

# UCSF

## UC San Francisco Previously Published Works

### Title

Disseminated Cutaneous and Osteoarticular Sporotrichosis Mimicking Pyoderma Gangrenosum

### Permalink

<https://escholarship.org/uc/item/0cq795h1>

### Journal

Open Forum Infectious Diseases, 6(10)

### ISSN

2328-8957

### Authors

Saeed, Lina

Weber, Robert J

Puryear, Sarah B

et al.

### Publication Date

2019-10-01

### DOI

10.1093/ofid/ofz395

Peer reviewed

# Disseminated Cutaneous and Osteoarticular Sporotrichosis Mimicking Pyoderma Gangrenosum

Lina Saeed,<sup>1,2\*</sup> Robert J. Weber,<sup>1\*</sup> Sarah B. Puryear,<sup>1,3</sup> Eman Bahrani,<sup>1,2</sup> Michael J. Peluso,<sup>1,3</sup> Jennifer M. Babik,<sup>1,3</sup> Anna Haemel,<sup>1,2</sup> and Sarah J. Coates<sup>1,2</sup>

<sup>1</sup>School of Medicine, University of California San Francisco, San Francisco, California, USA,

<sup>2</sup>Department of Dermatology, University of California San Francisco, San Francisco, California, USA, and <sup>3</sup>Division of Infectious Disease, University of California San Francisco, San Francisco, California, USA

Disseminated sporotrichosis may present with inflammatory arthritis and cutaneous ulcerations that mimic noninfectious skin conditions such as pyoderma gangrenosum (PG). Sporotrichosis must therefore be ruled out before administering immunosuppressive agents for PG. Furthermore, dimorphic fungi such as sporotrichosis may grow as yeast in bacterial cultures, even before fungal cultures become positive. We present a case of disseminated cutaneous and osteoarticular sporotrichosis mimicking PG and describe the differential diagnosis and the diagnostic and treatment approach to this condition.

**Keywords.** ulcer; deep fungal infection; septic arthritis; *Sporothrix*; disseminated fungal infection; United States of America.

## CASE REPORT

A 35-year-old woman with alcohol use disorder and type II diabetes presented with months of progressive, erythematous nodules and ulcerations. The initial lesion was an ulcerated nodule that appeared after falling on her right forearm. Similar lesions subsequently developed on her legs, contralateral arm, and abdomen (Figure 1). Concurrently, she developed asymmetric, large- and small-joint migratory arthritis and an unintentional 40-pound weight loss. She lived alone, previously worked as a landscaper, owned several indoor and outdoor cats, and denied recent sick contacts or travel outside California.

Skin biopsy demonstrated nodular vasculitis with negative organism stains, interpreted as erythema induratum. Blood

cultures, coccidioidomycoses serologies, HIV serologies, and QuantiFERON TB-gold were negative. Given numerous ulcers and negative organism stains, a presumptive diagnosis of pyoderma gangrenosum (PG) was made, and prednisone and doxycycline were initiated.

Despite immunosuppressive therapy, her lesions progressed, particularly the right forearm ulceration. Magnetic resonance imaging of this extremity revealed deep soft tissue inflammation, including olecranon bursitis, tenosynovitis, myositis, and trochlear avascular necrosis. For these findings, she underwent surgical debridement of a presumed soft tissue infection (Figure 2A) and was subsequently transferred to our hospital for further debridement.

Physical examination of the patient revealed numerous cribriform ulcerations with violaceous undermined borders (Figure 1) and right knee arthritis. No palpable lymphadenopathy was detected, and the remainder of her exam was normal. Computed tomography (CT) scan of the abdomen and pelvis revealed bilateral areas of hypolucency in each kidney, possibly compatible with pyelonephritis, though the patient lacked costovertebral angle tenderness and urine studies were negative. A chest CT detected no abnormalities. Brain imaging was not obtained; her neurologic exam was unremarkable. Right knee arthrocentesis showed 3000 white blood cells/mm<sup>3</sup> with a monocyte predominance and negative organism stains. Repeat skin biopsies demonstrated Periodic acid-Schiff-diastase (PAS-D)-positive yeast surrounding subcutaneous arterioles (Figure 2B). Three days later, synovial fluid bacterial cultures also yielded yeast.

## DIAGNOSIS: DISSEMINATED SPOROTRICHOSIS

Empiric liposomal amphotericin (4 mg/kg daily) was initiated. The next day, fungal cultures taken from the right forearm during surgical debridement, grown at 30°C on potato flake agar, yielded mold (Figure 3A), morphologically identified as *Sporothrix schenckii* (Figure 3B), confirming a diagnosis of sporotrichosis.

Corticosteroids were then tapered, and she completed 28 days of liposomal amphotericin, followed by oral itraconazole (induction at 200 mg 3 times daily for 3 days, followed by 200 mg twice daily), leading to resolution of most skin lesions. Joint involvement was managed conservatively without debridement or washout due to the high number of joints involved and evidence that medical management often suffices [1]. Recovery continued until 6 months later, when she was readmitted for worsening right arm and abdominal skin lesions, prompting concern for possible itraconazole resistance or failure (given itraconazole level was therapeutic).

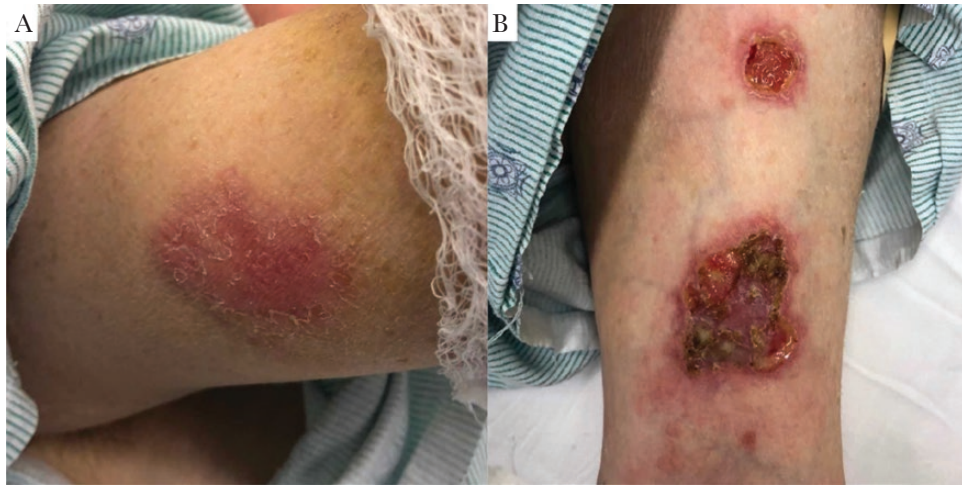Received 15 June 2019; editorial decision 3 September 2019; accepted 5 September 2019.

\*Lina Saeed and Robert J. Weber contributed equally to this work.

Correspondence: Sarah J. Coates, MD, Department of Dermatology, University of California San Francisco, 1701 Divisadero St., 3rd floor, San Francisco, CA 94115 (sarah.coates@ucsf.edu).

## Open Forum Infectious Diseases®

© The Author(s) 2019. Published by Oxford University Press on behalf of Infectious Diseases Society of America. This is an Open Access article distributed under the terms of the Creative Commons Attribution-NonCommercial-NoDerivs licence (<http://creativecommons.org/licenses/by-nc-nd/4.0/>), which permits non-commercial reproduction and distribution of the work, in any medium, provided the original work is not altered or transformed in any way, and that the work is properly cited. For commercial re-use, please contact journals.permissions@oup.com DOI: 10.1093/ofid/ofz395

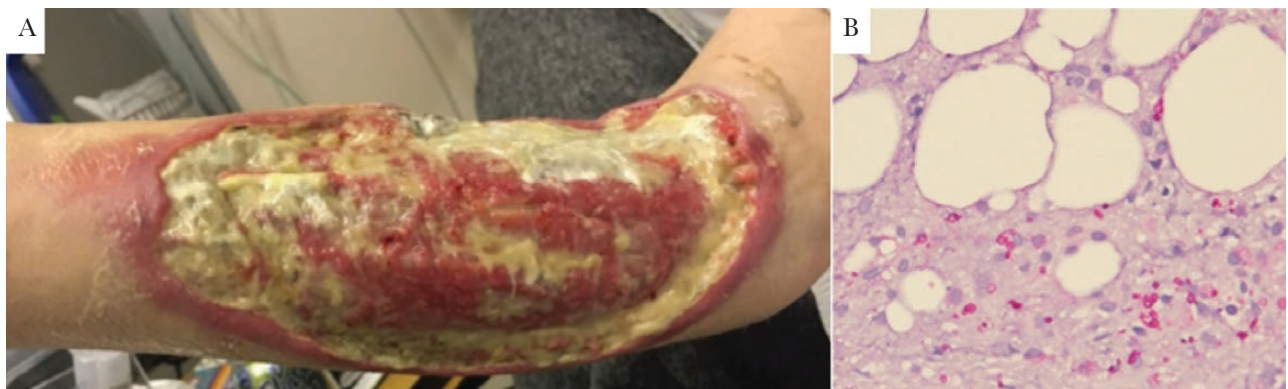

**Figure 1.** Skin lesions. A, Indurated, erythematous subcutaneous nodule with overlying scale on the right upper arm, representative of the early stages of evolution of these skin lesions. B, Left wrist exam, showing ulcerations with violaceous to erythematous undermined borders and a fibrinous base.

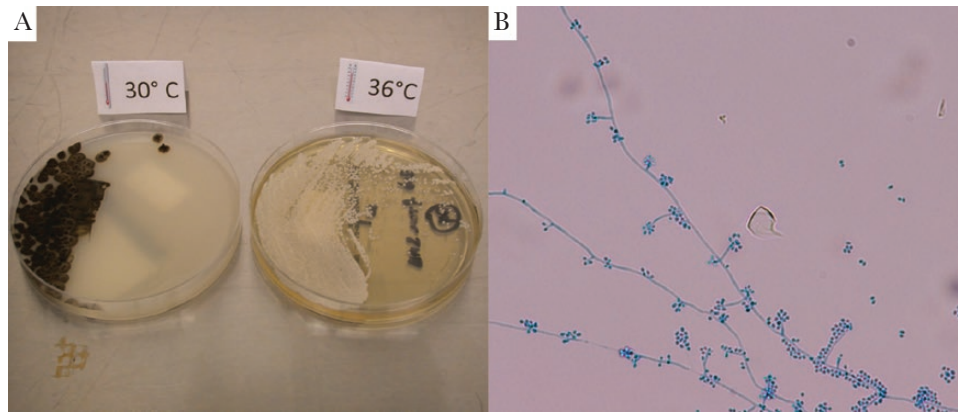
She was re-induced with amphotericin (4 mg/kg daily) for 3 weeks and then changed to oral posaconazole (300 mg once daily) based on initial sensitivity data (posaconazole minimum inhibitory concentration, 0.5). She remains on posaconazole 12 months after initial presentation, with no evidence of recurrence.

*Sporothrix* is a thermodimorphic fungus found in soil, animal excreta, and vegetation, mainly in subtropical and tropical regions [2]. It is spread primarily in its saprophytic, or hyphal, form through heavy soil exposure, especially via traumatic injuries sustained during outdoor work [2]. In South America, animals have been increasingly appreciated as vectors for *S. brasiliensis*, 1 species of the *Sporothrix* complex. In particular, domestic outdoor cats inoculate *Sporothrix* spp. via scratching [3] and many case reports highlight infection after handling wild armadillos [4].

*Sporotrichosis* classically presents in a lymphocutaneous pattern with distal to proximal spread from the inoculation site [2]. Typically, disseminated disease occurs in hosts with severe immunocompromise including those with HIV or hematologic malignancies. However, even immunocompetent hosts, especially those with heavy alcohol intake or poorly controlled diabetes, can develop both lymphocutaneous and disseminated disease (Table 1) [5]. Dissemination occurs in ~1% of cases [6], presenting with cutaneous features that include numerous nodules that often ulcerate [7]. Osteoarticular involvement is a common feature of disseminated disease, usually manifesting as large-joint monoarthritis [1]. Diagnosis is often delayed because symptoms mimic other conditions including PG, Sweet's syndrome, tuberculosis, sarcoidosis, and other mycotic or parasitic infections, including cutaneous leishmaniasis [8]. Indeed, *Sporothrix* is a common infectious mimicker of PG and can lead



**Figure 2.** A, Right upper extremity lesion after second debridement surgery. Significant full-thickness ulcer with erythematous, undermined borders covers most of forearm. Yellow material is a combination of fibrinous debris and gel wound dressing. B, Biopsy sample demonstrating PAS-D staining of yeast surrounding subcutaneous arterioles.



**Figure 3.** Culture findings. A, *Sporothrix schenckii* is a dimorphic fungus that grows as a mold at 30°C and as a yeast at 37°C. Culture specimens from surgical debridement are shown. B, Speciation of the mold was confirmed by microscopic examination, demonstrating hyphae and flower-like conidia.

to a delay in correct diagnosis, as several case reports have highlighted (Table 2) [9].

The histopathologic features of granulomatous inflammation with cigar-shaped organisms and asteroid bodies are supportive but have low sensitivity. Culture remains the gold standard but can take up to 7 days to result. *Sporothrix* grows as mold at lower temperatures (25°C–30°C) and yeast at body temperature. Notably, several dimorphic fungi may grow as yeast forms in aerobic bacterial culture systems at 35°C–37°C, including *Sporothrix*, *Blastomyces*, and *Histoplasma* [10, 11]. Given culture result latency, specific molecular diagnostics to rapidly confirm

*Sporothrix* infections have been studied [10]. In this case, however, broad-range fungal polymerase chain reaction (PCR) testing of skin samples and synovial fluid PCR were negative.

The recommended treatment for disseminated sporotrichosis, regardless of specific manifestation, is liposomal amphotericin 3–5 mg/kg daily until clinical improvement is seen, followed by step-down to oral itraconazole (200 mg twice daily) until resolution [12]. Posaconazole has occasionally been used as salvage therapy [13]. Prognoses are generally good, but up to a year of treatment may be required. Surgical joint debridement is rarely necessary and is ineffective as a monotherapy [12].

**Table 1. Case Reports of Disseminated Sporotrichosis in Immunocompetent Individuals**

Publication	Location	Age/Sex	Sites Involved	Risk Factor(s)	Treatment Regimen	Outcome
Campos-Macias et al. (2006) [13]	Japan	74/M	Skin (multiple sites) Lymph nodes Joints – arthritis, ankylosis, bursitis	None identified	Itraconazole 400 mg/d × 4 mo, then stopped prematurely Itraconazole 400 mg/d restarted, but taken incorrectly (200 mg/d)	Final outcome not provided
Yap (2011) [14]	Malaysia	70/F	Skin (multiple sites) Systemic – fevers, night sweats, wt loss	Gardening Pet cats	Amphotericin 0.7 mg/kg/d for 2 wk, followed by itraconazole 400 mg/d for 8 mo	Resolution
Ribeiro et al. (2015) [15]	Brazil	5/M	Skin (multiple sites) Joints – polyarthritis	None identified	Amphotericin (dose unknown) for 2 wk, followed by itraconazole (dose unknown) for 45 d	Resolution
Hassan et al. (2016) [6]	USA	56/M	Skin Joints – bilateral arthritis, bursitis Lungs – pleural effusions Eyes Systemic – fevers, wt loss	Farmer Alcohol use Type 2 DM	Liposomal amphotericin 3 mg/kg/d for 1 mo; discharged on itraconazole	Patient lost to follow-up
Hessler et al. (2017) [16]	California, USA		CNS – chronic meningitis Lungs Systemic – fevers No skin lesions or joint involvement	Construction worker	Itraconazole for 12 mo	Resolution

Abbreviations: CNS, central nervous system; DM, diabetes mellitus.

**Table 2. Case Reports of Disseminated Sporotrichosis Mimicking Pyoderma Gangrenosum, in Addition to Those Reported in Case Series From Byrd et al. (2001) [17] and Weenig et al. (2002) [9]**

Publication	Location	Age/ Sex	Host Features and Risk Factor(s)	Sites Involved	Treatments Received for Suspected PG	Time to Cor- rect Diagnosis	Treatment Regimen	Outcome
Charles et al. (2017) [18]	Michigan, USA	57/F	Immunocompetent History of obesity, asthma	Skin (multiple sites) Systemic – fevers, chills, fatigue	Methylprednisolone, prednisone, clobetasol	10 mo	Itraconazole 200 mg/d for 3 mo, then 200 mg twice daily due to poor response	Improved Final outcome not stated
Lima et al. (2017) [19]	Brazil	39/F	Immunocompetent Scratched by known sporotrichosis-infected (and untreated) cat	Skin (multiple sites) Lungs Systemic – sepsis	Systemic corticosteroids, infliximab (which triggered dissemination)	>24 mo	Liposomal amphotericin 400 mg/d for 6 wk, followed by itraconazole 400 mg/d for 12 mo	Resolution
Takazawa et al. (2018) [20]	Japan	47/M	History of ulcerative colitis on mesalamine	Skin (single site)	Topical steroid ointment	4 mo	Potassium iodide 500 mg for 2 wk, followed by 1000 mg and local heat therapy for 3 wk	Resolution

Abbreviations: PG, pyoderma gangrenosum; PMH,

## Acknowledgments

We would like to acknowledge our clinical lab assistant, Gail Cunningham, ASCP, for assistance in confirming the diagnosis and in providing microscopy and culture pictures. We would also like to thank Dr. Tim McCalmont in dermatopathology for his assistance with analyzing the histopathology in this case. Finally, we would like to thank Dr. Lindy Fox for her role in caring for this patient.

**Financial support.** This article has no funding sources. Dr. Weber (co-first author) is funded by the National Institute of General Medical Sciences (NIGMS) Medical Scientist Training Program (Grant #T32GM007618). Dr. Coates (corresponding and last author) is funded by the National Cancer Institute and the Fogarty International Center of the National Institutes of Health (NIH) under Award Number D43TW009343, as well as the University of California Global Health Institute (UCGHI).

**Disclaimer.** The content is solely the responsibility of the authors and does not necessarily represent the official views of the NIH or UCGHI.

**Potential conflicts of interest.** Authors L.S., R.W., S.P., E.B., M.P., J.B., A.H., and S.C. have no conflicts. All authors have submitted the ICMJE Form for Disclosure of Potential Conflicts of Interest. Conflicts that the editors consider relevant to the content of the manuscript have been disclosed.

## References

- Bayer A, Scott V, Guze L. Fungal arthritis. III. Sporotrichal arthritis. *Semin Arthritis Rheum* 1979; 9:66–74.
- Barros M, de Almeida Paes R, Schubach A. *Sporothrix schenckii* and sporotrichosis. *Clin Microbiol Rev* 2011; 24:633–54.
- Macedo-Sales P, Souto R, Destefani C, et al. Domestic feline contribution in the transmission of *Sporothrix* in Rio de Janeiro State, Brazil: a comparison between infected and non-infected populations. *BMC Vet Res* 2018; 14:19.
- Alves S, Boettcher C, Oliveira D, et al. *Sporothrix schenckii* associated with armadillo hunting in Southern Brazil: epidemiological and antifungal susceptibility profiles. *Rev Soc Bras Med Trop* 2010; 43:523–5.
- Bonifaz A, Tirado-Sanchez A, Paredes-Solis V, et al. Cutaneous disseminated sporotrichosis: clinical experience of 24 cases. *J Eur Acad Dermatol Venereol* 2018; 32:e77–9.
- Hassan K, Turker T, Zangeneh T. Disseminated sporotrichosis in an immunocompetent patient. *Case Reports Plast Surg Hand Surg* 2016; 3:44–7.
- He Y, Ma C, Fung M, Fitzmaurice S. Disseminated cutaneous sporotrichosis presenting as a necrotic facial mass: case and review. *Dermatol Online J* 2017; 23:13030/qt5zd47238.
- Grofino-Costa R, Boia M, Magalhaes G, et al. Arthritis as a hypersensitivity reaction in a case of sporotrichosis transmitted by a sick cat: clinical and serological follow up of 13 months. *Mycoses* 2010; 53:81–3.
- Weenig R, Davis M, Dahl P, Su W. Skin ulcers misdiagnosed as pyoderma gangrenosum. *N Engl J Med* 2002; 347:1412–8.
- Murray P, Masur H. Current approaches to the diagnosis of bacterial and fungal bloodstream infections in the intensive care unit. *Crit Care Med* 2012; 40:3277–82.
- Salimnia H, Brown P, Lephart P, Fairfax MR. Hyphal and yeast forms of *Histoplasma capsulatum* growing within 5 days in an automated bacterial blood culture system. *J Clin Microbiol* 2012; 50:2833–4.
- Kauffman C, Bustamante B, Chapman S, Pappas P; Infectious Diseases Society of America. Clinical practice guidelines for the management of sporotrichosis: 2007 update by the Infectious Diseases Society of America. *Clin Infect Dis* 2007; 45:1255–65.
- Bunce PE, Yang L, Chun S, Zhang SX, Trinkaus MA, Matukas LM. Disseminated sporotrichosis in a patient with hairy cell leukemia treated with amphotericin B and posaconazole. *Med Mycol* 2012; 50:197–201.
- Campos-Macías P, Arenas R, Vega-Memije M, Kawasaki M. *Sporothrix schenckii* type 3D (mtDNA-RFLP): report of an osteoarticular case. *J Dermatol* 2006; 33:295–9.
- Yap FB. Disseminated cutaneous sporotrichosis in an immunocompetent individual. *Int J Infect Dis* 2011; 15:e727–9.
- Ribeiro B, Ribeiro R, Penna C, Frota A. Bone involvement by *Sporothrix schenckii* in an immunocompetent child. *Pediatr Radiol* 2015; 45:1427–30.
- Hessler C, Kauffman CA, Chow FC. The upside of bias: a case of chronic meningitis due to *Sporothrix schenckii* in an immunocompetent host. *Neurohospitalist* 2017; 7:30–4.
- Byrd D, El-Azhary R, Gibson L, Roberts G. Sporotrichosis masquerading as pyoderma gangrenosum: case report and review of 19 cases of sporotrichosis. *J Eur Acad Dermatol Venereol* 2001; 15:581–4.
- Charles K, Lowe L, Shuman E, Cha KB. Painful linear ulcers: a case of cutaneous sporotrichosis mimicking pyoderma gangrenosum. *JAAD Case Rep* 2017; 3:519–21.
- Lima R, Jeunon-Sousa M, Jeunon T, et al. Sporotrichosis masquerading as pyoderma gangrenosum. *J Eur Acad Dermatol Venereol* 2017; 31:e539–41.
- Takazawa M, Harada K, Kakurai M, et al. Case of pyoderma gangrenosum-like sporotrichosis caused by *Sporothrix globosa* in a patient with ulcerative colitis. *J Dermatol* 2018; 45:e226–7.