

UCSF

UC San Francisco Previously Published Works

Title

Contralateral sialadenitis after resection of a right cerebellar metastasis: illustrative case

Permalink

<https://escholarship.org/uc/item/0c58s017>

Journal

Journal of Neurosurgery Case Lessons, 2(26)

ISSN

2694-1902

Authors

González, Hernán FJ
Morshed, Ramin A
Goldschmidt, Ezequiel

Publication Date

2021-12-01

DOI

10.3171/case21555

Peer reviewed

Contralateral sialadenitis after resection of a right cerebellar metastasis: illustrative case

Hernán F. J. González, PhD,¹ Ramin A. Morshed, MD,² and Ezequiel Goldschmidt, MD, PhD²

¹Medical Scientist Training Program, Vanderbilt University School of Medicine, Nashville, Tennessee; and ²Department of Neurological Surgery, University of California, San Francisco, San Francisco, California

BACKGROUND Acute postoperative sialadenitis is a rare and potentially morbid complication of cranial neurosurgery. This rapidly progressive, unilateral neck swelling often presents within hours of extubation. Diagnosis is made by imaging and exclusion of other causes of etiologies, such as neck hematoma, sialolithiasis, and dependent soft tissue edema.

OBSERVATIONS The authors presented a case of acute postoperative sialadenitis after suboccipital resection of a right cerebellar metastasis. Shortly after extubation, extensive left-sided neck swelling was apparent in the postanesthesia care unit. No central lines were placed during the procedure. Imaging revealed submandibular gland edema and fluid accumulation in the surrounding tissue. The patient was managed conservatively with steroids, antibiotics, and warm compresses, with complete resolution of symptoms 2 weeks after the procedure.

LESSONS This case emphasizes the broad differential of acute neck swelling after cranial surgery. Physical examination of the neck and airway protection should guide initial treatment. If a patient is stable, bedside ultrasound and computed tomography can be helpful with the differential diagnosis. Here the authors proposed an algorithm for diagnosis and treatment of acute neck swelling after cranial surgery.

<https://thejns.org/doi/abs/10.3171/CASE21555>

KEYWORDS sialadenitis; posterior fossa surgery; neck mass; cerebellar metastasis; parotitis; neurosurgery

Acute postoperative sialadenitis (also known as anesthesia mumps) is a rare complication of cranial neurosurgery.^{1,2} It has previously been noted as a complication of major abdominal surgery and may occur in as many as 0.1% of these cases.³ It was first reported in association with neurosurgical procedures by Berker et al. in 2004, and only a few reports on this topic have been published since.^{1,2,4-10} It typically presents in the immediate postoperative period as unilateral firm, nontender swelling in the submandibular region contralateral to the craniotomy site.⁹ The proposed etiology is the compression of the submandibular duct due to the rotation and flexion of the patient's head, leading to salivary stasis and, subsequently, sialadenitis. Here, we describe a case of acute postoperative sialadenitis in a patient after a right suboccipital craniotomy for tumor resection, review the literature on this rare clinical entity, and review an algorithm to diagnose and treat neck swelling after cranial surgery.

Illustrative Case

Preoperative Course and Imaging

A 75-year-old right-handed man with a history of esophageal cancer presented to his local emergency room with severe dysmetria, nausea, and vomiting, resulting in transfer to our facility. His physical examination at presentation to our facility showed 4/5 strength in bilateral upper and lower extremities and mild dysmetria in the bilateral upper extremities. These symptoms prompted neuroimaging, which revealed multiple contrast-enhancing lesions concerning for metastases (Fig. 1A and B). The largest of these lesions was found in the right cerebellum and was associated with fourth ventricular effacement and obstructive hydrocephalus. Therefore, a right suboccipital craniotomy for resection of the large cerebellar mass was recommended.

ABBREVIATIONS ETT = endotracheal tube; PACU = postanesthesia care unit.

INCLUDE WHEN CITING Published December 27, 2021; DOI: 10.3171/CASE21555.

SUBMITTED September 27, 2021. **ACCEPTED** November 8, 2021.

© 2021 The authors, CC BY-NC-ND 4.0 (<http://creativecommons.org/licenses/by-nc-nd/4.0/>).

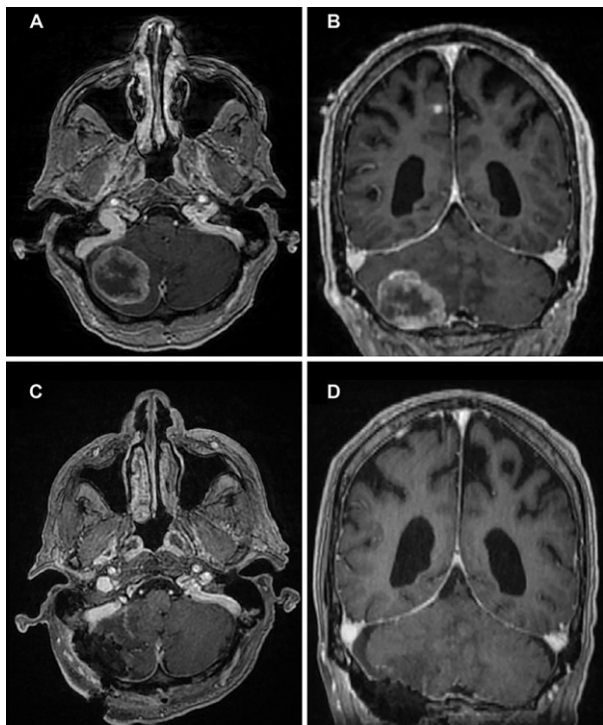


FIG. 1. Preoperative and postoperative magnetic resonance imaging (MRI). Axial (A) and coronal (B) preoperative T1-weighted contrast-enhanced MRI shows a dominant lesion in the right cerebellar hemisphere measuring approximately $3.1 \times 3.8 \times 3.1$ cm, with extensive edema in the right posterior cranial fossa and almost complete effacement of the fourth ventricle. Axial (C) and coronal (D) postoperative MRI shows excellent resection of the lesion.

Operation

The patient received a planned right frontal extraventricular drain placement and right suboccipital craniotomy for tumor resection. The patient was intubated with an endotracheal airway in a single attempt with a cuffed endotracheal tube (ETT) measuring 7.5 mm. The ETT was inserted to a depth of 23 cm as measured from the teeth with an initial cuff pressure of 24 cm H₂O. The intubation was performed via video laryngoscopy and cricoid pressure with a #4 blade. No complications or difficulties were encountered during intubation, and no central line was placed.

After placement of a right frontal external ventricular drain, the patient was then repositioned for the craniotomy in the lateral position with the right side up, and all pressure points were carefully padded (Fig. 2). The patient's head was placed in the Mayfield pin headrest. The head was turned 45° downward so the right suboccipital surface was horizontal to the floor. Additionally, this positioning allowed for seated use of the operative microscope. Care was taken during positioning to facilitate venous outflow. The patient received an uncomplicated right suboccipital craniotomy, and the right cerebellar metastasis was resected (Fig. 1C and D). The surgery lasted 5 hours from intubation to extubation and was uneventful. After an uncomplicated extubation, the patient was taken to the postanesthesia care unit (PACU), where his examination was the same as before surgery; his neck was supple and not noticeably swollen.

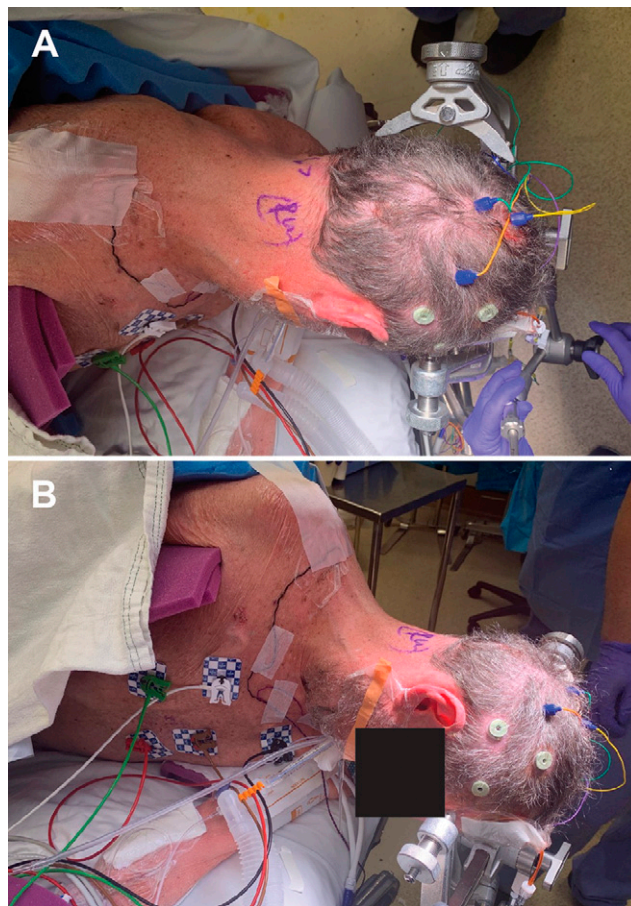


FIG. 2. The patient was in the lateral position with the right side up, and the patient's head was placed in Mayfield pins.

Postoperative Course

After approximately 5 minutes in the PACU, the patient was noted to have developed new acute left-sided lateral neck swelling that was not apparent immediately after extubation (Fig. 3). The patient's neck was mildly tender to palpation, but he endorsed no difficulty swallowing, no voice changes, no difficulty breathing, and no restricted neck range of motion. The differential for these findings in the neck included a soft tissue hematoma, sialolithiasis, acute sialadenitis, lymphatic or vascular obstruction, dependent edema, and angioedema.

A bedside ultrasound performed in the PACU was concerning for soft tissue swelling and an enlarged, cystic mass, which is not consistent with a hematoma. Computed tomography angiography (CTA) of the neck demonstrated extensive left submandibular gland edema with free fluid and soft tissue stranding in the submandibular space (Fig. 3C). There was no evidence of airway compression, compromise of major vessels, abscess, sialolith, or hematoma. The patient was transferred to the intensive care unit for close monitoring with a plan to reintubate if he showed signs of respiratory distress. He was started on antibiotics for 5 days to treat for gram-positive bacteria typically seen in the flora of the mouth and associated with sialadenitis.

On postoperative day 1, the patient was noted to have a 2-cm increase in neck circumference. He was asymptomatic with no

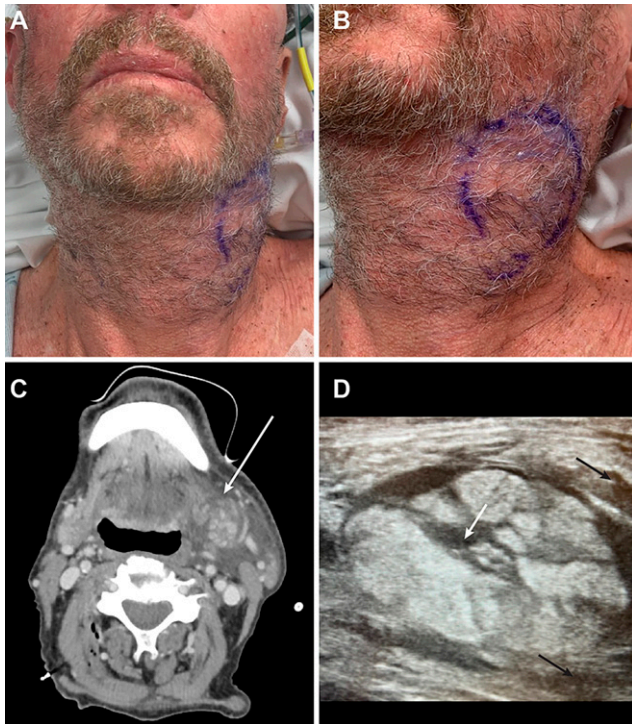


FIG. 3. A and B: Acute left submandibular swelling was noted shortly after suboccipital craniectomy for right cerebellar mass resection. **C:** Axial CT shows the left submandibular gland (*white arrow*) as significantly larger than the right submandibular gland. In the largest cross-sectional dimensions, the submandibular gland measured approximately 2.9×2.1 cm. **D:** Bedside submandibular ultrasound showed edema of subcutaneous fat (*black arrows*) and dilation of salivary ducts (*white arrow*). Additionally, no evidence of alternative cause for submandibular swelling was visualized.

dysphonia, shortness of breath, stridor, or difficulty swallowing. The otolaryngology service performed an additional assessment of the neck with bedside ultrasound, which showed worsened left submandibular gland swelling and edema of the subcutaneous fat without additional fluid collections or masses (Fig. 3D). The patient was started on high-dose steroids. Swelling eventually improved with continued conservative management. The patient was never in respiratory distress and did not require reintubation. He was discharged to home on postoperative day 7 with marked improvement in swelling.

Discussion

Observations

Acute postoperative sialadenitis is a rare complication of neurosurgical procedures and has seldom been reported in the literature (Table 1).²⁻²³ In one case series, Kim et al. described four patients who developed postoperative sialadenitis after retrosigmoid craniotomies in the supine position and one patient who developed sialadenitis after a far-lateral craniotomy in the park bench position.⁵ In another case study, a patient who received a left anterior temporal lobectomy was found to have contralateral sialadenitis resulting in hoarseness, right-sided tongue deviation, right-sided Horner's syndrome, and symptoms of right brachial plexus compression.⁹ Cavaliere et al.

reported a case of submandibular sialadenitis causing complete airway obstruction that required 7 days of intubation after a right parieto-occipital craniotomy.⁶ Quinn et al. presented a case of postoperative sialadenitis after a brainstem mass biopsy that required intubation for 5 days.¹ The exact reported incidence of this entity in neurosurgical procedures varies; however, frequency of acute bacterial parotitis in after abdominal surgery is better documented and may occur in up to 0.1% of cases.^{3,4} The case series by Kim et al. estimated that sialadenitis occurred in 0.84% of all retrosigmoid approaches at their institution.⁵ Another case series reported that postoperative sialadenitis occurred in 0.16% of their craniotomies and 1.9% of all sitting position neurosurgical procedures over a 5-year period.⁴ Other groups have cited an estimated incidence of sialadenitis as 1 in 1,000 to 3,000 after neurosurgical procedures.⁹

The mechanism of postoperative sialadenitis is likely multifactorial. However, in all reported cases, neck swelling was apparent contralateral to the craniotomy site, suggesting mechanical compression as the most likely etiology.¹¹ Across these previous works, postoperative neck swelling occurred most often from hours to 2 weeks after surgery.^{4,11} It is likely that the pathogenesis of postoperative neck swelling in these cases is heavily influenced by surgical position. Cases in which the head is placed in a turned and flexed position for surgery, such as retrosigmoid or suboccipital approaches, may be most likely to result in this postoperative complication. Positioning of the head in these cases may cause obstruction of salivary gland ducts, which is worsened by ETT and tongue compression. Once the duct is obstructed, it leads to salivary stasis and potential secondary bacterial infection with oral bacteria due to lack of salivary secretions, similar to sialolithiasis. In our case, we chose to place the patient lateral for access to the tumor. Alternatively, we could have placed the patient prone. This approach for positioning would have also prevented excess neck rotation. However, the prone position can result in increased venous pressure from increased pressure on the abdomen and increased positive end-expiratory pressure required to adequately ventilate these patients. In addition to positioning, other patient-specific and perioperative factors may influence likelihood of duct compression and postoperative submandibular swelling. Factors that may predispose to an increased risk of sialadenitis include extent of soft tissue compression, mouth dryness from perioperative dehydration, diabetes mellitus, hepatic failure, renal failure, hypothyroidism, Sjögren syndrome, and malnutrition.⁴

This case also brings to light the need for a differential diagnosis for acute postoperative neck swelling remote from a surgical site (Fig. 4). An expanding neck hematoma should always be considered first because it may lead to airway compromise. Continuous reevaluation of airway patency is the first step in management of these cases. There should be a low threshold to reintubate because airway compromise may make airway access impossible in minutes. After airway evaluation and vital signs assessment, images should be obtained. Point-of-care ultrasound can be useful for a rapid bedside evaluation. Ultrasound evaluation of acute sialadenitis typically reveals salivary duct dilatations, hypoechoic parenchyma, and enlarged intraglandular lymph nodes.^{12,13} Doppler may show hypervascularization resultant from inflammation.¹⁴ Although ultrasound is often sufficient to evaluate cases of sialadenitis, alternative causes of unilateral neck swelling may be better evaluated with CT angiography. On CT, postoperative sialadenitis typically presents with extensive soft tissue edema, evidenced by areas of hypoattenuation with some mild contrast enhancement and enlargement of the

TABLE 1. Review of the literature reporting cases of postoperative neck swelling in neurosurgical cases

Authors & Year	No. of Cases	Positioning	Presenting Symptoms	Management	Long-Term Sequelae	Preoperative Risk Factors	Reported Rate of Sialadenitis
Tattersall, 1984 ¹⁵	1	Suboccipital craniotomy, sitting	Tongue, lips, & bilateral face swelling, respiratory distress	Extubated after 17 days	Death	None reported	None reported
Narayan & Umamaheswara, 1999 ¹⁶	1	Right retrosigmoid craniectomy, lateral	Unilateral left face & neck swelling, inspiratory stridor	Tracheostomy (21 days), hydrocortisone, hyaluronidase injection	None	None reported	None reported
Berker et al., 2004 ⁴	5	4 posterior fossa craniotomies, & 1 parasagittal craniotomy, sitting	Unilateral swelling	Spiramycin 1 mg BID for 4 days	None	None reported	0.16% of all craniotomies & 1.9% of all sitting neurosurgical cases in 5-yr period
Izci et al., 2005 ¹⁷	1	Left pterional craniotomy, supine	Right submandibular swelling	Warm compresses	None	None reported	None reported
Kim et al., 2008 ⁵	5	Retrosigmoid, far-lateral craniotomies, supine & park bench	Unilateral neck swelling	4 patients extubated after 5–7 days, 1 patient given conservative management, all patients received 7–10 days of third-generation cephalosporin antibiotics	None	None reported	0.84% of all retrosigmoid/far-lateral approaches in a 4-yr period
Cavaliere et al., 2009 ⁶	1	Right parieto-occipital craniotomy, prone	Left neck swelling	Mannitol, dexamethasone, linezolid, meropenem, clindamycin, tracheostomy lasting 7 days	Dysphonia, right vocal cord palsy at discharge on postop day 28	None reported	None reported
Hébert-Blouin et al., 2009 ¹⁰	1	Right frontal craniotomy	Left brachial plexopathy	Steroids, sialagogues, broad-spectrum antibiotics	None	Prior episodes of periprocedural neck swelling	None reported
Shimizu et al., 2009 ¹⁸	1	Right suboccipital craniotomy, park bench	Left brachial plexopathy	Heparin	Brachial plexopathy, unilateral weakness, & sensory disturbances	None reported	None reported
Singha & Chatterjee, 2009 ⁷	1	Right retrosigmoid craniotomy, extreme lateral	Left neck swelling	Extubated after 14 days, antibiotics	None	None reported	None reported

CONTINUED ON PAGE 5 »

TABLE 1. Review of the literature reporting cases of postoperative neck swelling in neurosurgical cases

Authors & Year	No. of Cases	Positioning	Presenting Symptoms	Management	Long-Term Sequelae	Preoperative Risk Factors	Reported Rate of Sialadenitis
Prabhu et al., 2010 ¹⁹	1	Left vestibular schwannoma, semisitting	Unilateral neck swelling	Extubated after 7 days, broad-spectrum antibiotics	None	None reported	None reported
Rowell et al., 2010 ²	1	Left temporal craniotomy, semirecumbent	Left neck swelling	Cold compresses	None	None reported	None reported
Diehn & Morris, 2012 ²⁰	1	Right retrosigmoid craniotomy, supine with shoulder bump	Brachial plexopathy	Extubated after 2 days, sialagogues, warm compresses, antibiotics, steroids	Glossopharyngeal neuralgia at 3-mo follow-up	None reported	None reported
Özdek et al., 2014 ²¹	1	Right retrosigmoid craniotomy & auditory brainstem implantation, supine	Unilateral neck swelling	Ceftriaxone, dexamethasone	House-Brackman grade 4 facial paralysis that recovered over months	None reported	None reported
Uchino et al., 2015 ²²	2	Right retrosigmoid craniotomy, park bench, & right suboccipital craniotomy, lateral	Unilateral neck swelling	1 patient extubated after 3 days, 1 patient extubated after unreported length, antibiotics, corticosteroids	None	None reported	None reported
Vendantam et al., 2016 ⁹	1	Left anterior temporal lobectomy, supine with shoulder bump	Horner's syndrome & brachial plexopathy	Extubated after 9 days, corticosteroids, antibiotics, c1 esterase inhibitor protein	None	None reported	None reported
Clark et al., 2019 ²³	1	Right retrosigmoid craniotomy, supine	Unilateral neck swelling	Steroids, racemic epinephrine, tracheostomy	None	None reported	None reported
Naylor et al., 2021 ¹¹	1	Left retrosigmoid craniotomy, supine	Horner's syndrome	IV fluids, warm compress, sialagogues	None	None reported	None reported
This work	1	Right suboccipital craniotomy, lateral position	Unilateral neck swelling	Warm compresses, antibiotics, dexamethasone	None	None reported	None reported

IV = intravenous.

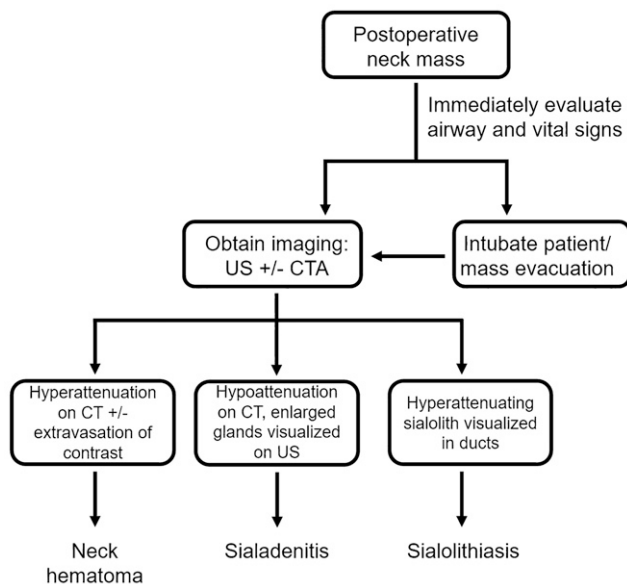


FIG. 4. Proposed algorithm for work-up and diagnosis of postoperative acute neck swelling. US = ultrasound.

submandibular glands.¹ The differential for acute neck swelling includes acute neck hematoma (resultant from line placement, surgical site in neck, pseudoaneurysm, or preexisting vascular wall weakness), angioedema (often medication related), and sialadenitis. This entire spectrum of possible diagnoses is well evaluated with CT and ultrasound. If diagnosis is still in doubt after imaging with both modalities, serial imaging can help monitor unilateral neck swelling.

In all reported cases of postoperative sialadenitis, management involved some combination of analgesics, corticosteroids, antibiotics, warm compresses, and/or airway protection by intubation.^{9,11} Empirical antibiotics can help prevent complications.^{4,11} Should swelling continue, high-dose corticosteroids can be used to reduce swelling and risk of airway compromise.

Although postoperative sialadenitis is manageable when quickly identified, prevention of this complication is preferred. Multiple strategies can be used to reduce the risk of postoperative sialadenitis: (1) working with the anesthesiologist to ensure that the ETT is not under tension, which may obstruct salivary gland outflow; (2) limiting the use of anticholinergic medications and other medications that decrease salivation (such as narcotics); (3) ensuring adequate hydration before, during, and after the operation; and (4) avoiding excessive rotation of the neck because postoperative sialadenitis can occur even when the neck is supple and adequate venous drainage is present.

Lessons

Positioning for posterior fossa surgery can include rotation and flexion of the neck.⁵ Some patients may develop acute postoperative sialadenitis, potentially because of their surgical positioning. Although acute sialadenitis is usually not apparent at the end of the operation, swelling often presents within hours of surgery.^{5,11} Important alternative diagnoses to consider include abscess, sialolith, and especially neck hematoma. Prevention strategies include perioperative

hydration and minimization of head and neck extreme positioning. Because sialadenitis is a rare complication in patients undergoing cranial neurosurgery, surgeons should make sure that positioning meets other surgical requirements, such as adequate lesion access, appropriate room for retraction and surgical working area, and minimization of other more common surgical complications. However, this case demonstrates that sialadenitis should be remembered during the management of acute postoperative neck swelling.

References

- Quinn ME, Quinn TD, Mian AZ, Sakai O. Imaging findings of “anesthesia mumps” (acute postoperative sialadenitis) after general anesthesia. *J Comput Assist Tomogr.* 2012;36(6):745–748.
- Rowell J, Lynn AM, Filardi TZ, Celix J, Ojemann JG. Acute unilateral enlargement of the parotid gland immediately post craniotomy in a pediatric patient: a case report. *Childs Nerv Syst.* 2010;26(9):1239–1242.
- McQuone SJ. Acute viral and bacterial infections of the salivary glands. *Otolaryngol Clin North Am.* 1999;32(5):793–811.
- Berker M, Sahin A, Aypar U, Ozgen T. Acute parotitis following sitting position neurosurgical procedures: review of five cases. *J Neurosurg Anesthesiol.* 2004;16(1):29–31.
- Kim LJ, Klopfenstein JD, Feiz-Erfan I, Zubay GP, Spetzler RF. Postoperative acute sialadenitis after skull base surgery. *Skull Base.* 2008;18(2):129–134.
- Cavaliere F, Conti G, Annetta MG, Greco A, Cina A, Proietti R. Massive facial edema and airway obstruction secondary to acute postoperative sialadenitis or “anesthesia mumps”: a case report. *J Med Case Reports.* 2009;3:7073.
- Singha SK, Chatterjee N. Postoperative sialadenitis following retromastoid suboccipital craniectomy for posterior fossa tumor. *J Anesth.* 2009;23(4):591–593.
- Phillips HW, Abdullah KG, Learned KO, Nayak N, McLaughlin E, Lee JY. Acute postoperative sialadenitis after retrosigmoid craniotomies. *J Neurosurg Sci.* 2016;60(3):403–404.
- Vedantam A, Hansen D, Daniels B, Lam S. Massive sialadenitis resulting in critical airway after elective craniotomy: case report. *J Neurosurg Pediatr.* 2016;18(4):475–479.
- Hébert-Blouin MN, Chowdhry SA, Abrahams PH, Spinner RJ. An unusual anatomical explanation for contralateral upper extremity weakness after frontal craniotomy. *Clin Anat.* 2009;22(7):840–845.
- Naylor RM, Graffeo CS, Ransom RC, et al. Acute sialadenitis after skull base surgery: systematic review and summative practice recommendations. *World Neurosurg.* 2021;150:205–210.e1.
- Bialek EJ, Jakubowski W, Zajkowski P, Szopinski KT, Osmolski A. US of the major salivary glands: anatomy and spatial relationships, pathologic conditions, and pitfalls. *Radiographics.* 2006;26(3):745–763.
- Katz P, Hartl DM, Guerre A. Clinical ultrasound of the salivary glands. *Otolaryngol Clin North Am.* 2009;42(6):973–1000.
- Kamble RC, Joshi AN, Mestry PJ. Ultrasound characterization of salivary lesions. *Int J Otorhinolaryngol Clin.* 2013;5(1):2013–2090.
- Tattersall MP. Massive swelling of the face and tongue: a complication of posterior cranial fossa surgery in the sitting position. *Anaesthesia.* 1984;39(10):1015–1017.
- Narayan VB, Umamaheswara GS. Unilateral facial and neck swelling after infratentorial surgery in the lateral position. *Anesth Analg.* 1999;89(5):1290–1291.
- Izci Y, Erdogan E, Timurkaynak E. Acute right submandibular swelling following surgery for bilateral optic nerve meningioma. *J Neurosurg Anesthesiol.* 2005;17(1):58–59.
- Shimizu S, Sato K, Mabuchi I, et al. Brachial plexopathy due to massive swelling of the neck associated with craniotomy in the park bench position. *Surg Neurol.* 2009;71(4):504–509.

19. Prabhu K, Nair S, Chacko AG. Acute submandibular sialadenitis as a cause of unilateral neck swelling after posterior fossa surgery in sitting position. *Neurol India*. 2010;58(6):963–964.
20. Diehn FE, Morris JM. Acute contralateral submandibular sialadenitis as a complication of skull base surgery. *Clin Neuroradiol*. 2012;22(2):161–163.
21. Özdek A, Bayör Ö, İşök ME, Tatar EÇ, Saylam G, Korkmaz H. Anesthesia mumps resulting in temporary facial nerve paralysis after the auditory brainstem implantation in a 3-year-old child. *Int J Pediatr Otorhinolaryngol*. 2014;78(1):159–162.
22. Uchino H, Motegi H, Kobayashi H, et al. Postoperative acute submandibular sialadenitis after neurosurgery: two case reports and a review of the literature. *NMC Case Rep J*. 2015;3:1–4.
23. Clark BM, Carlson ML, Van Gompel JJ, Warner MA. Severe acute postoperative airway compromise secondary to submandibular sialadenitis. *Can J Anaesth*. 2019;66(1):109–110.

Disclosures

The authors report no conflict of interest concerning the materials or methods used in this study or the findings specified in this paper.

Author Contributions

Conception and design: all authors. Acquisition of data: Morshed. Analysis and interpretation of data: González, Morshed. Drafting the article: all authors. Critically revising the article: all authors. Reviewed submitted version of manuscript: González, Morshed. Approved the final version of the manuscript on behalf of all authors: González. Administrative/technical/material support: Goldschmidt. Study supervision: Goldschmidt.

Correspondence

Ezequiel Goldschmidt: University of California San Francisco, San Francisco, CA. Eze.Goldschmidt@ucsf.edu.