

# UC Davis

## IDAV Publications

### Title

Severe Restriction in Jaw Movement Following Routine Injection of Local Anesthetic in Patients who have Fibrodysplasia Ossificans Progressiva

### Permalink

<https://escholarship.org/uc/item/0c5187fs>

### Journal

Oral Surgery, Oral Medicine, Oral Pathology, Oral Radiology, and Endodontics, 81

### Authors

Luchetti, Wayne  
Cohen, Randolph B.  
Hahn, Gregory V.  
et al.

### Publication Date

1996

Peer reviewed

---

## Severe restriction in jaw movement after routine injection of local anesthetic in patients who have fibrodysplasia ossificans progressiva

Wayne Luchetti, MD,<sup>a</sup> Randolph B. Cohen, MD,<sup>a</sup> Gregory V. Hahn, MD,<sup>a</sup> David M. Roche, PhD,<sup>b</sup> Mark Helpin, DMD,<sup>c</sup> Michael Zasloff, MD, PhD,<sup>d</sup> and Frederick S. Kaplan, MD,<sup>e</sup> Philadelphia, Pa., and Davis, Calif.

UNIVERSITY OF PENNSYLVANIA SCHOOLS OF MEDICINE AND DENTAL MEDICINE AND UNIVERSITY OF CALIFORNIA, DAVIS

**Objective.** To determine the relationship of dental procedures to immediate ossification and ankylosis of the jaw in patients who have fibrodysplasia ossificans progressiva.

**Study design.** A mail survey was conducted of the 60 patient-members of the International Fibrodysplasia Ossificans Progressiva Association. All 41 patients (18 males, 23 females) who responded were examined. Instantaneous exact hazard rates for ossification of the jaw were calculated by the Weibull model.

**Results.** Thirty-six patients had dental procedures performed. Twenty-one (58%) patients had received an injection of local anesthetic. Five (24%) patients had an immediate flare-up of fibrodysplasia ossificans progressiva with ossification and permanent ankylosis of the jaw (expected occurrence, 0.031;  $p < 0.0001$ ). None of the 12 patients who had comparable dental work without injections developed heterotopic ossification (expected occurrence, 0.019; not significant).

**Conclusion.** Injections of local anesthetic during dental procedures pose serious and immediate risk for inciting heterotopic ossification and ankylosis of the jaw in patients who have fibrodysplasia ossificans progressiva and should be assiduously avoided.

(ORAL SURG ORAL MED ORAL PATHOL ORAL RADIOLOG ENDOD 1996;81:21-5)

Fibrodysplasia ossificans progressiva (FOP) is an extremely rare<sup>1</sup> and disabling<sup>2</sup> heritable disorder<sup>3</sup> of connective tissue characterized by progressive post-natal heterotopic ossification of soft tissue<sup>4</sup> and by congenital malformation of the great toes.<sup>5</sup> There are presently fewer than 80 known living patients in the United States with the condition.<sup>3</sup> Autosomal dominant inheritance has been demonstrated,<sup>3</sup> but most

cases arise by spontaneous mutation.<sup>6</sup> The genetic defect and the pathogenesis of bone formation in FOP is unknown. The bone morphogenetic proteins have been postulated as candidate genes on the basis of their ability to induce heterotopic ossification and their ability to regulate vertebrate pattern formation.<sup>7</sup>

The first manifestation of impending ossification at an anatomic site is the occurrence of warm, painful, nodules in the soft connective tissues.<sup>8</sup> These nodules resemble aggressive fibromatosis<sup>3</sup> but develop through an endochondral process to form mature heterotopic bone that is morphologically indistinguishable from mature normotopic bone.<sup>3</sup> This heterotopic bone bridges and rigidly immobilizes the joints of the axial and appendicular skeleton, making movement impossible.<sup>8</sup> Heterotopic bone formation in FOP progresses in specific anatomic and temporal patterns beginning in cranial, proximal, axial, and dorsal regions and later involving more caudal, distal, appendicular, and ventral regions.<sup>2</sup>

Disease exacerbation can be stimulated by blunt trauma or may occur spontaneously.<sup>2</sup> Surgical removal of heterotopic bone is futile, as tissue trauma associated with surgery inevitably leads to the stimulation of even more robust ossification at the surgical site.<sup>1,8</sup> Furthermore, medical therapy has been

Supported in part by research fellowship grants from The American Heart Association-Merck Fellowship, and The International Fibrodysplasia Ossificans Progressiva Association.

<sup>a</sup>Assistant Instructor, Department of Orthopaedic Surgery, Division of Molecular Orthopaedics, University of Pennsylvania School of Medicine.

<sup>b</sup>Professor, Graduate School of Management, University of California, Davis.

<sup>c</sup>Assistant Professor, Department of Pediatric Dentistry, University of Pennsylvania School of Dental Medicine.

<sup>d</sup>Professor, Department of Orthopaedic Surgery, Division of Molecular Orthopaedics, University of Pennsylvania School of Medicine.

<sup>e</sup>Associate Professor, Department of Orthopaedic Surgery, Division of Molecular Orthopaedics, University of Pennsylvania School of Medicine.

Received for publication Feb. 20, 1995; returned for revision Apr. 13, 1995; accepted for publication July 25, 1995.

Copyright © 1996 by Mosby-Year Book, Inc.

1079-2104/96/\$5.00 + 0 7/12/68128

Table 1. Clinical data on 21 patients with FOP who received injections during dental procedures

Patient	Age (years)	Sex	Age at beginning of jaw restriction (years)	Age-related instantaneous risk of heterotopic ossification <sup>8</sup>	Injections	Braces	Fillings/ extractions	FOP flare
1	22	F	9	0.0005	Yes	No	Yes	Yes
2	35	M	18	0.0013	Yes	No	Yes	No
3	36	F	24	0.0019	Yes	Yes	Yes	No
4	33	F	13	0.0008	Yes	Yes	Yes	No
5	44	F	10	0.0006	Yes	No	Yes	Yes
6	56	F	24	0.0019	Yes	No	Yes	No
7	46	F	23	0.0018	Yes	No	Yes	No
	35	F	24	0.0019	Yes	No	Yes	
	15	M	No restriction	0.0000	Yes	Yes	Yes	No
	41	M	12	0.0008	Yes	No	Yes	No
	45	M	32	0.0028	Yes	No	Yes	No
	54	F	31	0.0026	Yes	No	Yes	No
	41	M	15	0.0010	Yes	No	Yes	No
14	33	M	33	0.0029	Yes	No	Yes	No
15	32	F	26	0.0021	Yes	No	Yes	No
16	22	F	19	0.0014	Yes	Yes	Yes	No
17	25	M	25	0.0019	Yes	No	Yes	No
18	36	F	20	0.0015	Yes	No	Yes	Yes
19	14	F	7	0.0004	Yes	No	Yes	Yes
20	42	F	26	0.0021	Yes	No	Yes	Yes
21	40	F	15	0.0010	Yes	No	Yes	No

empiric because of the lack of knowledge of the pathogenesis of FOP. At this time there is no effective treatment for the condition.

The temporomandibular joint (TMJ) is characteristically one of the last joints to be affected with heterotopic ossification<sup>2</sup> as the risk of jaw involvement is very low for young children but increases with age.<sup>9</sup> In a recent large review of patients, osseous bridging across the TMJ occurred in 71% of FOP patients by a mean age of 18 years (standard deviation, 7 years; range, 5 to 26 years) and led to permanent ankylosis of the jaw.<sup>2</sup> Patients have reported anecdotally that various forms of dental treatment may have precipitated heterotopic bone formation around the jaw regardless of age. However, conclusions have been based on small samples of patients without detailed dental histories. The present study uses data from a large sample of patients with FOP with detailed dental histories, assesses the risk of various aspects of dental therapy, and generates guidelines for the dental care of these patients.

#### METHODS

A detailed dental health survey was mailed to the 60 patient-members of The International Fibrodysplasia Ossificans Progressiva Association. The survey was designed to ascertain each patient's age, gender, age of onset of heterotopic ossification in the jaw, as well as a history of dental care including fill-

ings, extractions, or braces. The study was designed to note the use of any injected local anesthetic as well as the temporal relationship of injections to FOP flares in the TMJ. In addition, all patients who reported having injections of local anesthetic were contacted by telephone to obtain a more detailed dental history and an account of any heterotopic ossification of the TMJ. All 60 patients had been seen and examined by one of the two senior investigators (M.A.Z. or F.S.K.) between 1977 and 1993 and a diagnosis of FOP had been confirmed in all cases. At the time the survey was conducted, the 60 patient-members of the International FOP Association represented more than 90% of all known patients in the United States who had FOP.

A Weibull model was used to calculate instantaneous exact hazard rates for ossification of the jaw (a joint with nonconstant hazard) based on the data of Rocke et al.<sup>9</sup>

#### RESULTS

The mail survey was returned by 41 patients (68% response). There were 18 males and 23 females. The age of the respondents ranged from 3 to 69 (mean age, 28) years. Twelve (67%) of the 18 males and 18 (78%) of the 23 females reported jaw restriction. The mean age of onset of ossification in the jaw was 17 years.

Thirty-six (88%) of the 41 patients reported having

Table II. Clinical data on 12 patients with FOP who did not receive injections during dental procedures.

Patient	Age (years)	Sex	Age at beginning of jaw restriction (years)	Age-related risk of instantaneous heterotopic ossification <sup>8</sup>	Injections	Braces	Fillings/ extractions	FOP flare
1	9	M	—	0.0006	No	No	Yes	No
2	34	M	25	0.0030	No	No	Yes	No
3	7	M	—	0.0004	No	No	Yes	No
4	22	M	—	0.0018	No	No	Yes	No
5	20	M	—	0.0016	No	No	Yes	No
6	20	M	—	0.0016	No	No	Yes	No
7	12	M	9	0.0008	No	No	Yes	No
8	24	M	18	0.0020	No	No	Yes	No
9	11	F	7	0.0006	No	No	Yes	No
10	20	F	—	0.0016	No	Yes	Yes	No
11	21	F	—	0.0016	No	No	Yes	No
12	69	F	26	0.0030	No	No	Yes	No

had a dental procedure (fillings or extractions) performed. Twenty-one (54%) of the 36 patients who had dental work performed had received an injection of a local anesthetic during the procedure (Table I), whereas 12 of the 26 patients who had comparable dental procedures did not receive an injection of a local anesthetic (Table II). Detailed telephone follow-up of the 21 patients who received injections revealed that five (24%) patients reported an immediate FOP flare (defined as marked swelling and stiffening leading to permanent loss of jaw motion) within several days of an injection (expected occurrences, 0.031;  $p < 0.0001$ ). The null hypothesis that the observed ossification events had no relationship to the injection that preceded it was thus rejected at a  $p$  value of  $<0.0001$ . None of the 12 patients who had fillings or extractions performed without injections had developed heterotopic ossification as a result of the procedure (expected occurrences, 0.019; not significant). One patient (patient 12, Table I) reported marked stiffening of her jaw after an injection, but the stiffening resolved in 1 week. Three (14%) of the 21 reported that some form of local trauma to the neck or jaw (a fall, a clothesline injury, and a bicycle accident) led directly to an FOP flare in the TMJ. In addition, another patient (patient 17, Table I) reported having surgery to remove the heterotopic bone in the jaw, but the surgery led to a marked worsening of the condition and resulted in further heterotopic ossification with resultant ankylosis of the jaw. The flare-up and subsequent ankylosis in this case was attributed to the overwhelming trauma of surgery rather than to any injection.

Six (29%) of the 21 patients contacted by phone reported having orthodontic appliances during child-

hood. All six had fixed appliances in place from 6 months to 1½ years in duration. This was followed in three patients with the use of removable appliances. All six patients denied having any FOP flares as a result of the application or removal of fixed appliances or the routine use of removable appliances. One of the patients reported having had tooth extractions to facilitate eating after rigid ankylosis of the jaw. The procedure was performed with the patient under a general anesthetic, and no disease flare-up was reported.

#### DISCUSSION

The results of this survey establish that injections of local anesthetic during dental procedures pose substantial added risk for inciting heterotopic ossification and subsequent ankylosis of the TMJ in patients who have FOP. There was no significant added risk of immediate heterotopic ossification of the jaw after dental procedures in which there was no injection of local anesthetic. Several biases may have been introduced during this study. First, we relied on the records and memories of patients and their families rather than on clinician-generated dental records, and therefore certain recall biases or errors may have been introduced. Although many patients had meticulously recorded in diaries the details of their dental history and medical care, we were unable to determine whether the injections occurred in the maxilla or in the mandible or whether they were infiltrations or nerve blocks. This was the major flaw in the study. Second, approximately one third of the surveyed patients did not return the questionnaire, and we were thus unable to obtain useful information with respect to dental procedures from that group. However, care-

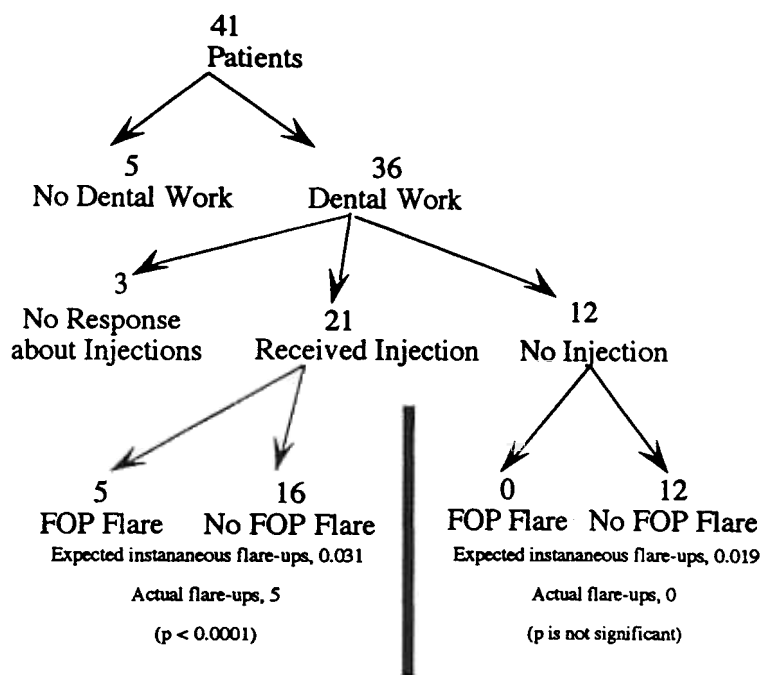


Fig. 1. Schematic diagram illustrates composition of study group according to occurrence of dental procedure, administration of injection, and occurrence of FOP flare.

ful review of old records in our possession on all of these patients failed to reveal any substantial differences between them and those who completed the survey.

Renton et al.<sup>10</sup> described the unusual roentgenographic appearance of the TMJs in two patients who had FOP and suggested that this unusual appearance was a characteristic feature of the underlying skeletal dysplasia in patients who had the disorder. Jonathan and Jefferis<sup>11</sup> presented an isolated case report of an 18-year-old girl who had an acute submandibular swelling as the presenting sign of FOP. Although several of our patients had experienced spontaneous submandibular swelling and subsequent ossification, none specifically reported it after a dental procedure or after an injection of a local anesthetic.

Several reports have noted that dental therapy may accelerate the natural course of heterotopic ossification in the jaw,<sup>2, 12</sup> as occurred in our patient 17 (Table I). In their 1982 study, Connor et al.<sup>1</sup> suggested, "Dental therapy should be cautious" in these patients, but no specific recommendations were made. Our study shows that as many as 24% of the patients with FOP who had received an injection of a local anesthetic as part of a dental procedure developed heterotopic ossification around the jaw within a week of the injection. In those patients who reported no jaw restriction, 55% underwent extractions or fillings without injections. At present, it is not possible to de-

termine if the trauma of injection, the local anesthetic agent itself, or a combination of both incited the local ossification process. However, considering the sensitivity of FOP to trauma, it is likely that the trauma of the injections rather than the specific agent injected led to stimulation of heterotopic ossification in the jaws of patients who have FOP.

In general, subcutaneous and intravenous injections are not problematic in patients who have FOP, whereas deep intramuscular injections of any type are more likely to cause a flare-up.<sup>1</sup> Therefore we strongly recommend the avoidance of any intramuscular or buccal injections during dental work in patients who have FOP. We also recommend that assiduous attention be directed to the prevention of dental caries, as prevention would decrease the need for invasive dental procedures. Preventative measures should include early, regular, and periodic dental visits, oral hygiene instruction, nutritional counseling, fluoride supplementation,<sup>13</sup> home fluorides,<sup>14</sup> and dental sealants.<sup>15</sup>

Only one patient in our survey (patient 17, Table I) had surgery to remove the heterotopic bone in his jaw, and the surgery led rapidly to a worsening of his condition. This is consistent with several previous reports.<sup>8, 12</sup> Rogers and Geho<sup>8</sup> reported 55 operations or biopsies in 37 patients with FOP and found that 34 patients experienced an exacerbation of the condition after a surgical procedure. In another study, Crofford

et al.<sup>12</sup> combined surgery with isotretinoin treatment (a drug with known inhibitory effects on differentiation of mesenchymal tissue) in an attempt to remove osseous bridges across the TMJ of two patients. Both patients, however, had clinical and roentgenographic evidence of recurrence of heterotopic ossification across the joint within 2 months after surgery. Thus, we strongly recommend avoidance of any surgical procedures to remove heterotopic bone in the jaw in patients who have FOP.<sup>1,4</sup>

Six of the 21 patients from whom we obtained detailed dental histories had used orthodontic appliances, and none of the six patients reported FOP flare-ups as a result of that therapy. We suggest that orthodontic care need not be avoided in these patients, but we do suggest avoidance of stretching of the jaw during the application or removal of braces or during any other dental procedure.

Our study shows that in patients with FOP, routine injections of local anesthetic for dental procedures may exacerbate the formation of heterotopic bone about the jaw and lead to permanent loss of TMJ movement. When dental procedures are necessary, the injection of a local anesthetic should be avoided whenever possible. If unavoidable, injections should be as atraumatic as possible, should be limited to subcutaneous infiltration, and should assiduously avoid intramuscular penetration. Vigilant attention should be directed to the prevention of dental carries in order to decrease the need for invasive dental procedures.

#### REFERENCES

1. Connor JM, Evans DAP. Fibrodysplasia ossificans progressiva. The clinical features and natural history in 34 patients. *J Bone Joint Surg* 1982;64B:76-83.
2. Cohen RB, Hahn GV, Tabas JA, et al. The natural history of

- heterotopic ossification in patients who have fibrodysplasia ossificans progressiva: a study of forty-four patients. *J Bone Joint Surg* 1993;75A:215-9.
3. Kaplan FS, McCluskey W, Hahn GV, Tabas JA, Muenke M, Zasloff MA. Genetic transmission of fibrodysplasia ossificans progressiva. *J Bone Joint Surg* 1993;75A:1214-20.
4. Beighton P. Fibrodysplasia ossificans progressiva. In: McKusick VA, ed. Heritable disorders of connective tissue. St. Louis: CV Mosby, 1993:501-18.
5. Schroeder H, Zasloff M. The hand and foot malformations in fibrodysplasia ossificans progressiva. *Johns Hopkins Med J* 1980;147:73-8.
6. Connor J, Evans D. Genetic aspects of fibrodysplasia ossificans progressiva. *J Med Genet* 1982;19:35-9.
7. Kaplan FS, Tabas JA, Zasloff MA. Fibrodysplasia ossificans progressiva: a clue from the fly. *Calc Tissue Int* 1990;47:117-25.
8. Rogers JG, Geho WB. Fibrodysplasia ossificans progressiva: a survey of 42 cases. *J Bone Joint Surg* 1979;61A:909-14.
9. Rocke D, Zasloff M, Peeper J, Cohen R, Kaplan F. Age- and joint-specific risk of initial heterotopic ossification in patients who have fibrodysplasia ossificans progressiva. *Clin Ortho Rel Res* 1994;301:243-8.
10. Renton P, Parkin S, Stamp T. Abnormal temporomandibular joints in fibrodysplasia ossificans progressiva. *Br J Oral Maxillofac Surg* 1982;20:31-8.
11. Jonathan D, Jefferis A. Fibrodysplasia ossificans progressiva presenting acutely as a submandibular swelling. *J Laryngol Otol* 1985;99:721-4.
12. Crofford LJ, Louie R, Zasloff MA, Marini JC. Failure of surgery and isotretinoin to relieve jaw immobilization in fibrodysplasia ossificans progressiva: report of two cases. *J Oral Maxillofac Surg* 1990;48:204-8.
13. Green JC, Louie R, Wycoff SJ. Preventive dentistry. *JAMA* 1989;262:3459-63.
14. Carlos JP. Fluoride mouthrinses. In: Shy W, ed. Clinical uses of fluorides. Philadelphia: Lea and Febiger, 1985:75-82.
15. Ripa LW. The current status of pit and fissure sealants: a review. *Can Dent Assoc J* 1985;5:367-80.

#### Reprint requests:

Frederick S. Kaplan, MD  
Chief of Metabolic Bone Diseases and Molecular Orthopaedics  
Hospital of the University of Pennsylvania  
Department of Orthopaedic Surgery  
Silverstein Two  
3400 Spruce Street  
Philadelphia, PA 19104