

UC Irvine

UC Irvine Previously Published Works

Title

Long-term consequences following conservative management of epithelial ovarian cancer in an infertile patient.

Permalink

<https://escholarship.org/uc/item/09s0w008>

Journal

Gynecologic oncology, 73(3)

ISSN

0090-8258

Authors

Moore, MM
Tewari, K
Rose, GS
[et al.](#)

Publication Date

1999-06-01

DOI

10.1006/gyno.1999.5357

Copyright Information

This work is made available under the terms of a Creative Commons Attribution License, available at <https://creativecommons.org/licenses/by/4.0/>

Peer reviewed

CASE REPORT

Long-Term Consequences Following Conservative Management of Epithelial Ovarian Cancer in an Infertile Patient

Meagan M. Moore, M.D.,* Krishnansu Tewari, M.D.,* G. Scott Rose, M.D.,*
John P. Fruehauf, M.D., Ph.D.,†‡ and Philip J. DiSaia, M.D.*

*Division of Gynecologic Oncology and †Department of Hematology & Oncology, University of California, Irvine—Medical Center, 101 The City Drive, Orange, California 92868; and ‡Oncotech, Inc., 1791 Kaiser Avenue, Irvine, California 92614

Received September 14, 1998

A 35-year-old woman with primary infertility underwent an ovarian cystectomy for a 5 × 4 cm left adnexal mass. There was no macroscopic evidence of metastatic disease. The final pathology report revealed a poorly differentiated serous cystadenocarcinoma. Because the patient desired to retain child-bearing capacity, she refused a surgical staging of her ovarian cancer. She elected to receive combination chemotherapy. This was then followed by a negative reassessment laparotomy. The patient was diagnosed with recurrent, metastatic ovarian carcinoma 10 years later.

© 1999 Academic Press

Key Words: ovarian cancer; recurrence; infertility.

INTRODUCTION

Epithelial ovarian carcinoma is the most lethal gynecologic malignancy of American women. The management of this disease typically includes surgical debulking followed by combination chemotherapy. In a woman who desires future fertility, a well-differentiated, nonserous, FIGO Stage IA ovarian cancer may be treated by conservative surgery (i.e., a unilateral salpingo-oophorectomy with preservation of the uterus and contralateral ovary) [1].

We present the case of an infertile woman with an invasive ovarian carcinoma who strongly desired future fertility. She demanded conservative surgical management despite pathologic and clinical factors which precluded a consideration for such treatment.

CASE HISTORY

In 1987, a 35-year-old, Caucasian, nulligravida, with a history of primary infertility, presented with abdominal pain to her local community hospital. Pelvic ultrasonography revealed a complex left adnexal mass. At laparotomy, a 5 × 4 cm left ovarian cyst was discovered and a cystectomy was performed. There was no gross evidence of pelvic or intra-abdominal

disease. An intraoperative frozen-section analysis had not been requested, and the final pathology report revealed an undifferentiated carcinoma. The patient was referred to the Division of Gynecologic Oncology at the University of California, Irvine.

The histologic material was sent to the clinical pathology consultative practice of Robert E. Scully of Harvard Medical School and the presence of a poorly differentiated serous cystadenocarcinoma of the ovary was confirmed. The cancer antigen 125 was <35 U/dl in serum. The patient was counseled to undergo a complete staging procedure for her ovarian cancer, but was adamant in her refusal, secondary to a desire to retain child-bearing capacity and to avoid further surgery. Thus, the patient remained surgically unstaged and elected to receive adjuvant systemic treatment. Seven cycles of Adriamycin and cisplatin were administered; cyclophosphamide was not included secondary to the risk of toxicity to the gonadal tissue.

In 1988, the patient agreed to undergo reassessment laparotomy, without oophorectomy. There was no gross evidence of residual disease. An infracolic omentectomy and bilateral pelvic lymphadenectomy as well as peritoneal biopsies and washings were negative for malignancy. The following year, at the age of 37, the patient was diagnosed with premature ovarian failure, presumably resulting from the previous chemotherapy. Despite ovarian failure, she continued to refuse completion surgery for her ovarian cancer and never received ovulation-induction agents or other fertility drugs.

During nearly a decade of follow-up, the patient remained without evidence of recurrence. Then, in 1997, she underwent surgical evaluation for pelvic pain and was found to have a 5 × 4 cm solid and cystic mass, involving the left ovarian remnant. A mandatory intraoperative frozen-section analysis revealed carcinoma. The right ovary appeared normal and there was no evidence of gross metastatic disease. She underwent a total abdominal hysterectomy, bilateral salpingo-oophorectomy,

TABLE 1
Chromosomal and Tumor Marker Analyses

Chromosomal analysis	Index case (1987)	Present case (1997)
DNA ploidy	Aneuploid	Diploid
Immunohistochemical analyses	Index case (1987)	Present case (1997)
Her-2/neu gene product	Not detected	Not detected
Estrogen receptor protein	Present	Present
p53 gene product	Present	Present
Cancer antigen 125	Present	Present
Epidermal growth factor receptor protein	Not detected	Present

completion omentectomy, and multiple peritoneal biopsies and washings.

The final pathology report revealed a poorly differentiated papillary serous cystadenocarcinoma of the left ovary. Microscopic metastases were present in the right fallopian tube and omentum and in an adhesion released from the sigmoid colon. The cancer antigen 125 in serum was within normal limits. Following her postoperative recovery, the patient began adjuvant therapy with paclitaxel and carboplatin.

DNA studies demonstrated that the original tumor was aneuploid and that the new lesion was diploid. Immunohistochemical analyses revealed that the estrogen receptor protein, the p53 tumor suppressor gene product, and CA-125 were present in both tumors. Neither tumor stained positive for the Her-2/neu proto-oncogene product. The epidermal growth factor receptor protein was only detected in the new tumor. These data are summarized in Table 1.

DISCUSSION

I. The Concept of Disease Recurrence

In theory, following primary cytoreductive surgery and adjuvant chemotherapy, a few cancer cells may survive and continue to escape complete annihilation by immunosurveillance mechanisms. Eventually, tumor cells multiply, neovascularization ensues, and malignant nodules develop and coalesce, resulting in clinically obvious recurrent disease. Although we may imagine that this could occur at any point during a patient's follow-up, we believe that this is much more likely to occur within the first 5 years, and rarely after 10 years. Cells which have been genetically primed through germline mutations, as well as those which have accumulated genetic damage secondary to environmental carcinogens, may undergo growth deregulation and declare their malignant potential at varying times in a woman's life.

The clinical problem is confounded in cases of early stage cancers treated conservatively with preservation of ovarian

tissue at the time of initial staging. Does disease relapse represent a true recurrence or a new primary lesion? Our patient had been treated conservatively and harbored residual ovarian tissue on the side of the original lesion. In addition to the histologic consistency between the two specimens, conservation of the estrogen receptor protein, the p53 gene product, and CA-125 indicates that the metachronous malignancies were similar and strongly suggests that cells shed from the original tumor were responsible for the recurrence.

Disparities between the metachronous lesions with respect to DNA ploidy and the epidermal growth factor receptor could be attributed to heterogeneity in the original tumor, cell line selection of an altered phenotype secondary to chemotherapy, and/or clonal divergence of the original tumor over time. Such clonal divergence in DNA ploidy was supported by our analysis of 66 matched cases of primary and recurrent ovarian cancers separated temporally by less than 5 years. Fifty-nine percent of the tumors retained their aneuploid status at recurrence, while 15% converted from aneuploidy to a diploid state at relapse (Fig. 1). This aneuploid-to-diploid transition is a phenomenon which was also exhibited by the metachronous lesions in our patient.

II. Conservative Management in the Infertile Patient

Young women with well-differentiated, nonserous, early stage ovarian cancer may be candidates for well-defined conservative surgery. Patients should undergo an adequate surgical staging procedure to be correctly placed into the FIGO Stage IA classification. A unilateral salpingo-oophorectomy, omental and peritoneal biopsies, careful lymph node sampling, and retrieval of washings for cytologic examination should be performed. Approximately 30% of patients whose disease appears grossly confined to one ovary will be upstaged on the basis of histologic examination [2]. Conversely, in patients diagnosed with a well-differentiated invasive cancer by cystectomy or unilateral salpingo-oophorectomy alone, a repeat laparotomy allows those patients determined to have surgical FIGO Stage IA disease to avoid adjuvant therapy [3].

Historically, it has been argued that once childbearing is completed or deemed impossible, some consideration should be given to the removal of the other ovary to lower the risk of

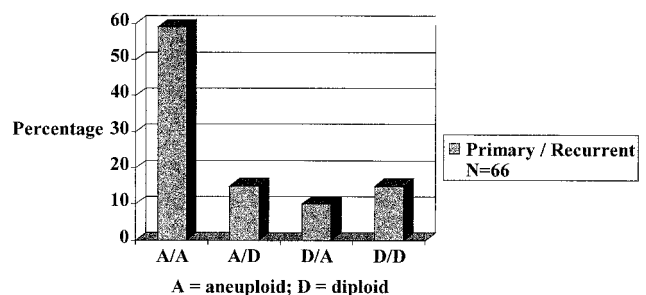


FIG. 1. DNA ploidy in primary and recurrent ovarian carcinoma.

recurrence or development of a second primary lesion. Colombo *et al.* reported three relapses occurring within 5 years of conservative surgery in 36 patients with Stage IA disease [4]. One of the recurrences occurred in the contralateral ovary and the patient was rescued by surgery; the other 2 patients experienced distal recurrences and died of disease. Clearly, extremely close follow-up of all patients treated by conservative surgery is warranted, with a complete workup of all specific and nonspecific symptoms.

Because our patient was surgically unstaged and had been diagnosed with a *serous* cystadenocarcinoma in 1987, she did not meet the criteria for conservative surgery. However, the patient demanded this approach because she desired the potential for child-bearing, although she had never achieved a pregnancy in the past. The subject of infertility merits a philosophical expansion on the appropriateness of conservative surgery. Perhaps a distinction should be made between the *young* woman who has not had the opportunity to start a family and the *infertile* patient who has tried unsuccessfully to become pregnant. The decision to permit conservative surgery may be appropriate for the young patient, but it may be prudent to exercise some caution when considering conservative management of early ovarian cancer in the infertile patient. The theoretical risk of incessant ovulation uninterrupted by pregnancy, or hyperstimulated ovulation, may place a woman with a history of early stage disease at increased risk for recurrent ovarian cancer.

Whittemore and colleagues reported the results of an analysis of several case-control studies which demonstrated an association between infertility and epithelial ovarian cancer as well as a possible causal link between the use of ovulation-stimulating agents and epithelial ovarian cancer in infertility patients [5]. Additionally, Rossing reported a higher risk of malignant and borderline epithelial ovarian tumors in a cohort of women undergoing ovulation induction with clomiphene citrate [6]. With respect to recurrent disease, Bandera reported a 31-year-old with a history of a Stage IC epithelial ovarian carcinoma who developed a recurrence shortly after receiving gonadotropin therapy for ovulation induction [7].

Although there exists much debate concerning the need for adjuvant therapy in early stage epithelial ovarian cancer, the risks of premature ovarian failure should be discussed with ovulatory patients scheduled to receive systemic chemotherapy. This risk appears to be dependent on maternal age, the specific antineoplastic agent used (e.g., cyclophosphamide), and the total cumulative dose administered. With advancing age, the reservoir of oocytes diminishes and increases the

likelihood of ovarian failure. In one prospective study of ovarian function in premenopausal women receiving chemotherapy for breast cancer, the risk of chemotherapy-induced amenorrhea was highest in women over the age of 40 [8]. Oocyte harvesting with *in vitro* fertilization and embryo cryopreservation may be an option for infertile patients who require systemic treatment and for those who may be destined to undergo resection of the remaining adnexa without hysterectomy.

In summary, infertile patients with early stage disease and appropriate histology who opt for conservative management should be counseled regarding the available data linking infertility and possibly, ovulation induction, to ovarian cancer. Furthermore, they should not delay in their attempts to achieve pregnancy. It may be advisable to establish a limit to the amount of time during which pregnancy may be attempted. Once the predetermined period has elapsed, whether patients have been successful or not, a strong consideration should be given to performing completion surgery for ovarian cancer. Under such circumstances, patients may then need to identify a surrogate mother for *in vitro* fertilization and embryo transfer (if the patient has retrievable oocytes) or pursue child adoption.

REFERENCES

1. DiSaia PJ, Townsend DE, Morrow CP: The rationale for less than radical treatment for gynecologic malignancy in early reproductive years. *Obstet Gynecol Surv* 29:589-593, 1994
2. Young RC, Decker DG, Wharton JT, Piver MS, Sindelar WF, Edwards BK, Smith JP: Staging laparotomy in early ovarian cancer. *JAMA* 250:3072-3076, 1983
3. Stier EA, Barakat RR, Curtin JP, Brown CL, Jones WB, Hoskins WJ: Laparotomy to complete staging of presumed early ovarian cancer. *Obstet Gynecol* 87:737-740, 1996
4. Colombo N, Chiari S, Maggioni A, Bocciolone L, Torri V, Mangioni C: Controversial issues in the management of early epithelial ovarian cancer: conservative surgery and role of adjuvant therapy. *Gynecol Oncol* 55:S47-S51, 1994
5. Whittemore AS, Harris R, Itnyre J, and the Collaborative Ovarian Cancer Group: Characteristics relating to ovarian cancer risk: collaborative analysis of 12 case-control studies II, invasive epithelial ovarian cancers in white women. *Am J Epidemiol* 136:1184-1203, 1992
6. Rossing MA, Daling JR, Weiss NS, Moore DE, Self SG: Ovarian tumors in a cohort of infertile women. *N Engl J Med* 331:771-776, 1994
7. Bandera CA, Cramer DW, Friedman AJ, Sheets EE: Fertility therapy in the setting of a history of invasive epithelial ovarian cancer—case report. *Gynecol Oncol* 58:116-119, 1995
8. Fisher B, Sherman B, Rockette H, Redmond C, Margolese K, Fisher ER: L-phenylalanine mustard (L-PAM) in the management of premenopausal patients with primary breast cancer. *Cancer* 44:847-857, 1979