

UC Irvine

Western Journal of Emergency Medicine: Integrating Emergency Care with Population Health

Title

Iliac Pseudoaneurysm from Endoleak

Permalink

<https://escholarship.org/uc/item/09d96763>

Journal

Western Journal of Emergency Medicine: Integrating Emergency Care with Population Health, 16(7)

ISSN

1936-900X

Authors

Moffett, Peter
Redmon, Travis
Vitto, Michael J.
[et al.](#)

Publication Date

2015

DOI

10.5811/westjem.2015.8.28284

Copyright Information

Copyright 2015 by the author(s). This work is made available under the terms of a Creative Commons Attribution License, available at <https://creativecommons.org/licenses/by/4.0/>

Peer reviewed

Iliac Pseudoaneurysm from Endoleak

Peter Moffett, MD
Travis Redmon, MD
Michael J. Vitto, DO, MS
David Evans, MD

Virginia Commonwealth University Health System, Department of Emergency Medicine, Richmond, Virginia

Section Editor: Sean O. Henderson, MD

Submission history: Submitted July 24, 2015; Accepted August 12, 2015

Electronically published December 1, 2015

Full text available through open access at http://escholarship.org/uc/uciem_westjem

DOI: 10.5811/westjem.2015.8.28284

[West J Emerg Med. 2015;16(7):1194-1195.]

A 65-year-old male presented to the emergency department complaining of two hours of severe lower abdominal pain radiating into his left testicle. The patient described a vascular procedure in the past but did not recall the details. An emergent bedside ultrasound was performed to evaluate the abdominal aorta. During the exam an echogenic object consistent with a prior endovascular stent was discovered in the distal aorta prompting further ultrasound evaluation of the iliac artery (Figure). A true lumen (thin black arrow) was visualized with evidence of leak (white arrows) during color Doppler evaluation. The patient was taken emergently to computed tomography and the diagnosis of an iliac artery pseudoaneurysm from an endoleak was confirmed.

A pseudoaneurysm is formed after a disruption causes a sacular expansion at the site of injury that is contained by adventitia or perivascular soft tissue. Rupture is common in

patients with iliac artery pseudoaneurysm, with associated mortality rates of approximately 50%.¹ An endoleak is a potential complication of endovascular stenting that involves blood leaking around or through the graft site.²

Presenting symptoms of a pseudoaneurysm are variable, based on the location, and are often caused by pressure on adjacent organs. Symptoms that have been described include abdominal pain, urinary symptoms, renal failure, lumbosacral pain, groin pain, rectal bleeding, or constipation.¹

Our patient had prior endovascular stenting of an iliac artery aneurysm that extended into the distal aorta. He had developed a pseudoaneurysm (thick black arrow) arising from the medial aspect of the left iliac artery at the juncture of two metallic stents with active extravasation suggestive of an endoleak (white arrows). The patient underwent endovascular repair with endograft placement to repair the leak and

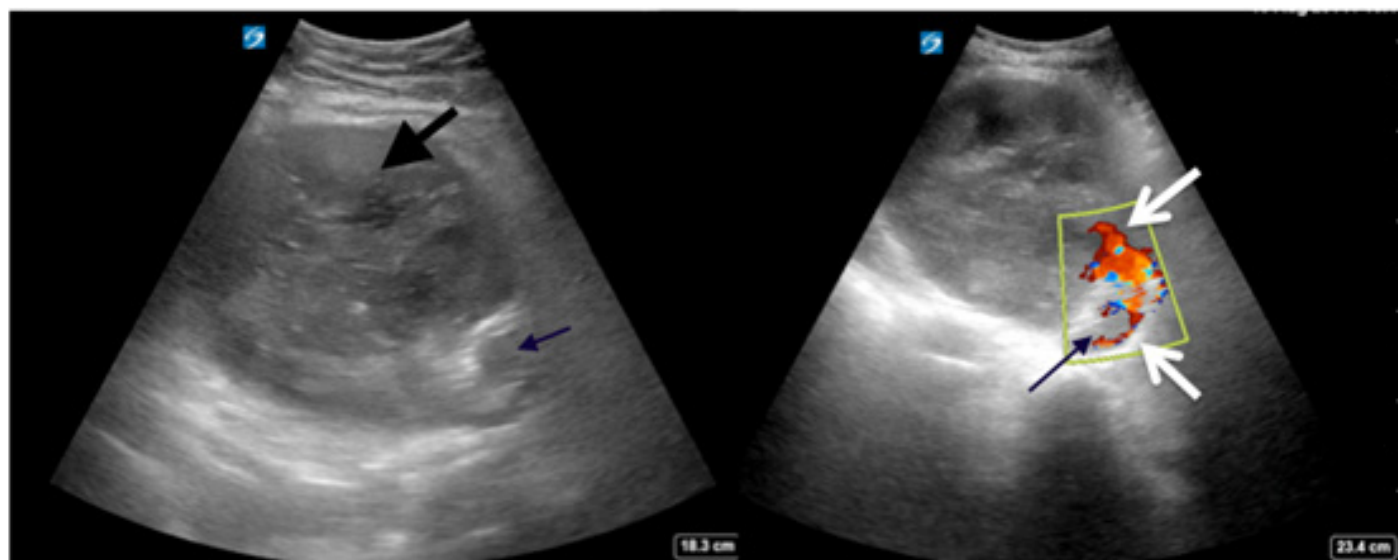


Figure. Ultrasound of the left iliac (left) with color Doppler flow (right) showing the true lumen (thin black arrow) and evidence of the leak (white arrows) creating a pseudoaneurysm (thick black arrow).

subsequent coil embolization of the pseudoaneurysm cavity.

Address for Correspondence: Peter Moffett, MD, Virginia Commonwealth University Health System, Department of Emergency Medicine, 1250 E Marshall Street, Main Hospital, P.O. Box 980401, Richmond, VA 23298. Email: pmoff2@gmail.com.

Conflicts of Interest: By the WestJEM article submission agreement, all authors are required to disclose all affiliations, funding sources and financial or management relationships that could be perceived as potential sources of bias. The authors disclosed none.

Copyright: © 2015 Moffett et al. This is an open access article distributed in accordance with the terms of the Creative Commons Attribution (CC BY 4.0) License. See: <http://creativecommons.org/licenses/by/4.0/>

REFERENCES

1. Dix FP, Titi M, Al-Khaffaf H. The isolated internal iliac artery aneurysm--a review. *Eur J Vasc Endovasc Surg.* 2005;30(2):119-129.
2. Rosen RJ and Green RM. Endoleak management following endovascular aneurysm repair. *J Vasc Interv Neurol.* 2008;19(6):S37-43.