

UC Davis

Dermatology Online Journal

Title

Edematous lip in a HIV patient on highly active antiretroviral therapy

Permalink

<https://escholarship.org/uc/item/0994886k>

Journal

Dermatology Online Journal, 20(4)

Authors

Thorpe, Ryan
Lopez, Isha
Tran, Kien

Publication Date

2014

DOI

10.5070/D3204022370

Copyright Information

Copyright 2014 by the author(s). This work is made available under the terms of a Creative Commons Attribution-NonCommercial-NoDerivatives License, available at <https://creativecommons.org/licenses/by-nc-nd/4.0/>

Peer reviewed

PhotoVignette

Edematous lip in a HIV patient on highly active antiretroviral therapy

Ryan Thorpe BS, Isha Lopez MD, Kien Tran MD PhD

Dermatology Online Journal 20 (4): 13

University of Texas Southwestern Medical Center

Correspondence:

Dr. Kien Tran
Clinical Assistant Professor
VA Medical Center
4500 Lancaster Rd
Medical Services-111 Department of Dermatology
Dallas, TX 75216
Kientran1975@gmail.com

Abstract

A 59-year-old HIV-positive, hepatitis C positive man on highly active antiretroviral therapy presented with a 2-year history of extreme swelling of the lower lip. Granulomatous cheilitis was diagnosed.

Key Words: granulomatous cheilitis, HAART, HIV, Melkersson-Rosenthal syndrome

Introduction

Granulomatous cheilitis (GC) is characterized by persistent swelling of one or both lips. The condition was first described by Miescher in 1945 and has been labeled by some as “Miescher Cheilitis.” [1, 2, 3] Although the exact etiology is unknown, allergy, genetic susceptibility, immune-mediated diseases like Crohn disease and sarcoidosis, and infectious etiologies, such as primary syphilis, tuberculosis, and leprosy have all been associated. [1, 2] In particular, TB and odontogenic infections have resulted in GC. Once the infection is resolved, the GC usually improves.

Case synopsis

We report the case of a 59-year-old HIV positive, Hepatitis C positive man who presented with persistent, painless swelling of the lower lip for 2 years. The swelling had impacted his ability to eat and speak. He had been compliant with his highly active antiretroviral therapy (HAART) medications for the past 8 years. Eighteen months before presenting he was misdiagnosed with angioedema of the lower lip and subsequently failed to respond to antihistamines and corticosteroids. He had no history of any AIDS defining illnesses. He also denied any history of Crohn disease, ulcerative colitis, or other skin disease.

Physical examination revealed a severely enlarged lower lip with uniform induration and superficial purple-brown macules on the mucosal surface (Figure 1). There was no lymphadenopathy and the tongue was not fissured. Lacrimal glands were not enlarged and no neuropathy was identified. A PPD and RPR were negative and his CD4+ count was 718 with an HIV RNA viral load < 20 copies/mL. A punch biopsy was performed (Figure 2 and Figure 3).

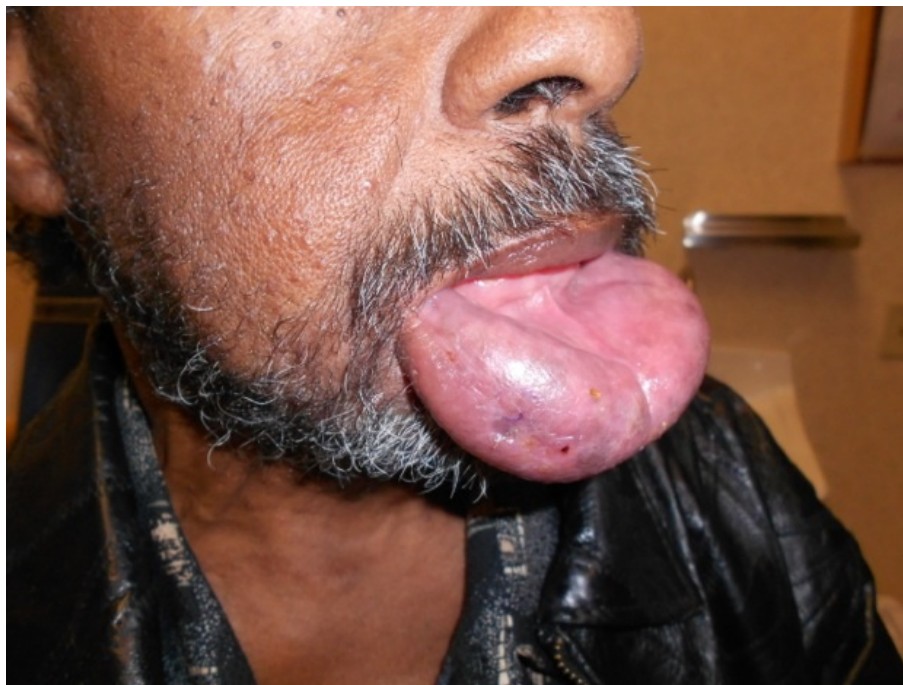

Figure 1. Granulomatous cheilitis in the lower lip

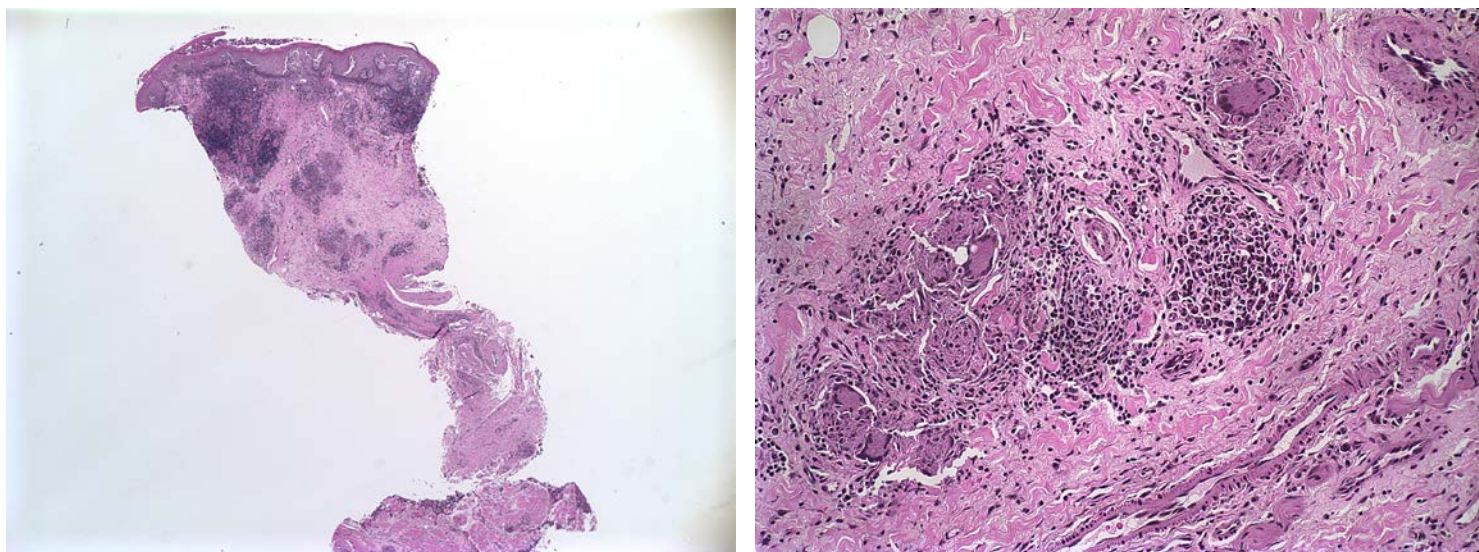


Figure 2. Low-power view revealing multiple non-necrotizing granulomas in the dermis surrounded by chronic inflammatory infiltrates 40x

Figure 3. High-power view revealing multiple non-necrotizing granulomas surrounded by chronic inflammatory infiltrates 200x

Light microscopy analysis revealed multiple non-necrotizing granulomas in the dermis surrounded by chronic inflammatory infiltrates (see Figure 2 and 3). The granulomas were smaller than those seen in classical sarcoidosis and the inflammation was more pronounced than in classical sarcoidosis. Stains for acid-fast bacilli and fungi were negative and there were no birefringent foreign bodies under polarized light.

Discussion

Granulomatous cheilitis is chronic swelling of the lip owing to accumulating granulomatous inflammation, but the etiology remains unknown [1, 2, 3]. Granulomatous cheilitis is rarely described with fissured tongue and facial palsy in which case it is termed Melkersson-Rosenthal Syndrome. Lip swelling can be the sole manifestation of Melkersson-Rosenthal Syndrome in about 25% of the cases [2]. Patients within this spectrum are frequently misdiagnosed as having angioedema and the diagnosis of GC becomes more apparent following failed therapy for angioedema [4].

Interestingly, on review of the literature, this is the second reported case of GC in an HIV positive patient on HAART [5]. The patient in the previously described case report had a possible nidus for GC in an odontogenic infection, but the GC did not improve once the infection resolved. The authors of that report hypothesized that HAART may have reconstituted the patient's immune system leading to a granulomatous response to the odontogenic infection.

The diagnosis of GC usually requires clinicohistopathologic correlation. Non-caseating granulomas are the hallmark. Treatment of GC has been difficult, unpredictable, and non-uniform. Many strategies have been reported in the literature with varied success, including antibiotics, antihistamines, corticosteroids, anti-TNF inhibitors, and surgery [1, 6, 7]. Combination therapies have been reported with some success, including betamethasone injections with concurrent doxycycline [8] and intralesional injection of Pingyangmycin plus corticosteroids [9]. In this case, a test-dose of intralesional kenalog (ILK) injection was performed with some improvement in the swelling. After he had no clinical signs of infection, he was started on 10 mg/cc of ILK injections and is awaiting the commencement of dapsone therapy.

In our patient, no clear etiology or nidus of infection could be found. Although at present the relationship between HAART, HIV, and GC cannot be proven to be causal, there is a possibility that this is the second case to support such an association. Nevertheless, many GC cases are idiopathic with no clear etiology. Further observation and reporting are required to characterize any relationship between GC and HAART or immune reconstitution in HIV patients.

References

1. Banks T, Gada S. A comprehensive review of current treatments for granulomatous cheilitis. *Br J of Dermatol*. 2012 May;166(5):934-7. [PMID: 22187977]
2. Martinez-Martinez ML, Amana-Dofez, JM, Perez-Garcia LJ, Lopez-Villaescusa MT, Vasquez MR, Faura-Berruga C. Granulomatous cheilitis: a report of 6 cases and a review of the literature. *Actas Dermosifiliogr*. 2012 Oct;103(8):718-24. [PMID: 22657098]
3. Vibhute NA, Vibhute AH, Daule NR. Cheilitis granulomatosa: a case report with review of literature. *Indian J Dermatol*. 2013 May;58(3):242. [PMID: 23723497]
4. Lopez-Urbano MJ, Villar MA, Ruiz Villaverde R, Avila IR. Granulomatous cheilitis: a condition that merits inclusion in the differential diagnosis of angioedema. *J Investig Allergol Clin Immunol*. 2009;19(1):68-70. [PMID: 19274936]
5. Dalessandro M, Vecchiet J, Angelucci D, Pizzigallo E, Tulli A, Amerio P. Granulomatous cheilitis in an HIV positive patient on HAART therapy. *Eur J Dermatol*. 2008 Sep-Oct;18(5):591. [PMID: 18779107]
6. Kruse-Losler B, Presser D, Metze D, Joos U. Surgical treatment of persistent macrocheilia in patients with Melkersson-Rosenthal syndrome and cheilitis granulomatosa. *Arch Dermatol*. 2005 Sep;141(9):1085-91. [PMID: 16172304]
7. Nocini PF, Procacci P, Albanese M, Trevisiol L, D'agostino A, Girolomoni G, Palma P, Chiarini L, Bertossi D. Tongue flap to treat a severe case of Miescher's cheilitis granulomatosa. *Minerva Stomatol*. 2013 Aug 1. [PMID: 23903449]
8. Oudrhiri L, Chiheb S, Marnissi F, Zamiati S, Benchikhi H. Successful treatment of Miescher's cheilitis in Melkersson-Rosenthal syndrome with betamethasone injections and doxycycline. *Pan Afr Med J*. 2012;13:75. Epub 2012 Dec 9. [PMID: 23397029]
9. Gu L, Huang DY, Fu CJ, Wang ZL, Liu Y, Zhu GX. Intralesional injection of Pingyangmycin plus corticosteroids may be an effective treatment for cheilitis granulomatosa. *Med Hypotheses*. 2013 Aug 14. [PMID: 23953485]