

UCSF

UC San Francisco Previously Published Works

Title

Supramaximal Resection Can Prolong the Survival of Patients with Cortical Glioblastoma: A Volumetric Study.

Permalink

<https://escholarship.org/uc/item/0990g5fm>

Journal

Neurologia Medico-Chirurgica, 63(8)

Authors

Otsuji, Ryosuke

Hata, Nobuhiro

Funakoshi, Yusuke

et al.

Publication Date

2023-08-15

DOI

10.2176/jns-nmc.2022-0351

Copyright Information

This work is made available under the terms of a Creative Commons Attribution-NonCommercial-NoDerivatives License, available at

<https://creativecommons.org/licenses/by-nc-nd/4.0/>

Peer reviewed

Supramaximal Resection Can Prolong the Survival of Patients with Cortical Glioblastoma: A Volumetric Study

Ryosuke OTSUJI,¹ Nobuhiro HATA,^{1,2} Yusuke FUNAKOSHI,¹ Daisuke KUGA,¹ Osamu TOGAO,³ Ryusuke HATAE,¹ Yuhei SANGATSUDA,¹ Yutaka FUJIOKA,¹ Kosuke TAKIGAWA,¹ Aki SAKO,¹ Kazufumi KIKUCHI,³ Tadamasa YOSHITAKE,³ Hidetaka YAMAMOTO,⁴ Masahiro MIZOGUCHI,¹ and Koji YOSHIMOTO¹

¹Department of Neurosurgery, Graduate School of Medical Sciences, Kyushu University, Fukuoka, Fukuoka, Japan

²Department of Neurosurgery, Oita University Faculty of Medicine, Yufu, Oita, Japan

³Department of Clinical Radiology, Graduate School of Medical Sciences, Kyushu University, Fukuoka, Fukuoka, Japan

⁴Department of Pathology, Graduate School of Medical Sciences, Kyushu University, Fukuoka, Fukuoka, Japan

Abstract

We aimed to retrospectively determine the resection rate of fluid-attenuated inversion recovery (FLAIR) lesions to evaluate the clinical effects of supramaximal resection (SMR) on the survival of patients with glioblastoma (GBM). Thirty-three adults with newly diagnosed GBM who underwent gross total tumor resection were enrolled. The tumors were classified into cortical and deep-seated groups according to their contact with the cortical gray matter. Pre- and postoperative FLAIR and gadolinium-enhanced T1-weighted imaging tumor volumes were measured using a three-dimensional imaging volume analyzer, and the resection rate was calculated. To evaluate the association between SMR rate and outcome, we subdivided patients whose tumors were totally resected into the SMR and non-SMR groups by moving the threshold value of SMR in 10% increments from 0% and compared their overall survival (OS) change. An improvement in OS was observed when the threshold value of SMR was 30% or more. In the cortical group (n = 23), SMR (n = 8) tended to prolong OS compared with gross total resection (GTR) (n = 15), with the median OS of 69.6 and 22.1 months, respectively (p = 0.0945). Contrastingly, in the deep-seated group (n = 10), SMR (n = 4) significantly shortened OS compared with GTR (n = 6), with median OS of 10.2 and 27.9 months, respectively (p = 0.0221). SMR could help prolong OS in patients with cortical GBM when 30% or more volume reduction is achieved in FLAIR lesions, although the impact of SMR for deep-seated GBM must be validated in larger cohorts.

Keywords: supramaximal resection, glioblastoma, depth, volumetric study, survival

Introduction

The association between the resection rate of contrast-enhanced (CE) tumors and the outcome has been widely investigated in patients with glioblastoma (GBM). Gross total resection (GTR), in which the CE lesion is completely resected, is known to be effective in prolonging overall survival (OS).^{1,2)} However, since GBM is a highly invasive tumor, tumor cells often spread far from the CE region and can extend to the contralateral hemisphere at the time of

diagnosis.³⁻⁷⁾ Considering such infiltrative behavior, resection beyond the CE region is required for the “theoretical” complete GBM’s resection; however, GTR of CE tumors has been recognized as the maximal resection for standardized treatment.

The consensus among neurosurgeons regarding maximal resection is desirable as long as it does not compromise the neurological function.^{1,2,8-14)} The fluid-attenuated inversion recovery (FLAIR) lesion around the CE area is the site where tumor cells infiltrate the edematous brain paren-

Received November 2, 2022; Accepted April 17, 2023

Copyright © 2023 The Japan Neurosurgical Society

This work is licensed under a Creative Commons Attribution-NonCommercial-NoDerivatives International License.

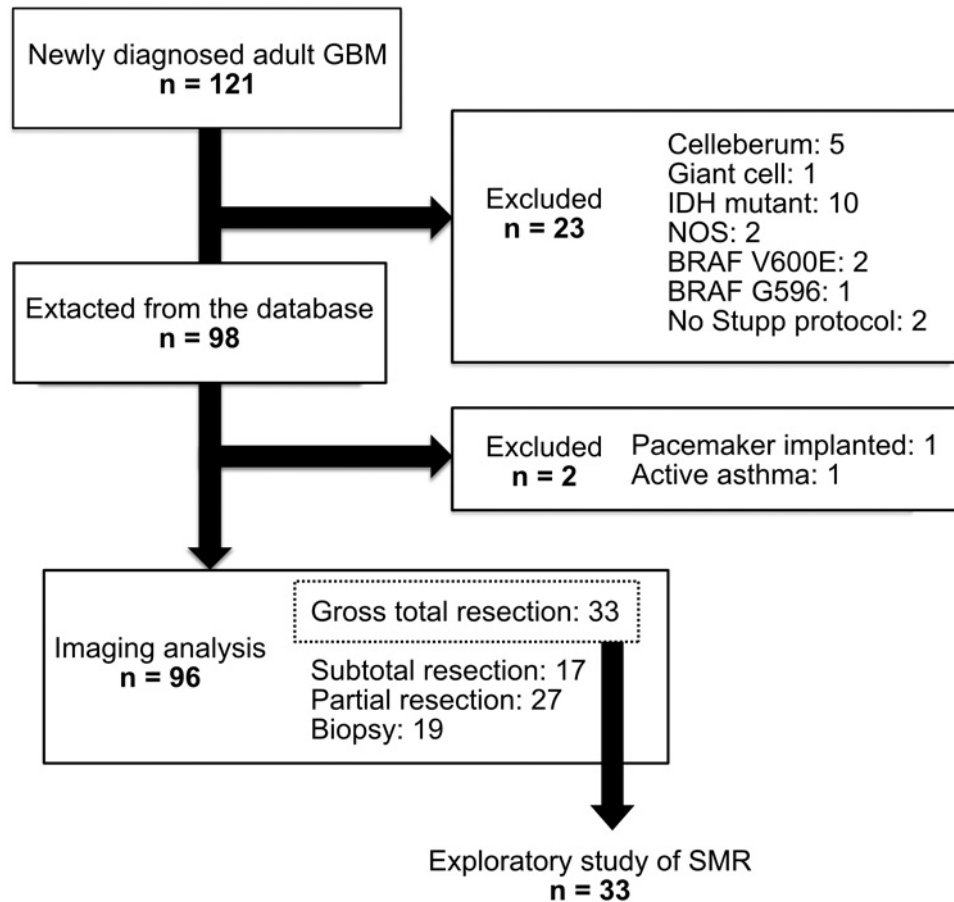


Fig. 1 Flowchart of the study's patient selection process.

chyma, and the density of tumor cells decreases continuously toward the periphery.¹⁵⁾ Accordingly, expanding the excision to the FLAIR lesion reduces the volume of infiltrating tumor cells but can compromise the damage to normal brain tissues. For surgeons, balancing functional preservation with the resection of infiltrating tumors complicates their decision-making process. Although several reports on the expanded resection of FLAIR lesions lead to a favorable prognosis,^{14,16-24)} consensus for optimizing the resection rate of FLAIR lesions is not established. In this study, we aimed to explore the quantity of FLAIR lesion resection beyond CE tumors and analyzed the clinical effects of supramaximal resection (SMR).

Materials and Methods

Patients

We enrolled 121 adult patients (age > 18 years) with newly diagnosed GBM from our database between December 2006 and August 2018. The patients were treated as previously described.²⁵⁾ Patients were excluded based on previously described criteria.²⁶⁾ Patients with BRAF mutations were also excluded because they comprise a distinct biological subgroup of GBM.²⁷⁻²⁹⁾ Two patients were ex-

cluded because of a lack of adjuvant therapy with the Stupp regimen. One patient who could not undergo magnetic resonance imaging (MRI) due to a cardiac pacemaker implant and one patient who could not undergo CE MRI due to active bronchial asthma were excluded. Finally, 96 patients were enrolled in this study (Fig. 1). In Japan, bevacizumab can be used with temozolomide as a first-line treatment. However, bevacizumab is used as a second-line chemotherapy for cases with subtotal or more resection at our institution; therefore, all cases used in the final analysis (gross total or more resection) were treated without first-line bevacizumab. Our local ethics committee approved this study (Kyushu University Institutional Review Board for Clinical Research: 848-00). This study followed the 1964 Declaration of Helsinki (as revised in Fortaleza, Brazil, October 2013). Written informed consent was obtained from all patients.

Neuroimaging findings

MRI scans were using a 1.5- or 3-T scanner. For each patient, pre- and postoperative neuroimages on FLAIR and gadolinium-enhanced T1-weighted imaging were evaluated. Preoperative scans were acquired within 10 days before surgery, and postoperative scans were acquired within 48 h

after surgery. The tumor location in the non-eloquent cortex was defined as the right frontal/temporal/occipital or left occipital, as described by Shah et al.²³⁾ According to the previous study,²⁴⁾ tumors were classified into two groups according to whether or not the CE tumor was in contact with the cortical gray matter. The association with the lateral ventricles (LVs) was classified based on the location of the CE tumor as contact with the subventricular zone (SVZ).³⁰⁻³³⁾ Based on Lim et al.'s classification, tumor depth was divided into two groups depending on whether or not the cortex was included.³⁰⁾ In their classification, groups I and III were cortical, and II and IV were the deep-seated groups. Pre- and postoperative tumor volumes were quantified with a three-dimensional imaging and analysis system volume analyzer of DICOM image, Synapse Vincent software version 5.5.0007 (Fujifilm, Tokyo, Japan). The CE T1-weighted tumor volume and FLAIR abnormality volume beyond the CE tumor were calculated by manually selecting the region of interest evaluated with subsequent automatic computerization of the volumetric data. An experienced neurosurgeon, blinded to the patients' clinical characteristics or prognosis, performed the volume analysis. Pre- and postoperative CE volumes and FLAIR abnormality volumes were measured directly. CE volume was the area of increased signal intensity on CE T1-weighted images. FLAIR volume beyond CE was the hyperintense area on FLAIR around the CE area. FLAIR hyperintense volume beyond the CE was calculated as follows. FLAIR abnormality volume, including the CE region, was measured directly, and the CE volume was subtracted from the FLAIR volume. As supplementary data collection, postoperative FLAIR images of SMR were observed to detect where the FLAIR area spontaneously regressed. If present, the volume of FLAIR was measured using the same method.

Classification of tumor resection

GTR was 100% resection of the CE tumor, subtotal resection (STR) was $\geq 90\%$ tumor resection, and partial resection was $< 90\%$ tumor resection. Biopsy was defined as an operation for diagnosis without tumor reduction. This classification of tumor resection was based on the image analysis of tumor volume before and after surgery.

SMR was the resection of FLAIR around the CE tumor beyond a certain threshold value, along with GTR. The optimum threshold for FLAIR reduction was obtained by moving the threshold value in 10% increments from 0%.

Genetic analyses

Sample preparation and subsequent confirmation of genetic signatures whose clinical significance was revealed in previous studies, including ours, were performed as described previously.^{27-29,34-38)}

Statistical analyses

Clinical and molecular characteristics were evaluated us-

ing the chi-square, Mann-Whitney U, and Fisher's exact tests. The Kaplan-Meier analysis was performed to evaluate OS, and the log-rank test was used to compare survival distributions.

Univariate and multivariate Cox proportional hazards models were used to investigate the associations between the variables and OS. Changes in Karnofsky Performance Scale (KPS) scores before and after surgery between SMR and GTR were compared using a paired t-test. The level of statistical significance was set at $p < 0.05$. All statistical analyses were performed using JMP Pro, version 13.2 (SAS Institute Inc., Cary, NC, USA).

Results

Background characteristics

In the enrolled 96 patients, GTR was achieved in 33 (34.3%) patients. For these patients, we performed maximal safe resection of the CE lesion guided by 5-aminolevulinic acid (5-ALA) with a multiple operation support system, including neuro-navigation and neurophysiological monitoring. The clinical characteristics and molecular genetic features of the 33 patients are summarized in Supplementary Table S1. The median age of the patients was 64 (range, 36-79) years. The median KPS score was 90 (20-100). The mean preoperative CE tumor volume was 30.2 (0.31-143.8) cm^3 . The mean residual volume on FLAIR was 57.6 (0-153.4) cm^3 , and the mean resection ratio on FLAIR was 21.9% (-752-100) (Fig. 2A). In our study, less than 0% FLAIR resection, inferring that the FLAIR hyperintensity region enlarged postoperatively, was found in 11 (33.3%) patients, similar to that found in previous studies.^{16,23)}

Survival outcome of radiographic findings

To determine the suitable threshold of the FLAIR resection ratio for the positive effect of the outcome, we changed the cut-off value from 0% to 50% and performed Kaplan-Meier analysis (Fig. 2B). Survival prolongation was observed in patients who underwent resection of $\geq 30\%$ of the FLAIR lesions. Therefore, we defined SMR as cases in which more than 30% FLAIR resection beyond GTR was achieved. The patients' backgrounds in SMR and GTR are shown in Supplementary Table S2. SMR included more females. However, the two groups had no significant differences, including age, KPS, tumor size, and pMGMT methylation status.

Association between extent of resection and overall survival classified by tumor depth

When SMR is defined by the volume reduction of the FLAIR hyperintense area, the situations in which SMR can be achieved differ between cortical and deep-seated tumors. Figure 3A-B and D-E show that the resection rate of the FLAIR hyperintense area of deep-seated tumors is

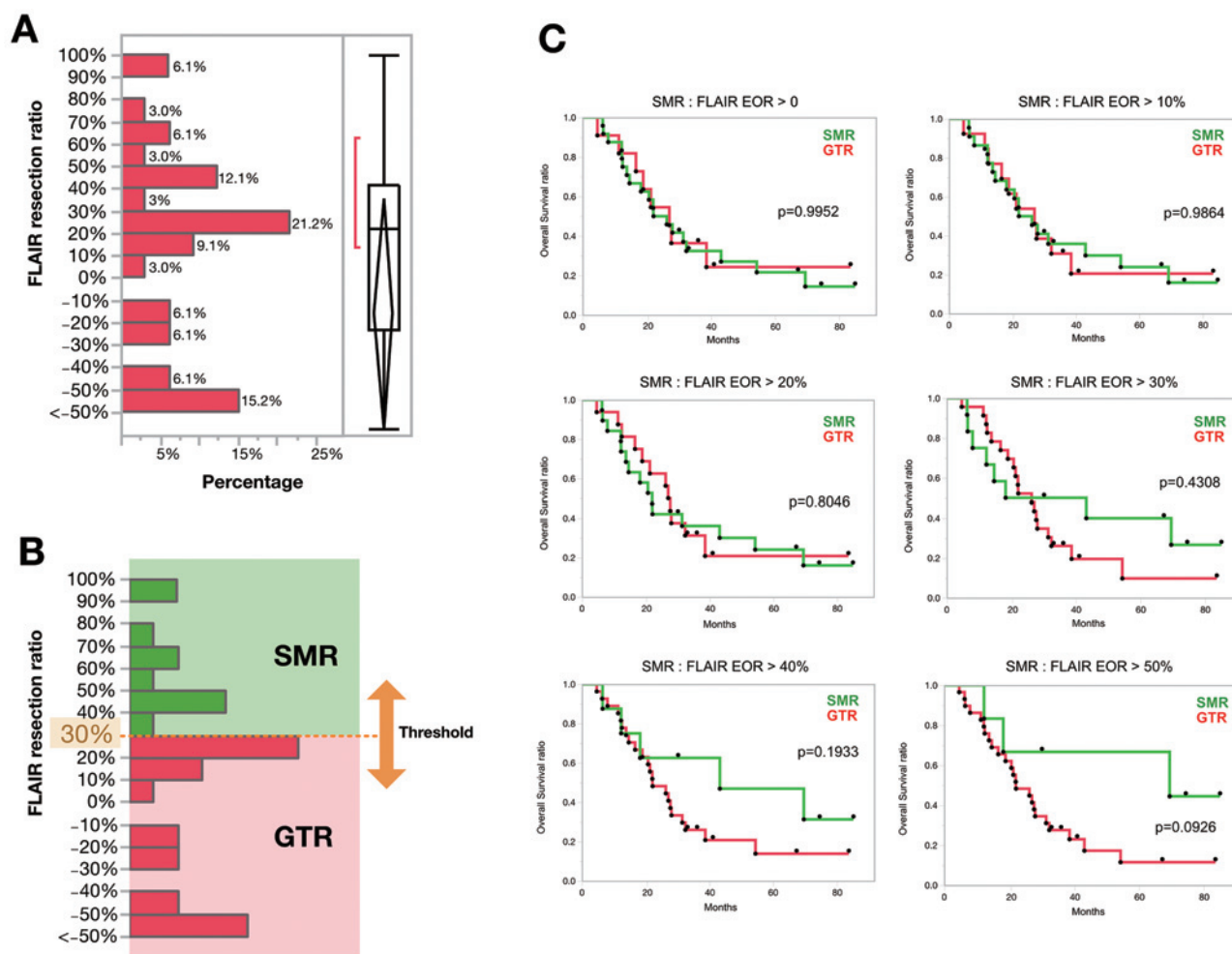


Fig. 2 Exploratory analyses of supramaximal resection (SMR) in 33 patients who underwent gross total resection (GTR) of glioblastoma.

(A) Histogram showing the distribution of the fluid-attenuated inversion recovery (FLAIR) resection ratio (percent). (B) The threshold of the FLAIR resection rate, defining SMR, was increased from 0% to 50% by 10%. The figure shows an example with a threshold of 30%. (C) The Kaplan-Meier analysis of survival to examine FLAIR resection rates, defining the SMR. Although there was no difference between the two groups when the cut-off value was 0-20%, the survival rate of the SMR group increased when the cut-off value was 30% or more.

overestimated compared with that of cortical tumors because a certain volume reduction of the hyperintense FLAIR area was obtained during corticotomy of the surgical corridor for the resection of deep-seated tumors. Such situations resulted in “apparent” SMR, in which the volume reduction of infiltrating tumor cells beneath the enhanced tumor is inefficient. Furthermore, the Kaplan-Meier curves in Fig. 4A show that deep-seated tumors had significantly shorter OS than cortical tumors (median OS was 20.9 months and 31.5 months, respectively; $p = 0.0342$), indicating that the cortical and deep-seated groups had different characteristics. Based on this concept and findings, we divided 33 patients with GTR into two groups, cortical ($n = 23$) and deep-seated ($n = 10$), according to the depth of the tumor (Supplementary Table S1, S3). The association

between the extent of resection and OS was analyzed for each group (Fig. 4B-C). In the cortical group, SMR tended to prolong OS compared with GTR, with the median OS of 69.6 and 22.1 months, respectively ($p = 0.0945$). By contrast, in the deep-seated group, SMR significantly shortened OS compared with GTR, with median OS of 10.2 and 27.9 months, respectively ($p = 0.0221$), suggesting that SMR was associated with unfavorable outcomes. In univariate Cox proportional hazards regression analysis of the cortical group, unmethylation of the O(6)-methylguanine-DNA methyltransferase promoter (pMGMT) (hazard ratio [HR], 5.17; 95% confidence interval [CI], 1.56-17.15; $p = 0.0073$) was associated with shorter OS (Table 1). Additionally, achievement of SMR may be associated with a longer OS (HR, 0.37; 95% CI, 0.11-1.23; $p = 0.1053$). Conversely,

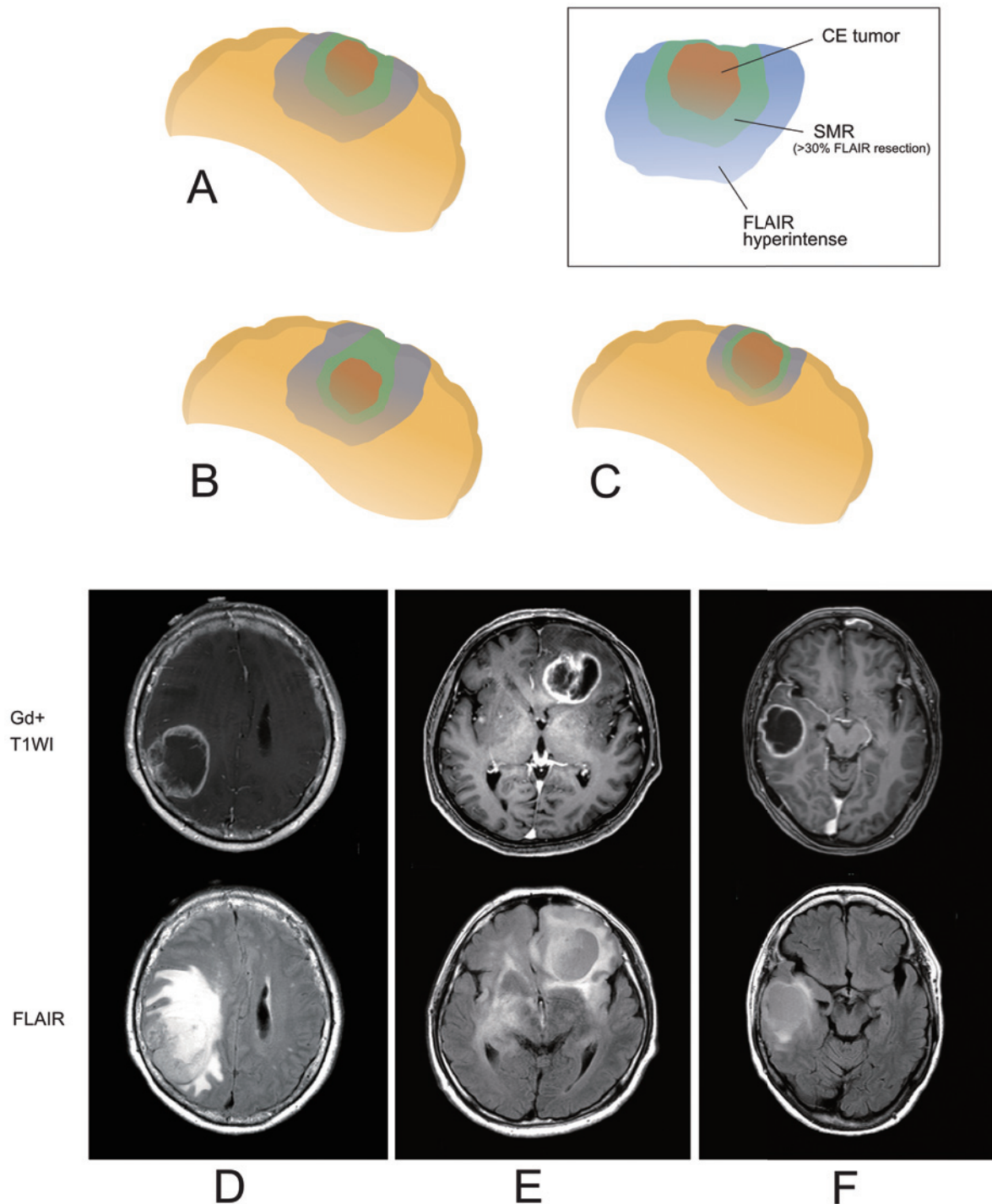


Fig. 3 Schema and representative magnetic resonance images of supramaximal resection (SMR).

(A-C): Schema showing the situations affecting SMR achievement. Contrast-enhanced tumors and surrounding fluid-attenuated inversion recovery (FLAIR) lesions are shown as red- and blue-colored areas, respectively. The FLAIR lesions to be resected for SMR achievement are shown in green-colored. (A) Example of a cortical tumor in a normal situation. (B) Example of a deep-seated tumor in which the FLAIR lesion on the surface is readily resected during conventional gross total resection (GTR). (C) An example case in which the FLAIR lesion was extremely localized outside the contrast enhancement area. SMR can be achieved with standard surgical procedures for GTR in the situations described in Figures (B) and (C).

(D-F): Magnetic resonance images of representative cases showing a, b, and c situations. (D): A cortical tumor in a normal situation. (E): A deep-seated tumor. (F): A cortical tumor with a localized FLAIR lesion.

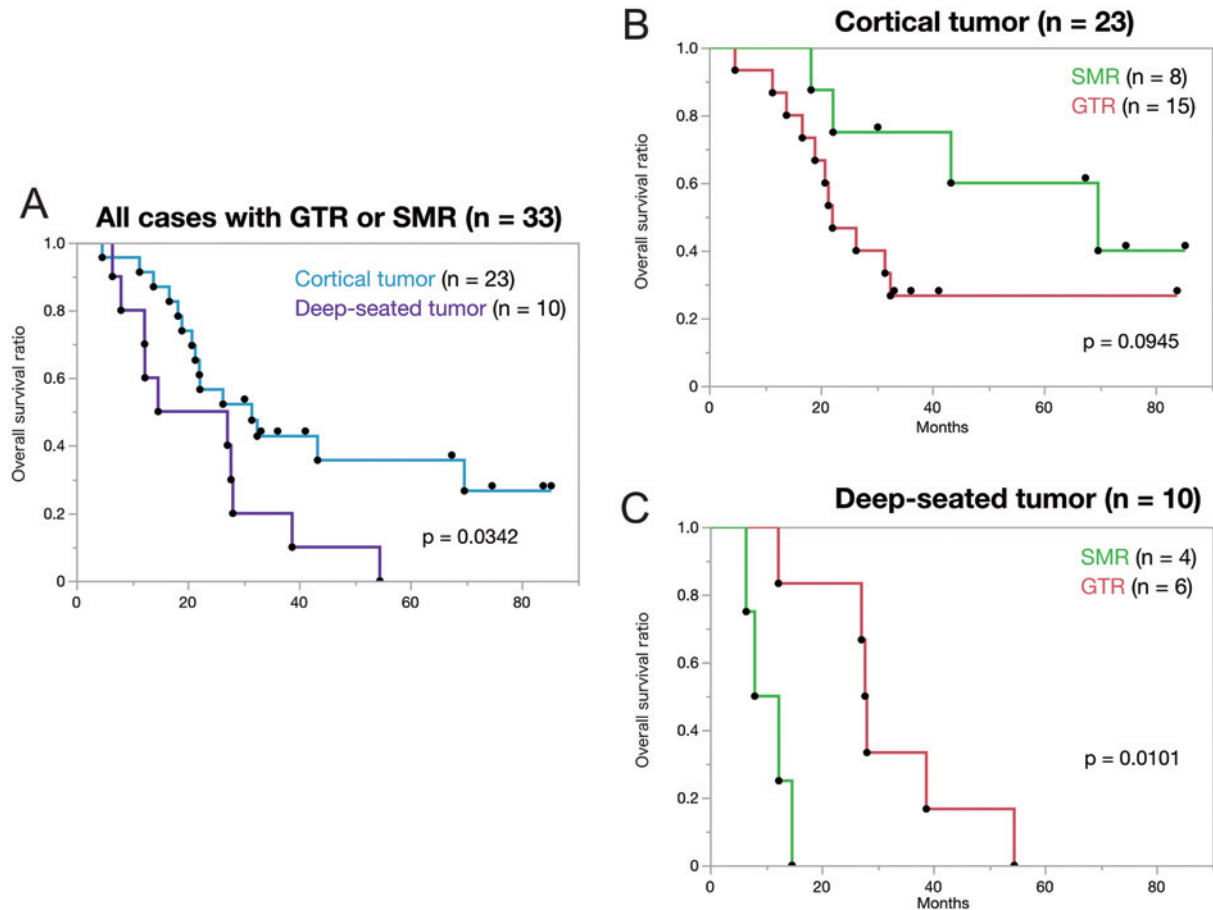


Fig. 4 The Kaplan-Meier plot shows the difference in OS between patients with cortical and deep-seated tumors.

(A): Patients with deep-seated tumors had significantly shorter OS than those with cortical tumors (median OS was 20.9 months and 31.5 months, respectively; $p = 0.0342$).

(B-C): Survival analysis showing survival rates by a degree of excision classified by tumor depth. The supramaximal resection (SMR) group had a longer survival in tumors that included the cortex. The median overall survival (OS) periods in SMR and gross total resection (GTR) were 69.6 and 22.1 months, respectively ($p = 0.0945$). Conversely, the order was reversed in the deep-seated tumors, and the median OS periods of SMR and GTR were 10.2 and 27.9 months, respectively ($p = 0.0101$).

pMGMT status did not affect OS in the deep-seated group, and achievement of SMR significantly worsened OS (HR, 10.80; 95% CI, 1.17-99.65; $p = 0.0358$). Consequently, the association between SMR and OS appeared to be contrary between cortical and deep-seated GBMs. Multivariate analyses, including age, pMGMT status, and SMR in cortical and deep-seated groups, were performed (Supplementary Table S4). In the cortical tumor, unmethylated pMGMT was also associated with poor prognosis (HR, 6.01; 95% CI, 1.55-23.28; $p = 0.0095$), while an effect of SMR was not observed. In the deep-seated tumor, only SMR was significantly associated with shortened OS (HR, 12.83; 95% CI, 1.28-128.59; $p = 0.0300$). In multivariate analysis combining deep-seated and cortical tumors, unmethylated pMGMT alone significantly affected OS (HR, 2.83; 95% CI, 1.14-7.03; $p = 0.0249$) (Supplementary Table S5).

Age groups and the effect of SMR

As a supplementary analysis, we divided the patients into two groups according to age to observe the effect of SMR because there was a difference in age between the deep and superficial groups (Supplementary Table S1). The Kaplan-Meier analysis showed no significant observable effect of SMR on OS in the young or elderly group (Supplementary Figure S1).

Spontaneous regression of FLAIR in SMR

In some cases of SMR, spontaneous regression of FLAIR occurred after surgery. Four of twelve SMR cases (three of eight cortical and one of four deep-seated) showed decreased FLAIR outside the excised cavity. The median volume of non-tumor FLAIR regions in the four cases was 8.5 mL (range 5.9-10.2 mL), and the median FLAIR resection rate add-on was 4.0% (range 1.7-4.9%). Of these, one superficial case was originally GTR because the FLAIR resection

Table 1 Univariate analysis of the overall survival of patients with cortical and deep-seated tumors

Variable assessed	Cortical Tumors (n = 23)			Deep-seated Tumors (n = 10)		
	Number of Cases (%)	HR (95% CI)	p-value	Number of Cases (%)	HR (95% CI)	p-value
Age ≥ 65 years	8 (34.8)	1.87 (0.66–5.29)	0.2412	8 (80.0)	0.70 (0.14–3.57)	0.6686
Age < 65 years	15 (65.2)	1.00		2 (20.0)	1.00	
Male sex	14 (60.9)	1.93 (0.64–5.78)	0.2412	5 (50.0)	0.36 (0.09–1.55)	0.1711
Female sex	9 (39.1)	1.00		8 (50.0)	1.00	
KPS score < 70	6 (26.1)	1.52 (0.52–4.47)	0.4479	1 (10.0)	3.97 (0.36–43.93)	0.2606
KPS score ≥ 70	17 (73.9)	1.00		9 (90.0)	1.00	
Unmethylated pMGMT	10 (43.5)	5.17 (1.56–17.15)	0.0073*	5 (50.0)	0.95 (0.25–3.58)	0.9429
Methylated pMGMT	13 (56.5)	1.00		5 (50.0)	1.00	
Supramaximal resection	8 (34.8)	0.37 (0.11–1.23)	0.1053	4 (40.0)	10.80 (1.17–99.65)	0.0358*
Gross total resection	15 (65.2)	1.00		6 (60.0)	1.00	
with BCNU	11 (47.8)	0.65 (0.23–1.84)	0.4177	4 (40.0)	3.95 (0.70–22.13)	0.1183
without BCNU	12 (52.2)	1.00		6 (60.0)	1.00	
Contacted with LVs	12 (52.2)	1.00 (0.34–2.91)	0.9994	8 (80.0)	3.05 (0.37–25.12)	0.3003
Uncontacted with LVs	11 (47.8)	1.00		2 (20.0)	1.00	

Asterisk indicates statistical significance ($p < 0.05$); CI, confidence interval; HR, hazard ratio; KPS, Karnofsky Performance Scale; LV, lateral ventricles; pMGMT, O (6)-methylguanine-DNA methyltransferase promoter

rate was <30% when the FLAIR area was removed from the preoperative FLAIR.

Analysis of IDH-mutant tumor

A similar study on 10 patients (excluded cases) with histologically diagnosed glioblastoma and molecularly diagnosed as IDH-mutant was performed as a supplementary analysis. Four cases had no CE lesion, and in four cases, subtotal or less resection had been performed. Only in two cases had GTR been performed, and both were classified as cortical tumors. One of these cases had a 30.9% FLAIR resection rate, corresponding to SMR when applied to our threshold for IDH-wildtype. Supplementary Table S6 summarizes the backgrounds of one case of GTR and one case of SMR. The KPS score in the SMR case was clearly lower than that in the GTR case, the CE tumor volume was approximately three times larger than that in GTR cases, and the residual FLAIR volume was about two times larger than that in GTR cases. The OS for GTR and SMR was 47.8 months and 45.2 months, respectively.

Discussion

Definition of supramaximal resection (SMR) and its effects on prognosis

In this study, we defined SMR by volumetric analyses of the resection rate using FLAIR images and evaluated its effects on molecularly diagnosed GBM with homogeneous clinical backgrounds. In previous studies, various definitions of SMR, such as additional resection of more than 1 cm surrounding the CE tumor,²⁰⁾ complete resection of FLAIR,¹⁹⁾ and addition of lobectomy,^{21,23)} were applied. Although these definitions may ensure the uniformity of sur-

gical procedures, achieving SMR depends on clinical situations, such as tumor location and FLAIR distribution, leading to selection bias and less versatility. The advantages of the SMR definition based on volumetric analysis, such as ours, are tumor location independence and objectivity maintenance. Moreover, we did not set any inclusion criteria based on the operative method, including awake surgery or intraoperative imaging.¹⁷⁾ To determine the optimal FLAIR resection threshold for the definition of SMR, we changed the cut-off values in stepwise increments of 10% each (Fig. 2B-C). As the OS prolongation associated with SMR appeared around the threshold exceeding 30%, as shown in Fig. 2C, we defined SMR as more than 30% of the FLAIR resection. The results were variable in previous reports, in which SMR was determined using volumetric analysis. Li et al. reported that the prognosis improved by 53.21% or more.¹⁶⁾ Vivas et al. reported that a 20–50% FLAIR reduction threshold positively affected OS prolongation.²⁴⁾ However, notably, the former studies were not designed based on the World Health Organization 2016 criteria; thus, these previous studies seemed to include a certain number of patients with molecularly lower grade gliomas, possibly resulting in the overrating of the SMR effect because volume reduction of FLAIR lesion likely relates to OS improvement for lower grade glioma more than for GBM. Nonetheless, the threshold for FLAIR resection differs; various studies, including ours, suggest that extended excision of the surrounding FLAIR lesion above a certain level should positively affect the prognosis of patients with GBM.

Our study showed no significant difference in postoperative KPS scores between the SMR and GTR groups (Supplementary Figure S2). It is concerning that intentional

SMR can compromise the postoperative performance status of patients. In this study, we retrospectively analyzed the SMR effect in a cohort in which the extent of resection outside the CE area was not designed preoperatively. Although a maximal safe resection was performed using 5-ALA, preservation of neurological function should be the top priority using surgical support systems, such as electrophysiological monitoring and neuro-navigation. Direct evaluation with neuropsychological tests is also used during awake surgery, as needed. Such standardized surgery ensured safety in the SMR and GTR groups and prevented deterioration of functional outcomes in our cohort. It is desirable to evaluate the performance status before and after the surgery to evaluate whether or not SMR negatively affects neurological prognosis in future clinical trials to assess the clinical significance of SMR.

Effect of SMR depending on tumor depth

Our results indicate that the outcome effects of SMR differ greatly depending on tumor depth. SMR may have an advantage in prolonging OS in cortical GBM but may negatively impact OS in deep-seated tumors (Table 1, Fig. 4B-C). Since deep-seated tumors were significantly older than cortical tumors (Supplementary Table S1), the effect of SMR was evaluated by age as a supplementary analysis; no significant difference was seen (Supplementary Figure S2). This result suggests that the difference in the effect of SMR was due to the difference between cortical and deep-seated positions, not due to age. Furthermore, these findings did not change with the addition of the two IDH-mutant cases (data not shown).

There are four possible reasons for the difference in the efficacy of SMR between cortical and deep-seated tumors.

First, a difference in resection patterns in FLAIR lesions between cortical and deep-seated tumors exists. Since SMR is defined by the resection rate of FLAIR lesions, SMR for deep-seated tumor seems to be readily achieved during uncapping of the tumor surface, and volume reduction of the surrounding FLAIR lesion of the CE tumor is not always necessary. We consider such a situation as “apparent” SMR, inducing confusion in evaluating the clinical effects of SMR, which is expected to prevent local recurrences from surrounding tissues beneath the CE lesions. Second, deep-seated tumors may affect the degree of fluorescence of 5-ALA. Although 5-ALA fluorescence seems to coincide with blood-brain barrier disruption regions,^{39,40)} CE regions, it has been reported that even unenhanced lower grade gliomas are latently fluorescent.⁴¹⁾ One study reported that 5-ALA fluorescent lesions beyond the CE tumor corresponded with preoperative hyperintense areas using neuro-navigation during operation.⁴²⁾ Considering that deep-seated tumors are more aggressive, the deep-seated SMR group is possibly within the range where fluorescence was observed to be wider. However, the relationship between the 5-ALA fluorescent region and the FLAIR-hyper region

in the relevant case is inconclusive. We can only speculate at this stage since this is a retrospective study, and we cannot perform intraoperative MRI at our facility. Third, deep-seated tumors have a high proportion of contact with the LVs owing to their localization. Previous studies suggested that CE lesions of GBM bordering the LVs would have a worse prognosis because neural progenitor cells in the SVZ may potentially initiate tumors and increase malignancy.³⁰⁻³³⁾ Deep-seated tumors may harbor innate aggressive bioactivities that differ from those of cortical tumors. Patients with deep-seated tumors had a significantly shorter OS than those with cortical tumors among 33 cases in which GTR or higher was performed (Fig. 4A). Finally, the cases used in this analysis may be biased, a major concern of our small cohort. The number of deep-seated tumors was limited to only ten, of which only four had SMR. Supplementary Table S3 shows that the median volume of CE tumors in the SMR group among the deep-seated tumors was more than three times larger than in the GTR group, which means that patients with a shorter OS may be clustered in the SMR group. Therefore, our results should be interpreted with caution, and it cannot be generalized that SMR has a negative effect on deep-seated tumors based on our cohort alone. The effect of SMR on deep-seated tumors must be validated in larger cohorts.

Issues to be considered in the future

We defined SMR based on volumetric analyses comparing FLAIR lesions between pre- and postoperative images; however, the decrease in FLAIR after surgery is not limited to the effect of resection. The FLAIR hyperintensity decreases regardless of resection when the FLAIR hyperintensity before surgery reflects vasogenic edema. Previous research for SMR on GBM also pointed out that preoperative FLAIR hyperintense regions may include tumor infiltration and vasogenic edema.^{16,24,42)} However, no reports in which FLAIR volume spontaneously regressed were evaluated. In our research, four of twelve SMR cases included a FLAIR region that spontaneously regressed after surgery, and the FLAIR resection rate was overestimated by 4.0% (range 1.7-4.9%). We emphasize that the resection class may change depending on whether spontaneous regression is subtracted in cases close to the threshold, when the reduction rate of FLAIR volume defines SMR before and after surgery. Theoretically, delineating the range of tumors using FLAIR images should be performed to distinguish between non-CE tumors and nonspecific FLAIR hyperintensities, such as edema. Quantifying FLAIR signal intensity to identify nonspecific hyperintensities⁴²⁾ or combining other MR image sequences or radiological facilities, such as positron emission tomography, might resolve this issue.^{42,43)} Moreover, the CE/FLAIR ratio of the tumor varies in each case. If the FLAIR lesion around the CE tumor shows the localized distribution, even standard tumor resection can meet the SMR criterion (Fig. 3C, F). These issues should be con-

sidered in SMR studies, such as ours. To overcome these issues, considerable inclusion criteria should be incorporated into future prospective studies. Specifically, it is essential to assess the feasibility of SMR using preoperative images for each case, to set the planning in advance according to the volumetric simulation, and then to perform the operation according to the preoperative plan using a navigation system or intraoperative images. To elucidate the clinical effects of SMR, a prospective study should exclude cases in which lobectomy and sufficient margin resection cannot be tolerated due to tumor localization beneath the eloquent area.

Limitation

This study has some limitations. We conducted a retrospective study analyzing a cohort from a single center and set strict exclusion criteria; the final cohort size was small. As GBMs show complicated infiltration patterns, varying greatly among cases, volumetric analyses cannot be performed automatically; therefore, the possibility of human error cannot be ruled out completely. Although we detected no significant difference in KPS scores before and after surgery, a neuropsychological examination must evaluate detailed functional outcomes for an intricate neurological and cognitive function evaluation. Taken together, prospective trials must validate the evidence for the clinical effects of SMR accumulated by retrospective studies, including ours.

In conclusion, our results indicate that extended resection of FLAIR lesions beyond CE tumors can prolong survival in patients with GBM. When FLAIR lesion resection of $\geq 30\%$ was defined as SMR, survival was significantly longer than that in patients with cortical GBMs. As the outcome effects of SMR differed greatly depending on tumor depth, tumor location should be considered when defining SMR based on volumetric analysis. Further studies are needed to support our findings and evaluate the clinical effects of SMR.

Supplementary Material

<https://doi.org/10.2176/jns-nmc.2022-0351>

Acknowledgments

We want to thank Editage (www.editage.com) for English language editing.

Funding

This work was supported by the Japanese Society for the Promotion of Science Grants-in-Aid for Scientific Research (JSPS KAKENHI) (Grant Nos. 19K17673, 21H03044, 21K09128, 20K17972, and JP20K09392).

Data Availability

The datasets generated during and/or analyzed during the current study are available from the corresponding author upon reasonable request.

Ethics Approval

Our local ethics committee (Kyushu University Institutional Review Board for Clinical Research: 848-00) approved this study. The study followed the 1964 Declaration of Helsinki (as revised in Fortaleza, Brazil, October 2013).

Author Contributions

Conception and design: NH, RO, MM, YFun, DK, YS, YFuj, KT, KY

Funding acquisition: NH, DK, RH, YS, MM

Provision of study material or patients: NH, DK, RH, YS, YFuj, OT, KK, TY, HY, MM, KY

Technical support: AS

Collection and assembly of data: RO, YFun, KT, NH, DK, RH, YS, YFuj

Image analysis: RO

Statistical analysis: RO, YFun

The first draft of the manuscript: RO

Reviewing and editing the manuscript: All authors

Accountable for all aspects of the work: All authors

All authors have read and approved the manuscript.

Conflicts of Interest Disclosure

The authors declare no conflict of interest.

References

- 1) Lacroix M, Abi-Said D, Fourney DR, et al.: A multivariate analysis of 416 patients with glioblastoma multiforme: prognosis, extent of resection, and survival. *J Neurosurg* 95: 190-198, 2001
- 2) Sanai N, Polley MY, McDermott MW, Parsa AT, Berger MS: An extent of resection threshold for newly diagnosed glioblastomas. *J Neurosurg* 115: 3-8, 2011
- 3) Dandy WE: Removal of right cerebral hemisphere for certain tumors with hemiplegia. *JAMA* 90: 823-825, 1928
- 4) Matsukado Y, Maccarty CS, Kernohan JW: The growth of glioblastoma multiforme (astrocytomas, grades 3 and 4) in neurosurgical practice. *J Neurosurg* 18: 636-644, 1961
- 5) Kelly PJ, Daumas-Duport C, Kispert DB, Kall BA, Scheithauer BW, Illig JJ: Imaging-based stereotaxic serial biopsies in untreated intracranial glial neoplasms. *J Neurosurg* 66: 865-874, 1987
- 6) Cuddapah VA, Robel S, Watkins S, Sontheimer H: A neurocentric perspective on glioma invasion. *Nat Rev Neurosci* 15: 455-465, 2014
- 7) Vollmann-Zwerenz A, Leidgens V, Feliciello G, Klein CA, Hau P: Tumor cell invasion in glioblastoma. *Int J Mol Sci* 21: 1932, 2020
- 8) Chaichana KL, Jusue-Torres I, Navarro-Ramirez R, et al.: Establishing percent resection and residual volume thresholds affect-

- ing survival and recurrence for patients with newly diagnosed intracranial glioblastoma. *Neuro Oncol* 16: 113-122, 2014
- 9) Grabowski MM, Recinos PF, Nowacki AS, et al.: Residual tumor volume versus extent of resection: predictors of survival after surgery for glioblastoma. *J Neurosurg* 121: 1115-1123, 2014
 - 10) Hadjipanayis CG, Widhalm G, Stummer W: What is the surgical benefit of utilizing 5-aminolevulinic acid for fluorescence-guided surgery of malignant gliomas? *Neurosurgery* 77: 663-673, 2015
 - 11) Hervey-Jumper SL, Berger MS: Maximizing safe resection of low- and high-grade glioma. *J Neurooncol* 130: 269-282, 2016
 - 12) Haj A, Doenitz C, Schebesch KM, et al.: Extent of resection in newly diagnosed glioblastoma: impact of a specialized neuro-oncology care center. *Brain Sci* 8: 5, 2017
 - 13) Matsuda M, Kohzaki H, Ishikawa E, et al.: Prognostic analysis of patients who underwent gross total resection of newly diagnosed glioblastoma. *J Clin Neurosci* 50: 172-176, 2018
 - 14) Molinaro AM, Hervey-Jumper S, Morshed RA, et al.: Association of maximal extent of resection of contrast-enhanced and non-contrast-enhanced tumor with survival within molecular subgroups of patients with newly diagnosed glioblastoma. *JAMA Oncol* 6: 495-503, 2020
 - 15) Chang PD, Malone HR, Bowden SG, et al.: A multiparametric model for mapping cellularity in glioblastoma using radiographically localized biopsies. *AJNR Am J Neuroradiol* 38: 890-898, 2017
 - 16) Li YM, Suki D, Hess K, Sawaya R: The influence of maximum safe resection of glioblastoma on survival in 1229 patients: can we do better than gross-total resection? *J Neurosurg* 124: 977-988, 2016
 - 17) Eyüpoglu IY, Hore N, Merkel A, Buslei R, Buchfelder M, Savaskan N: Supra-complete surgery via dual intraoperative visualization approach (DiVA) prolongs patient survival in glioblastoma. *Oncotarget* 7: 25755-25768, 2016
 - 18) Esquenazi Y, Friedman E, Liu Z, Zhu JJ, Hsu S, Tandon N: The survival advantage of "supratotal" resection of glioblastoma using selective cortical mapping and the subpial technique. *Neurosurgery* 81: 275-288, 2017
 - 19) Pessina F, Navarria P, Cozzi L, et al.: Maximize surgical resection beyond contrast-enhancing boundaries in newly diagnosed glioblastoma multiforme: is it useful and safe? A single institution retrospective experience. *J Neurooncol* 135: 129-139, 2017
 - 20) Glenn CA, Baker CM, Conner AK, et al.: An examination of the role of supramaximal resection of temporal lobe glioblastoma multiforme. *World Neurosurg* 114: e747-e755, 2018
 - 21) Roh TH, Kang SG, Moon JH, et al.: Survival benefit of lobectomy over gross-total resection without lobectomy in cases of glioblastoma in the noneloquent area: a retrospective study. *J Neurosurg* 132: 895-901, 2019
 - 22) Dimou J, Beland B, Kelly J: Supramaximal resection: a systematic review of its safety, efficacy and feasibility in glioblastoma. *J Clin Neurosci* 72: 328-334, 2020
 - 23) Shah AH, Mahavadi A, Di L, et al.: Survival benefit of lobectomy for glioblastoma: moving towards radical supramaximal resection. *J Neurooncol* 148: 501-508, 2020
 - 24) Vivas-Buitrago T, Domingo RA, Tripathi S, et al.: Influence of supramarginal resection on survival outcomes after gross-total resection of IDH-wild-type glioblastoma. *J Neurosurg* 136: 1-8, 2022
 - 25) Takigawa K, Hata N, Michiaki Y, et al.: Volumetric study reveals the relationship between outcome and early radiographic response during bevacizumab-containing chemoradiotherapy for unresectable glioblastoma. *J Neurooncol* 154: 187-196, 2021
 - 26) Hata N, Mizoguchi M, Kuga D, et al.: First-line bevacizumab contributes to survival improvement in glioblastoma patients complementary to temozolomide. *J Neurooncol* 146: 451-458, 2020
 - 27) Parsons DW, Jones S, Zhang X, et al.: An integrated genomic analysis of human glioblastoma multiforme. *Science* 321: 1807-1812, 2008
 - 28) Simon M, Hosen I, Gousias K, et al.: Tert promoter mutations: a novel independent prognostic factor in primary glioblastomas. *Neuro Oncol* 17: 45-52, 2015
 - 29) Hatae R, Hata N, Suzuki SO, et al.: A comprehensive analysis identifies BRAF hotspot mutations associated with gliomas with peculiar epithelial morphology. *Neuropathology* 37: 191-199, 2017
 - 30) Lim DA, Cha S, Mayo MC, et al.: Relationship of glioblastoma multiforme to neural stem cell regions predicts invasive and multifocal tumor phenotype. *Neuro Oncol* 9: 424-429, 2007
 - 31) Chaichana KL, McGirt MJ, Frazier J, Attenello F, Guerrero-Cazares H, Quinones-Hinojosa A: Relationship of glioblastoma multiforme to the lateral ventricles predicts survival following tumor resection. *J Neurooncol* 89: 219-224, 2008
 - 32) Chen L, Guerrero-Cazares H, Ye X, et al.: Increased subventricular zone radiation dose correlates with survival in glioblastoma patients after gross total resection. *Int J Radiat Oncol Biol Phys* 86: 616-622, 2013
 - 33) Mistry AM, Hale AT, Chambless LB, Weaver KD, Thompson RC, Ihrie RA: Influence of glioblastoma contact with the lateral ventricle on survival: a meta-analysis. *J Neurooncol* 131: 125-133, 2017
 - 34) Funakoshi Y, Hata N, Takigawa K, et al.: Clinical significance of CDKN2A homozygous deletion in combination with methylated MGMT status for IDH-wildtype glioblastoma. *Cancer Med* 10: 3177-3187, 2021
 - 35) Fujioka Y, Hata N, Akagi Y, et al.: Molecular diagnosis of diffuse glioma using a chip-based digital PCR system to analyze IDH, tert, and H3 mutations in the cerebrospinal fluid. *J Neurooncol* 152: 47-54, 2021
 - 36) Sturm D, Witt H, Hovestadt V, et al.: Hotspot mutations in H3F3A and IDH1 define distinct epigenetic and biological subgroups of glioblastoma. *Cancer Cell* 22: 425-437, 2012
 - 37) Arita H, Yamasaki K, Matsushita Y, et al.: A combination of tert promoter mutation and MGMT methylation status predicts clinically relevant subgroups of newly diagnosed glioblastomas. *Acta Neuropathol Commun* 4: 79, 2016
 - 38) Yoshimoto K, Hatae R, Sangatsuda Y, et al.: Prevalence and clinicopathological features of H3.3 G34-mutant high-grade gliomas: a retrospective study of 411 consecutive glioma cases in a single institution. *Brain Tumor Pathol* 34: 103-112, 2017
 - 39) Stummer W, Tonn JC, Goetz C, et al.: 5-aminolevulinic acid-derived tumor fluorescence: the diagnostic accuracy of visible fluorescence qualities as corroborated by spectrometry and histology and postoperative imaging. *Neurosurgery* 74: 310-319, 2014
 - 40) Stummer W, Suero Molina ES: Fluorescence imaging/agents in tumor resection. *Neurosurg Clin N Am* 28: 569-583, 2017
 - 41) Suero Molina ES, Black D, Kaneko S, Muther M, Stummer W: Double dose of 5-aminolevulinic acid and its effect on protoporphyrin IX accumulation in low-grade glioma. *J Neurosurg* 137: 943-952, 2022
 - 42) Certo F, Altieri R, Maione M, et al.: FLAIrectomy in supramarginal resection of glioblastoma correlates with clinical outcome and survival analysis: a prospective, single institution, case series. *Oper Neurosurg (Hagerstown)* 20: 151-163, 2021
 - 43) John F, Bosnyák E, Robinette NL, et al.: Multimodal imaging-defined subregions in newly diagnosed glioblastoma: impact on overall survival. *Neuro Oncol* 21: 264-273, 2019

Corresponding author: Nobuhiro Hata, MD, PhD

Department of Neurosurgery, Oita University Faculty of Medicine,
1-1 Idaigaoka, Hasamamachi, Yufu, Oita 879-5593, Japan.
e-mail: hatanobu66@oita-u.ac.jp