

UCSF

UC San Francisco Previously Published Works

Title

Effectiveness of sotalol as first-line therapy for fetal supraventricular tachyarrhythmias.

Permalink

<https://escholarship.org/uc/item/0954f488>

Journal

The American journal of cardiology, 109(11)

ISSN

0002-9149

Authors

Shah, Ameer
Moon-Grady, Anita
Bhogal, Neil
et al.

Publication Date

2012-06-01

DOI

10.1016/j.amjcard.2012.01.388

Peer reviewed

Effectiveness of Sotalol as First-Line Therapy for Fetal Supraventricular Tachyarrhythmias

Amee Shah, MD^a, Anita Moon-Grady, MD^{a,b}, Neil Bhogal, BSc^a, Kathryn K. Collins, MD^a, Theresa Tacy, MD^a, Michael Brook, MD^a, and Lisa K. Hornberger, MD^{a,*}

Fetal supraventricular tachycardia (SVT) and atrial flutter (AF) can be associated with significant morbidity and mortality. Digoxin is often used as first-line therapy but can be ineffective and is poorly transferred to the fetus in the presence of fetal hydrops. As an alternative to digoxin monotherapy, we have been using sotalol at presentation in fetuses with SVT or AF with, or at risk of, developing hydrops to attempt to achieve more rapid control of the arrhythmia. The present study was a retrospective review of the clinical, echocardiographic, and electrocardiographic data from all pregnancies with fetal tachycardia diagnosed and managed at a single center from 2004 to 2008. Of 29 affected pregnancies, 21 (16 SVT and 5 AF) were treated with sotalol at presentation, with or without concurrent administration of digoxin. Of the 21, 11 (6 SVT and 5 AF) had resolution of the tachycardia within 5 days (median 1). Six others showed some response (less frequent tachycardia, rate slowing, resolution of hydrops) without complete conversion. In 1 fetus with a slow response, the mother chose pregnancy termination. The 5 survivors with a slow response were all difficult to treat postnatally, including 1 requiring radiofrequency ablation as a neonate. One fetus developed blocked atrial extrasystoles after 1 dose of sotalol and was prematurely delivered for fetal bradycardia. Three grossly hydropic fetuses with SVT showed no response and died within 1 to 3 days of treatment. In conclusion, transplacental sotalol, alone or combined with digoxin, is effective for the treatment of fetal SVT and AF, with an 85% complete or partial response rate in our series. © 2012 Elsevier Inc. All rights reserved. (Am J Cardiol 2012;109:1614–1618)

Sotalol, a safe and effective antiarrhythmic in pediatric and adult patients, is also useful in fetuses. Sotalol has been used as a second-line agent to treat fetal supraventricular tachycardia (SVT) with mixed results.^{1–5} In 2000, Oudijk et al² reported discouraging results with sotalol in the treatment of fetal SVT because of the high fetal mortality associated with treatment. However, 3 of the 4 nonsurviving fetuses were grossly hydropic at presentation, a factor that likely contributed to their death. The same group subsequently documented good transplacental pharmacokinetics for sotalol⁵ and suggested, despite their earlier experience, that sotalol is still a reasonable choice for second-line fetal SVT therapy. Additionally, in studies of small cohorts of patients, sotalol appeared to have reasonable success in

treating both fetal atrial flutter⁶ and long ventricular-atrial (VA) SVT,⁷ 2 conditions for which digoxin alone is generally ineffective. These encouraging studies suggested that sotalol might be a good first-line medication for the treatment of these fetal arrhythmias. As a step toward determining the efficacy of sotalol as first-line therapy in the treatment of fetal SVTs, we retrospectively reviewed our experience managing fetal SVT and atrial flutter (AF) in a single center in which sotalol as first-line therapy was the preferred approach.

Methods

This was a descriptive retrospective study of all consecutively encountered pregnancies with fetal SVT evaluated and managed in our combined fetal cardiovascular program at the University of California, San Francisco, and University of California, Davis, from July 2004 to July 2008. The human subjects committees at both institutions approved the present study. Fetuses referred for tachycardia (>180 beats/min), who were found to have ventricular tachycardias, characterized by AV dissociation with ventricular rates in excess of the atrial rates, were excluded. The treatment protocol used by our fetal cardiovascular program is outlined in Figure 1. After a diagnosis of fetal SVT or AF, and before the initiation of sotalol, the pregnant mothers underwent a baseline electrocardiogram (ECG) with or without an echocardiogram and an adult cardiology consultation. Contraindications to sotalol administration included a maternal history of cardiac disease with dysfunction, maternal bra-

^aFetal Cardiovascular Program, Division of Cardiology, Department of Pediatrics and the Fetal Treatment Center, University of California, San Francisco, School of Medicine, San Francisco, California; ^bDivision of Cardiology, Department of Pediatrics, University of California, Davis, Davis, California. Manuscript received September 27, 2011; revised manuscript received and accepted January 26, 2012.

Dr. Shah is currently at Morgan Stanley Children's Hospital of New York Presbyterian, Columbia University Medical Center, New York, New York; Dr. Tacy is currently at Lucile Packard Children's Hospital, Stanford University, Palo Alto, California; Dr. Collins is currently at University of Colorado, Children's Hospital, Aurora, Colorado; and Dr. Hornberger is currently working at Fetal & neonatal Cardiology Program, Stollery Children's Hospital, University of Alberta, Edmonton, Alberta, Canada.

*Corresponding author: Tel: (780) 407-3355; fax: 780-407-3310.

E-mail address: lisa.hornberger@albertahealthservices.ca (L. Hornberger).

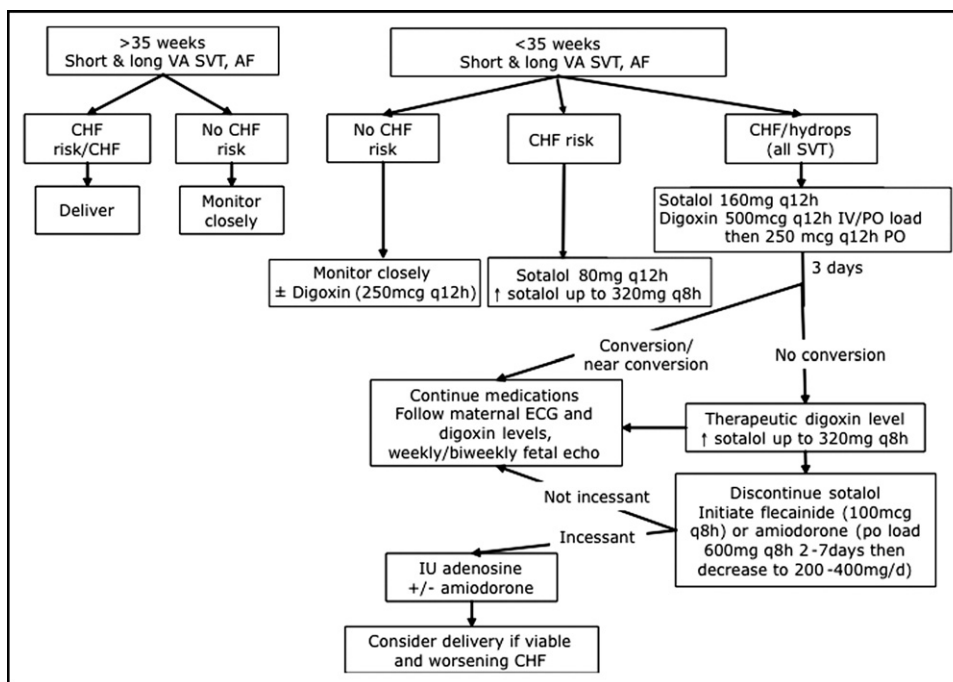


Figure 1. Treatment algorithm for fetal tachycardias at our institution. CHF = congestive heart failure.

dyscardia, and/or prolonged QTc. QTc-prolonging medications were discontinued, including antiemetics. The mothers were admitted to a nontelemetry bed on the obstetrical ward and had continuous fetal heart rate monitoring (or intermittent fetal heart rate monitoring 2 to 4 times daily, if pre-viable or if continuous monitoring was not feasible). The mothers were kept under observation during the initiation of sotalol or sotalol and digoxin therapy (digoxin added either at the treating physician's discretion or if it was believed that the β blockade effect of sotalol would be detrimental in the context of overt fetal ventricular dysfunction). The dose of sotalol was increased after 48 hours if there was no or a minimal change in the frequency of SVT events. After initiation of sotalol (and after each dose adjustment), maternal ECGs were performed to assess the QTc intervals through the first 5 doses to exclude significant prolongation of maternal QTc. Serum electrolytes were monitored daily during the initiation and adjustment of sotalol, and potassium and magnesium supplementation were given orally as needed to maintain normal levels. Fetal echocardiography was repeated if a change occurred in the baseline rhythm. Routine biophysical profiles were not performed; however, obstetric ultrasound scans or echocardiograms were done daily or every other day for evaluation of effusions while the fetuses were in tachycardia.

The maternal medical records were reviewed to document the gestational age at the diagnosis of fetal SVT or AF, treatment course, time to response, and any other pertinent pregnancy history, including maternal side effects. The postnatal medical records of the infants were reviewed to assess for postnatal arrhythmias, to confirm the tachycardia mechanism, the treatment course, the response to treatment, and the presence or absence of structural heart disease. Fetal echocardiograms were retrospectively reviewed by 2 experienced fetal and pediatric cardiologists to evaluate the

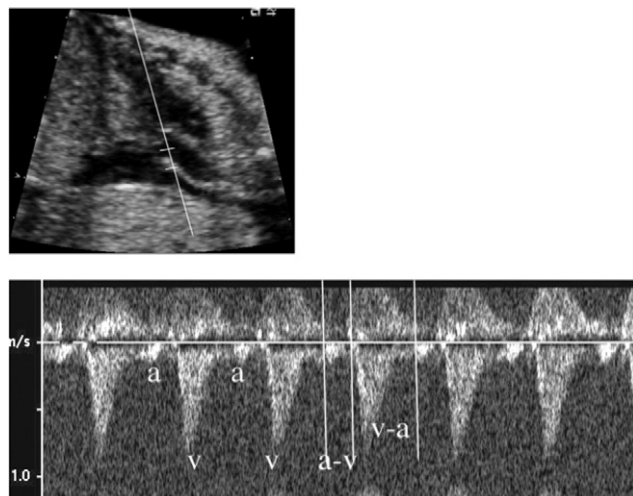


Figure 2. Spectral Doppler ultrasound through SVC and ascending aorta demonstrating long VA interval on fetal echocardiogram.

mechanism of the tachycardia, to assess for hydrops, and to evaluate for structural heart disease. SVT and AF were diagnosed using standard M-mode and Doppler techniques.⁸ The mechanism of SVT in the fetus was defined according to Doppler-derived atrial and ventricular flow onset intervals, as previously described by Fouron et al⁹ (Figure 2). Hydrops was defined as the presence of ≥ 2 of the following: ascites, pericardial effusion, pleural effusions, and skin edema. Pregnancies were defined as at risk of congestive heart failure using the observations of Naheed et al¹⁰ and included a diagnosis of SVT or AF that presented before 32 weeks gestation, incessant SVT ($>50\%$ of the examination), and the presence of structural heart disease.

An electrophysiologist reviewed all maternal ECGs performed before and after treatment onset, from which the

Table 1
Prenatal demographics (n = 21)

Demographics	Value
Gestational age at diagnosis (weeks)	
Mean	25
Range	17–35
Hydrops	8 (38%)
Type	
Atrial flutter	5 (24%)
Supraventricular tachycardia	16 (76%)
Short ventriculoatrial interval	2
Long ventriculoatrial interval	7
Equal intervals	4
Indeterminate intervals	3
Medication	
Sotalol alone	9 (43%)
Sotalol with digoxin	12 (57%)
Sotalol with other medication*	3 (14%)

* Sotalol and digoxin were discontinued and other antiarrhythmic agents were tried.

maternal heart rates and QTc intervals were recorded. Infant ECGs, Holter monitor reports, and electrophysiologic studies were also reviewed to confirm the mechanism of tachyarrhythmia and evaluate the response to treatment.

Descriptive statistics, including the mean, median, and range, are reported. The gestational age at diagnosis, tachycardia mechanism and rate, and the presence or absence of hydrops were compared among rapid responders, partial or slow responders, and nonresponders to sotalol.

Results

A total of 29 pregnancies presented to our fetal cardiovascular program from July 2004 to July 2008 with fetal tachycardia, none of which had received previous treatment. Of these 29, 21 were treated with sotalol as per the described protocol, and the remainder were either treated with digoxin alone or were managed expectantly owing to intermittent nature of the tachycardia or diagnosis near term. In 4 nonhydropic fetuses, sotalol and digoxin were used at onset of treatment at the discretion of the involved fetal cardiologist, thus not fully conforming to the outlined protocol. Of the 21 treated with sotalol or sotalol and digoxin together, the gestational age at diagnosis of the fetal tachycardia ranged from 17 to 35 weeks (median 25). The mechanisms of tachycardia among treated patients included AF in 5 and SVT in 16. Of those with SVT, most had documented long VA intervals (Table 1).

The maximum sotalol dose among the treated pregnant women ranged from 80 mg 2 times/day to 240 mg 3 times/day. Of those who received sotalol therapy, 12 also received digoxin, including 8 who presented with fetal hydrops. Of the 4 others who did not have hydrops, 2 were given an oral digoxin load and then maintenance digoxin dose was started 1 to 2 weeks after the onset of sotalol therapy for synergistic control of the tachycardia, because they had a good response to sotalol but still had brief, intermittent episodes of SVT. Two patients received an intravenous load (1 mg total in divided doses) followed by oral maintenance digoxin simultaneously with the sotalol, according to the referring cardiologist's preference, as did the 8 who presented with hydrops.

The patients were divided into rapid responders, partial responders, and nonresponders to sotalol therapy (Figure 3). All fetuses with AF were rapid responders; however, the other mechanisms of SVT were represented equally among the responders, partial responders, and nonresponders. One fetus was delivered emergently at 27 weeks for fetal "bradycardia" (average ventricular rate 70 beats/min) after the first dose of sotalol, although on retrospective review of the images, this likely represented blocked atrial extrasystoles. Of the 20 others, 11 had a rapid response, with 10 having full resolution of the tachycardia within 5 days of therapy (median 2), and 1 had significant rate slowing to within the normal sinus rhythm ranges. Six patients (including three with hydrops) were slower to respond or had only a partial response (less frequent SVT in 3 and partial or complete resolution of fluid collections in 3), with a median interval to response of 2 weeks after the onset of therapy. With a desire to completely control the SVT, 3 of these 6 slow/partial responders were given an additional medication (amiodarone in 2 and flecainide in 1), with subsequent conversion. In 1 other with a partial response, the mother chose pregnancy termination. Three grossly hydropic fetuses with SVT showed no response to the sotalol and digoxin combination and died within 1 to 3 days of the onset of treatment with these medications.

Eight treated fetuses had documented arrhythmias postnatally. Three of these infants were rapid responders in utero. The SVT mechanism was correctly predicted by the VA and AV interval assessment, with 1 infant with permanent junctional reciprocating tachycardia (long VA in utero), 1 with ectopic atrial tachycardia (long VA in utero), and 1 with AV node reentry tachycardia (short VA in utero). All 5 live-born fetuses with more difficult to treat SVT in utero (slow or partial responders) have had SVT that has been a challenge to treat after birth: 4 had AV reentry tachycardia (1 with Wolff-Parkinson-White syndrome and the others with concealed pathways), and 1 had permanent junctional reciprocating tachycardia. No fetus with AF had tachycardia postnatally.

Neonatal ECGs performed within the first 12 hours of delivery (for those delivered at our institution) demonstrated an average heart rate of 131 ± 13 beats/min (range 108 to 152, n = 11) and an average QTc among the treated infants of 435 ± 47 ms (range 380 to 550, n = 11) seen on the ECGs performed within 1 day of birth. The infant with a QTc of 550 ms was observed without sotalol and experienced normalization of the QTc within several days. None of the fetuses or neonates developed torsades during sotalol therapy.

The maternal symptoms during sotalol therapy included nausea, dizziness, and fatigue in 4 mothers who were concomitantly taking digoxin. Two of the 4 had the sotalol discontinued because of suboptimal control of fetal SVT and were administered other antiarrhythmic medications with no reported changes in maternal symptoms. The baseline QTc of the mothers before therapy was 418 ± 29 ms (range 360 to 460, n = 19). The average QTc interval with the maximum dose of sotalol was 425 ± 30 ms (range 370 to 480, n = 19). No mothers developed torsades during sotalol therapy. In no cases was sotalol discontinued because of maternal side effects.

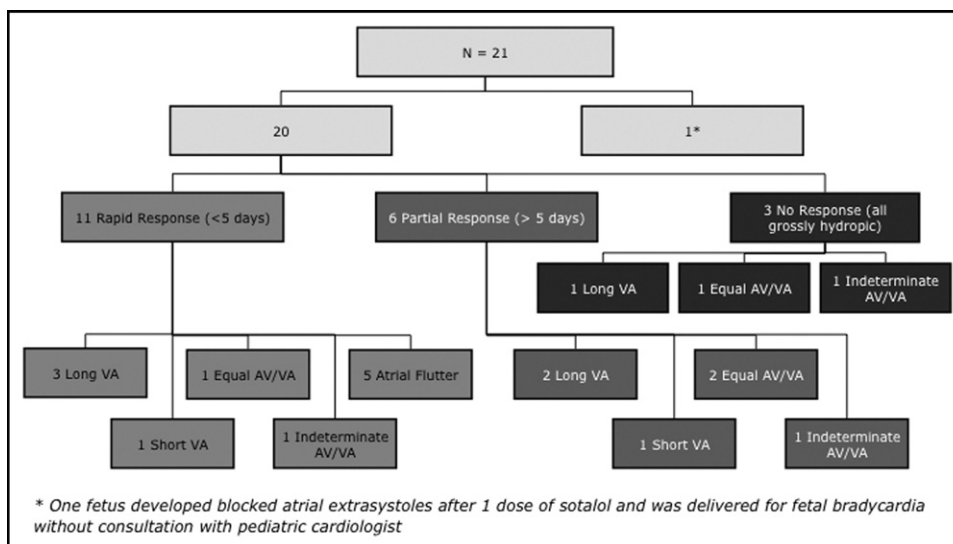


Figure 3. Response to treatment and type of fetal SVT.

Discussion

The present study has demonstrated rapid conversion and/or control of supraventricular tachyarrhythmias in the fetus using sotalol or sotalol combined with digoxin as first-line therapy. In our experience, 85% of treated fetuses demonstrated improvement or resolution of the tachyarrhythmias, with 5 of 8 hydropic fetuses demonstrating resolution of hydrops. Of the fetuses that showed no response to sotalol therapy, all were grossly hydropic at presentation. We also demonstrated a 100% rapid response rate in the subset of patients with AF. All our findings were comparable to the success reported in other much smaller cohorts of pregnancies treated with sotalol as first-line therapy^{5,11} and have demonstrated that sotalol or sotalol combined with digoxin is safe and effective first-line treatment of fetal SVTs.

Sotalol use has typically been indicated as a second-line agent in the treatment of long VA tachycardias^{5,7} and AF^{6,11,12} in utero. We documented the mechanism of tachycardia in most fetuses, and although we found it of interest to have a better sense of the mechanism of therapy, our treatment strategy and the clinical outcomes with sotalol therapy were not influenced by the knowledge of the mechanism. No previous report has documented the assessment of the SVT mechanism using Doppler-derived AV and VA intervals and their management outcomes outside of that reported by Fouron et al.⁷ In their cohort, the fetuses with AF and short VA tachycardias were treated with digoxin and those with long VA tachycardias with sotalol with an 89% conversion rate according to their respective therapies. In our group, all 5 fetuses with AF had a quick and complete response to sotalol. With respect to the other mechanisms of SVT, we did not observe a significant difference in the response to sotalol. We did observe that those fetuses who were more difficult to treat prenatally were also more difficult to treat postnatally with any antiarrhythmic therapy. The SVT mechanism in utero, although important for the postnatal prognosis, might, therefore, not be critical to medical management during pregnancy, because sotalol was effective in all groups.

Despite its common use in infants and children with SVT and AF, the reluctance to use this medication in pregnant women has largely stemmed from its additional class III effects, which result in its potential proarrhythmic effect associated with QT prolongation. However, in our experience and in the experience of other groups,⁵ QTc prolongation typically does not occur, even at very high doses in pregnant women. Given the potential risk, however, it remains advisable to be vigilant, not only in excluding maternal contraindications to sotalol treatment before initiation, but also in monitoring for electrocardiographic disturbances during loading and dose adjustments and avoiding the simultaneous use of QTc-prolonging agents, particularly certain antiemetics. We did document some lesser side effects (possibly associated with the β -blockade properties of sotalol) in some women, including lightheadedness and nausea, but none were so severe as to necessitate discontinuation of the drug.

With respect to the risks of sotalol to the fetus, although an initial report suggested a high fetal demise rate associated with sotalol use, most of these fetuses were grossly hydropic with demise with or without a response.² In a review of their large, single-center experience, Simpson and Sharland¹³ observed a 9% to 10% mortality of hydropic fetuses with SVT or atrial flutter, despite successful conversion with other antiarrhythmic medications, including digoxin, flecainide, verapamil, and amiodarone.¹³ One might conclude from these observations that the severity of fetal heart failure, rather than the medication, might be the most important culprit in their demise. However, given the lack of data regarding the effects of sotalol on fetal conduction (i.e., fetal magnetocardiography or electrocardiography, which might have contributed to the management of these fetuses) and potential myocardial depression from the drug, we could not completely exclude a direct role of sotalol in these fetal deaths.

Our observation that 5 hydropic fetuses experienced complete recovery after successful conversion provides strong support for achieving control of the tachyarrhythmia

among affected pregnancies as soon as possible to reverse or prevent hydrops in at-risk fetuses. A previous report cites a median response time of 14 days with digoxin therapy alone¹⁴; however, in our series, most fetuses had rapid conversion or rate control within 1 to 5 days of the onset of therapy with sotalol.

Our results have demonstrated that the efficacy of sotalol in treating fetal atrial arrhythmias is similar to, or better than that with, other drugs reported in published data but with advantages in administration and a better safety profile. Regarding the transplacental delivery of the drugs, the flecainide levels in fetal serum, even in the presence of hydrops, seem to be similar to maternal levels,¹⁵ and placental transfer of sotalol has also been shown to be excellent.^{5,16} Flecainide has been shown to be effective in controlling tachycardia and leading to the resolution of hydrops in this population, with conversion rates >80% reported in several small series either with flecainide as a first-line or second-line agent after digoxin therapy.^{14,15,17,18} The interval to conversion to sinus rhythm that we observed for sotalol is similar to that suggested in the published data for flecainide. Allan et al¹⁷ reported conversion by 48 hours after the initiation of flecainide in most patients (9 of 12); however, Krapp et al¹⁵ later demonstrated a 5-day mean (range 0 to 14) interval to conversion after flecainide was initiated in a group of 19 patients already being treated with digoxin. With respect to safety, sotalol requires only electrocardiographic monitoring for QT prolongation, and flecainide requires periodic serum levels to evaluate for potential toxicity in addition to serial ECGs. Conversion with amiodarone therapy (in addition to digoxin and in some cases as a third agent) has been reported to be similarly effective, with a mean of 6 days (range 2 to 21) in a study population, including both fetal atrial and ventricular tachycardias.¹⁹ It was very effective with SVT (converting 14 of 15) but was much less successful in atrial flutter (only 3 of 9). Amiodarone, however, has a very serious side-effect profile, including reports of biochemical fetal hypothyroidism in several of these fetuses in this series¹⁹ and cases of clinical hypothyroidism requiring postnatal thyroid replacement therapy in 3 other studies.^{20–22} Sotalol, therefore, is a much more desirable medication to treat fetal tachyarrhythmias than either flecainide or amiodarone.

Our retrospective review had several limitations. Sotalol did not immediately control tachycardia in all of our fetal patients and at least for the 3 partial responders requiring additional medications, one could argue these represented unsuccessful attempts at treatment with sotalol. The simultaneous initiation of sotalol and digoxin in the treatment of 4 patients without hydrops and 8 with hydrops made it difficult to be absolutely certain of the role of sotalol separate from digoxin in the SVT treatment of these patients. The present study was not a randomized trial of sotalol and digoxin, which would have demonstrated the different therapeutic profiles of the antiarrhythmics more effectively, and we did not routinely treat with any other antiarrhythmics (i.e., flecainide), limiting our ability to comment regarding the ideal first-line agent. Given the rarity of fetal SVT and AF, a randomized study comparing different antiarrhythmic agents would require a multicenter design but might be the

only manner in which to truly demonstrate the best method to treat these fetuses, especially the sickest ones.

1. Sonesson SE, Fouron JC, Wesslen-Eriksson E, Jaeggi E, Winberg P. Foetal supraventricular tachycardia treated with sotalol. *Acta Paediatr* 1998;87:584–587.
2. Oudijk MA, Michon MM, Kleinman CS, Kaputsa L, Stoutenbeek P, Visser GH, Meijboom EJ. Sotalol in the treatment of fetal dysrhythmias. *Circulation* 2000;101:2721–2726.
3. Oudijk MA, Ruskamp JM, Ambachtsheer BE, Ververs TF, Stoutenbeek P, Visser GH, Meijboom EJ. Drug treatment of fetal tachycardias. *Paediatr Drugs* 2002;4:49–63.
4. Merriman JB, Gonzalez JM, Rychik, Ural SH. Can digoxin and sotalol therapy for fetal supraventricular tachycardia and hydrops be successful? A case report. *J Reprod Med* 2008;53:357–359.
5. Oudijk MA, Ruskamp JM, Ververs FF, Ambachtsheer EB, Stoutenbeek P, Visser GH, Meijboom EJ. Treatment of fetal tachycardia with sotalol: transplacental pharmacokinetics and pharmacodynamics. *J Am Coll Cardiol* 2003;42:765–770.
6. Jaeggi E, Fouron JC, Drblik EJ. Fetal atrial flutter: diagnosis, clinical features, treatment, and outcome. *J Pediatr* 1998;132:335–339.
7. Fouron JC, Fournier A, Proulx F, Lamarche J, Bigras JL, Boutin C, Brassard M, Gamache S. Management of fetal tachyarrhythmia based on superior vena cava/aorta Doppler flow recordings. *Heart* 2003;89:1211–1216.
8. Hornberger LK. Echocardiographic assessment of fetal arrhythmias. *Heart* 2007;93:1331–1333.
9. Fouron JC, Proulx F, Miro J, Gosselin J. Doppler and M-mode ultrasonography to time fetal atrial and ventricular contractions. *Obstet Gynecol* 2000;96:732–736.
10. Naheed ZJ, Strassburger JF, Deal BJ, Benson DW, Gidding SS. Fetal tachycardia: mechanisms and predictors of hydrops fetalis. *J Am Coll Cardiol* 1996;27:1736–1740.
11. Lisowski LA, Verheijen PM, Benatar AA, Soyeur DJ, Stoutenbeek P, Brenner JI, Kleinman CS, Meijboom EJ. Atrial flutter in the perinatal age group: diagnosis, management and outcome. *J Am Coll Cardiol* 2000;35:771–777.
12. Krapp M, Kohl T, Simpson JM, Sharland GK, Katalinic A, Gembruch U, Baschat AA. Review of diagnosis, treatment, and outcome of fetal atrial flutter compared with supraventricular tachycardia. *Heart* 2003;89:913–917.
13. Simpson JM, Sharland GK. Fetal tachycardias: management and outcome of 127 consecutive cases. *Heart* 1998;79:576–581.
14. van Engelen AD, Weijts O, Brenner JI, Kleinman CS, Copel JA, Stoutenbeek P, Meijboom EJ. Management outcome and follow-up of fetal tachycardia. *J Am Coll Cardiol* 1994;24:1371–1375.
15. Krapp M, Baschat AA, Gembruch U, Geipel A, Germer U. Flecainide in the intrauterine treatment of fetal supraventricular tachycardia. *Ultrasound Obstet Gynecol* 2002;19:158–164.
16. Wagner X, Jougard J, Moulin M, Miller AM, Petitjean J, Pisapia A. Coadministration of flecainide acetate and sotalol during pregnancy: lack of teratogenic effects, passage across the placenta, and excretion in human breast milk. *Am Heart J* 1990;119:700–702.
17. Allan LD, Chita SK, Sharland GK, Maxwell D, Priestley K. Flecainide in the treatment of fetal tachycardias. *Br Heart J* 1991;65:46–48.
18. Ebenroth ES, Cordes TM, Darragh RK. Second-line treatment of fetal supraventricular tachycardia using flecainide acetate. *Pediatr Cardiol* 2001;22:483–487.
19. Strasburger JF, Cuneo BF, Michon MM, Gotteiner NL, Deal BJ, McGregor SN, Oudijk MA, Meijboom EJ, Feinkind L, Husey M, Parilla BV. Amiodarone therapy for drug-refractory fetal tachycardia. *Circulation* 2004;109:375–379.
20. Pézard PG, Boisson F, Sentilhes L, Lépinard C, Couvreur MH, Victor J, Geslin P, Descamps P. Fetal tachycardia: a role for amiodarone as first- or second-line therapy? *Arch Cardiovasc Dis* 2008;101:619–627.
21. Khositseth A, Ramin KD, O'Leary PW, Porter CJ. Role of amiodarone in the treatment of fetal supraventricular tachyarrhythmias and hydrops fetalis. *Pediatr Cardiol* 2003;24:454–456.
22. Jouannic JM, Delahaye S, Fermont L, Le Bidois J, Villian E, Dumez Y, Dommergues M. Fetal supraventricular tachycardia: a role for amiodarone as second-line therapy? *Prenat Diagn* 2003;23:152–156.