

UC Davis
Otolaryngology

Title

Treatment Outcomes with Conservative Management of Frontal Sinus Outflow Tract Fractures

Permalink

<https://escholarship.org/uc/item/08x9f4gv>

Authors

Cheema, Karmtej

Sarhadi, Kamron

Hwang, Joshua

et al.

Publication Date

2021

Data Availability

The data associated with this publication are not available for this reason: N/A



Treatment Outcomes with Conservative Management of Frontal Sinus Outflow Tract Fractures

Karmtej S Cheema, Kamron S Sarhadi, Joshua C Hwang, Steven Dennis, MD, Toby Steele, MD, E Brad Strong, MD

Department of Otolaryngology – Head and Neck Surgery, University of California, Davis



BACKGROUND

Frontal sinus fractures represent approximately 10-15% of maxillofacial fractures and are generally a result of high-speed motor vehicle accidents, assaults, or sporting injuries¹. Historic treatment options have included: observation, open reduction and internal fixation, obliteration, and cranialization². Frontal sinus fractures often occur with involvement of the frontal sinus outflow tract (FSOT) which has been treated aggressively to prevent complications including CSF leak, sinusitis, mucocele, meningitis, or brain abscess³. To avoid the possibility of these complications, immediate surgical treatment of FSOT fractures has been a standard practice. However, early surgical intervention has an intrinsic morbidity⁴, and through technologic and endoscopic advances, conservative management (i.e. observation) of FSOT fractures has become more common as well as a more viable option to treat the described long-term complications.

AIMS

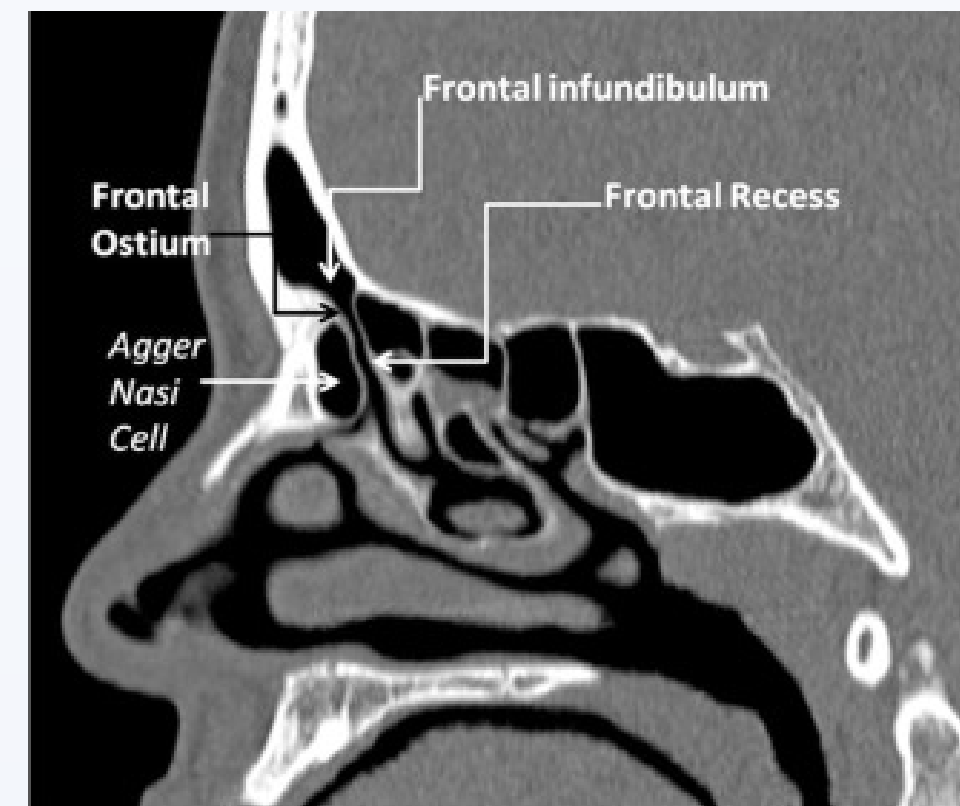
As conservative management of FSOT fractures becomes increasingly prevalent, there is minimal data regarding complication rates with observation. Via retrospective chart review, this study seeks to evaluate these risks to help clinicians in deciding if conservative management is right for their patient.

METHODS

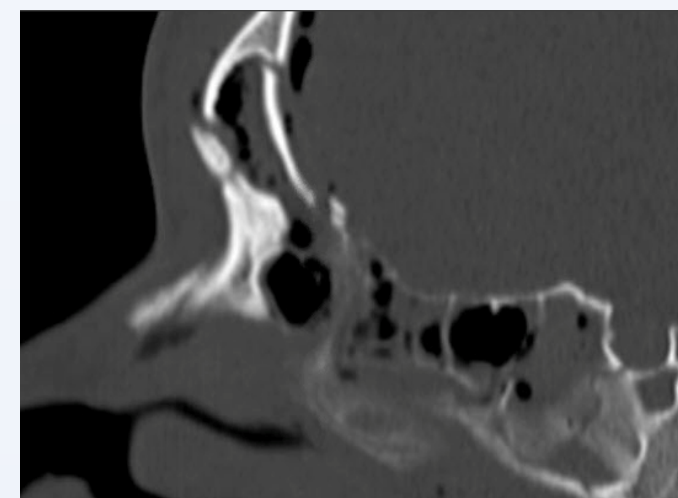
All FSOT injuries presenting to a tertiary care, level 1 trauma center between January 1, 2005, and May 1, 2019, were identified. Patient demographics, fracture patterns, surgical intervention, complications (major - CSF leak & mucocele; minor – sinusitis), and long-term sequelae were recorded. FSOT fractures were classified as either “disrupted” (bony violation of the FSOT with residual patent tract) or “obstructed” (bony obstruction of the FSOT). Patients with follow up imaging >90 days were included. Patients undergoing immediate surgical intervention were excluded.

RESULTS

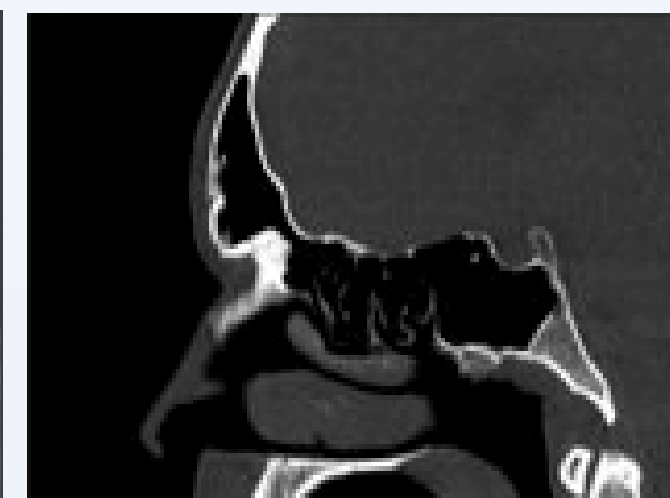
Normal Front Sinus Outflow Tract



FSOT Disruption



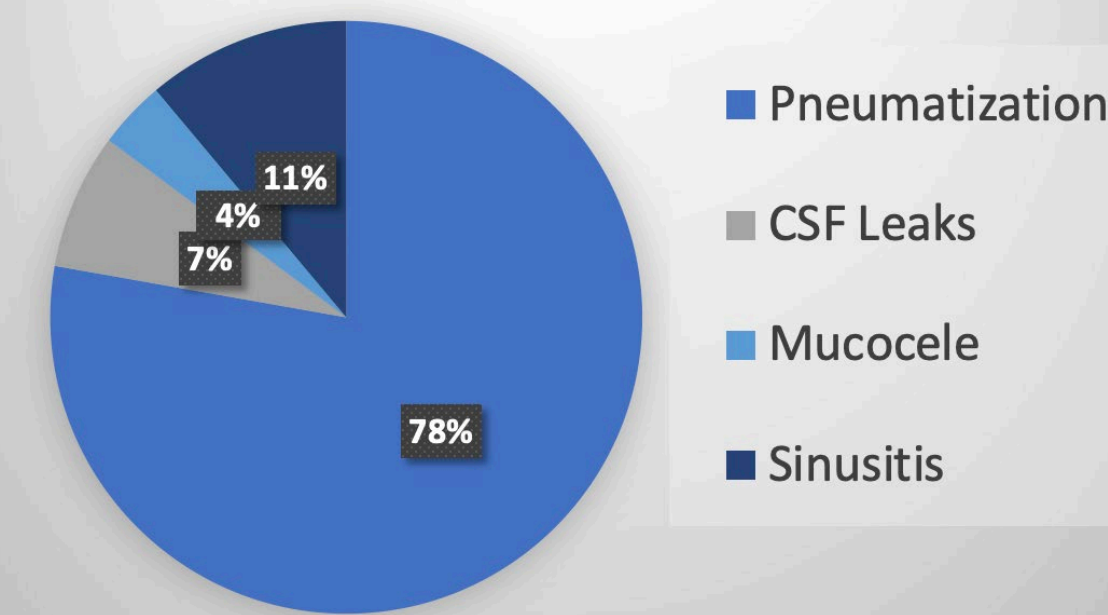
FSOT Pneumatization



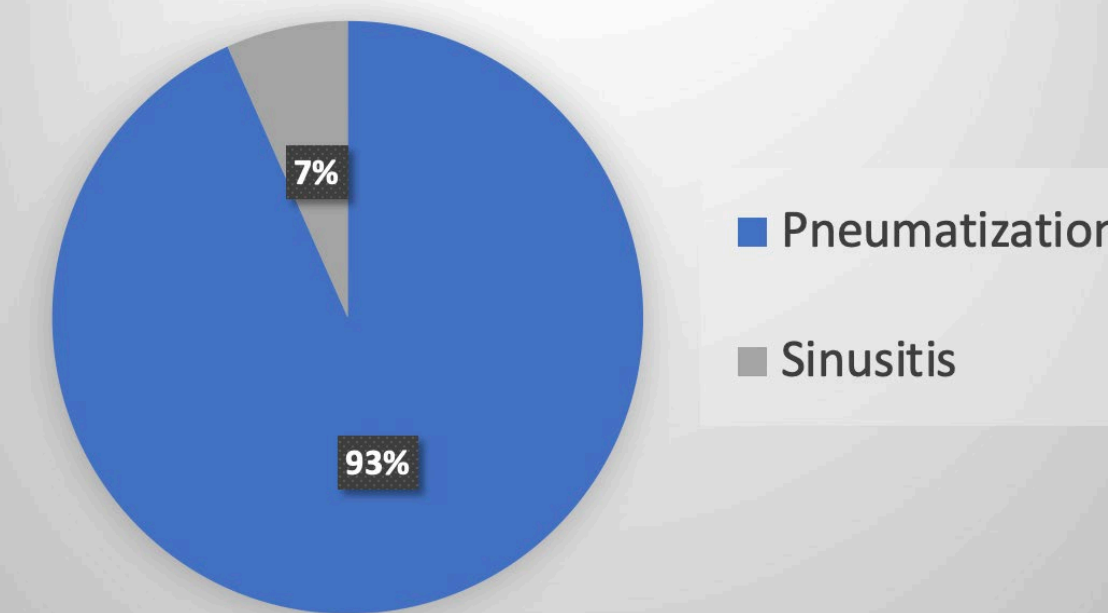
RESULTS

One hundred thirty-six patients with FSOT fractures were identified and 31 met criteria. Median follow up imaging was 426 days (range, 127-4387 days). Eight patients were found to have complications (26%) at 14.2 months median follow up. There were 3 major complications (2 delayed CSF leaks and 1 mucocele) (10%) and 5 minor complications (sinusitis) (16%). Delayed surgical intervention was required in 4 patients (13%) and there were no long-term sequelae in these 4 patients. When analyzed by type of injury, FSOT obstruction accounted for all major (11%) and 3 minor complications (11%); while FSOT disruption accounted for only 2 minor complications (7%).

FSOT Obstruction



FSOT Disruption



DISCUSSION

Of the 31 patients included in this study, 74% were found to have complete pneumatization of the FSOT with observation alone. No FSOT disruption and 13% of FSOT obstruction patients ultimately required surgical intervention. There were no long-term sequelae after surgery to address the complication. Given the limited sample size of this data, further data collection is necessary to determine the significance of these findings. However, this preliminary data trends towards higher complications in patients with complete obstruction of the FSOT. These findings suggest that conservative management is worth consideration, especially in FSOT disruption, and may spare patients from unnecessary interventions.

CONCLUSIONS

The results indicate observation is associated with a low risk of future complication and may reduce unnecessary surgical intervention, given reasonable assurance of long-term follow-up. Additionally, in the cases where observation eventually led to the need for delayed surgical intervention, complications were addressed without further long-term sequelae.

FUTURE DIRECTIONS

- Directly comparing rate of complication in patients managed conservatively vs. patients managed with immediate surgical intervention.
- Number needed to treat analysis of number of interventions needed to prevent 1 mucocele, 1 CSF leak, etc.
- Devising grading system for FSOT fractures that predicts likelihood of specific complications.

REFERENCES

1. Kim IA, Boahene KD, Byrne PJ. Trauma in Facial Plastic Surgery: Frontal Sinus Fractures. *Facial Plast Surg Clin North Am.* 2017 Nov;25(4):503-511. doi: 10.1016/j.fsc.2017.06.004. PMID: 28941504.
2. Emara TA, Elnashar IS, Omara TA, Basha WM, Anany AM. Frontal sinus fractures with suspected outflow tract obstruction: a new approach for sinus preservation. *J Craniomaxillofac Surg.* 2015 Jan;43(1):1-6. doi: 10.1016/j.jcms.2014.09.013. Epub 2014 Oct 29. PMID: 25458344.
3. Rodriguez ED, Stanwix MG, Nam AJ, St Hilaire H, Simmons OP, Christy MR, Grant MP, Manson PN. Twenty-six-year experience treating frontal sinus fractures: a novel algorithm based on anatomical fracture pattern and failure of conventional techniques. *Plast Reconstr Surg.* 2008 Dec;122(6):1850-1866. doi: 10.1097/PRS.0b013e31818d58ba. PMID: 19050539
4. Johnson NR, Roberts MJ. Frontal sinus fracture management: a systematic review and meta-analysis. *Int J Oral Maxillofac Surg.* 2021 Jan;50(1):75-82. doi: 10.1016/j.ijom.2020.06.004. Epub 2020 Aug 27. PMID: 32861554.

ACKNOWLEDGEMENTS

This project was supported by the University of California, Davis School of Medicine Medical Student Research Fellowship