

# UC San Diego

## UC San Diego Previously Published Works

### Title

Advanced magnetic resonance imaging of the osteochondral components in hemophilic joints reveals cartilage hemosiderin and correlations with clinical joint scores

### Permalink

<https://escholarship.org/uc/item/08p8459r>

### Authors

Lu, Xing  
Ma, Yajun  
Wong, Jonathan  
et al.

### Publication Date

2018

Peer reviewed

## ORIGINAL ARTICLE

# Magnetic resonance imaging and joint outcomes in boys with severe hemophilia A treated with tailored primary prophylaxis in Canada

J. KRAFT,\* V. BLANCHETTE,† P. BABYN,‡ B. FELDMAN,§ S. CLOUTIER,¶ S. ISRAELS,\*\* M. PAI,†† G.-E. RIVARD,‡‡ S. GOMER,§§ M. MCLIMONT,§§ R. MOINEDDIN\*\*\* and A. S. DORIA†††

\*Clarendon Wing Radiology Department, Leeds General Infirmary, Leeds, UK; †Division of Hematology/Oncology, Department of Pediatrics, The Hospital for Sick Children, Toronto; ‡Department of Medical Imaging, University of Saskatchewan and Saskatoon Health Region Royal University Hospital, Saskatoon; §Division of Rheumatology, The Hospital for Sick Children, Department of Pediatrics, Medicine, Health Policy Management and Evaluation, and The Dalla Lana School of Public Health, University of Toronto, Toronto; ¶Department of Hematology, L' Hôpital de l'Enfant-Jésus, Québec; \*\*Section of Pediatric, Hematology/Oncology, Department of Pediatrics and Child Health, University of Manitoba, Children's Hospital, Winnipeg, MB; ††Division of Pediatric Hematology/Oncology, McMaster University Health Sciences Centre/Niagara Regional Hemophilia Centre, Hamilton Health Sciences Corporation, Hamilton; ‡‡Division of Hematology-Oncology, CHU Sainte-Justine, Montreal; §§Child Health Evaluative Sciences Program, Research Institute, The Hospital for Sick Children, Toronto; \*\*\*Department of Family and Community Medicine, University of Toronto, Toronto; and †††Department of Diagnostic Imaging, The Hospital for Sick Children, Toronto, Canada

**To cite this article:** Kraft J, Blanchette V, Babyn P, Feldman B, Cloutier S, Israels S, Pai M, Rivard G-E, Gomer S, McLimont M, Moineddin R, Doria AS. Magnetic resonance imaging and joint outcomes in boys with severe hemophilia A treated with tailored primary prophylaxis in Canada. *J Thromb Haemost* 2012; **10**: 2494–502.

**Summary.** *Background/objectives:* Tailored primary prophylaxis (TPP) is a reduced-intensity treatment program for hemophiliacs with the goal of preventing arthropathy. Our primary aim was to evaluate the joint outcomes of treated subjects using magnetic resonance imaging (MRI) and physical examination as outcome measures. *Methods:* Ankles, elbows and knees (index joints) of 24 subjects (median [range] age at start of therapy, 1.6 [1–2.5] years) with severe hemophilia A enrolled in the Canadian Hemophilia Primary Prophylaxis Study (CHPS) were examined by MRI at a median age of 8.8 years (range 6.2–11.5 years). Subjects were treated with TPP using a recombinant factor VIII concentrate, starting once weekly and escalating in frequency and dose according to frequency of bleeding. *Results:* Osteochondral changes (cartilage loss/subchondral bone damage) were detected in 9% (13/140) of the index joints and 50% (12/24) of study subjects. Osteochondral changes were restricted to joints with a history of clinically reported joint bleeding. Soft tissue changes were detected in 31% (20/65) of index joints with no history of clinically reported bleeding (ankles 75% (12/16); elbows 19% (6/32); and knees 12% (2/17)). In these apparently 'bleed free' index joints hemosiderin deposition was detected by MRI in

26% (17/65) of joints (ankles 63% (10/16); elbows 16% (5/32), and knees 12% (2/17)). *Conclusion:* TPP did not completely avoid the development of MRI-detected structural joint changes in hemophilic boys in this prospective study. A longer period of follow-up is required for assessment of the longitudinal course of these early changes in hemophilic arthropathy, detected using a sensitive imaging technique (MRI).

**Keywords:** arthropathy, children, hemophilia, magnetic resonance imaging, prophylaxis.

## Introduction

Hemophilic arthropathy is caused by recurrent bleeding into joints leading to synovial hypertrophy, hemosiderin deposition, cartilage destruction and changes in the subchondral bone. As a result, the joint becomes painful, with loss of function and the potential for significant disability [1]. Primary prophylaxis, the preventive administration of the deficient clotting factor on a regular basis before the onset of joint damage, is aimed at reducing or eliminating hemarthrosis and thus joint damage in patients with hemophilia [2]. However, primary prophylaxis is expensive and, in order to ensure reliable venous access, may require the placement of a central venous access device in very young boys with severe hemophilia. The longer primary prophylaxis is postponed after the first joint bleed, the higher is the risk of developing arthropathy [3].

Tailored ('dose escalation') primary prophylaxis is a regimen in which young boys with severe hemophilia A initially receive weekly factor VIII (FVII) infusions (dose, 50 IU kg<sup>-1</sup>), with an

Correspondence: Andrea S. Doria, Department of Diagnostic Imaging, The Hospital for Sick Children, 555 University Ave, Toronto ON, M5G 1X8, Canada.

Tel.: +1 416 813 6079; fax: +1 416 813 7591.

E-mail: andrea.doria@sickkids.ca

Received 16 April 2012, accepted 1 October 2012

increase in infusion frequency (dose escalation) based on clinically significant breakthrough bleeding into joints [4]. This management approach is less expensive than 'full-dose' primary prophylaxis, a program that involves the infusion of FVIII concentrate on alternate days (24–40 IU kg<sup>-1</sup> per infusion), which was reported in the early 1990s to prevent the development of clinically significant arthropathy, as evidenced by plain radiography of joints [5,6]. Recently, Manco-Johnson *et al.* [7] published the results of a randomized clinical trial demonstrating that 'full-dose' primary prophylaxis (starting at 25 IU kg<sup>-1</sup> of FVIII every other day with the potential to increase the dose infused based on breakthrough bleeding) before the age of two and a half years in boys with severe hemophilia A, can prevent, in most cases, joint damage as defined by the absence of osteochondral changes seen on magnetic resonance imaging (MRI) of joints at the age of 6 years.

Evaluation of outcomes in patients on prophylaxis is essential for determination of its effectiveness. MRI is an optimal tool for assessment of musculoskeletal outcomes in boys with hemophilia treated with prophylaxis, because of its capacity to detect early soft tissue and osteochondral abnormalities in joints into which bleeding has occurred [8–10]. The purpose of this study was to evaluate the outcomes for joints of young boys with severe hemophilia A receiving tailored primary prophylaxis using MRI as an outcome measure.

## Materials and methods

### Study design

The study protocol was approved by the Research Ethics Boards of the participating institutions. Written informed consent was obtained from all parents and/or patients who participated in the study. The multicenter Canadian Hemophilia Primary Prophylaxis Study (CHPS) prospectively enrolled patients from July 1997 until January 2007 [4]. This communication reports the results of a sub-study that evaluated the first 25 subjects enrolled in the study (between July 1997 and March 2001).

### Patients

Twenty-five boys were enrolled in the MRI sub-study. One of the patients withdrew from the CHPS study and was therefore excluded. The 24 included subjects with severe hemophilia A were from 10 Canadian pediatric hemophilia treatment centers (Hamilton (five), Montreal (four), Toronto (four), Winnipeg (three), Calgary (two), Quebec City (two), Halifax (one), Ottawa (one), Thunder Bay (one), Vancouver (one)). To be eligible for enrollment in the study, boys were required to have normal index joints (ankles, knees and elbows), as defined by the modified World Federation of Hemophilia Orthopaedic joint score [11], and radiologic (Pettersson) scores at study entry [12].

Exclusion criteria for the CHPS study included a history of three or more clinically determined bleeds into any index joint (ankle, knee or elbow), present or past history of a circulating inhibitor to FVIII (level  $\geq$  0.6 Bethesda Units) and competing risk factors (symptomatic HIV infection, juvenile inflammatory arthritis, metabolic bone disease or other disease that may mimic arthropathy).

### Tailored Primary Prophylaxis protocol

A three-step tailored escalating dose/frequency protocol was used.

Step 1: prophylaxis with a full-length recombinant factor VIII (rFVIII) at a dose of 50 International Units (IU) kg<sup>-1</sup> body weight given once weekly.

Step 2: 30 IU rFVIII kg<sup>-1</sup> body weight given twice weekly if the subject experienced three or more bleeds into a single index joint in a consecutive 3-month period; or  $\geq$  four clinically determined bleeds (either significant soft tissue bleeds or joint bleeds into any number of index joints) over a consecutive 3-month period; or  $\geq$  five clinically determined bleeds into any index joint while on the same dosage (step) over any period of time. A significant soft tissue hemorrhage was defined as a muscle bleed associated with functional impairment (e.g. a calf bleed with an associated limp) [13].

Step 3: 25 IU rFVIII kg<sup>-1</sup> body weight given on alternate days if any of the escalation criteria recurred (see Step 2). Further incremental increases in dose (at 5 IU rFVIII kg<sup>-1</sup> body weight) were allowed if bleeding continued.

### Outcome measures

The primary outcome measure of this study was evidence of changes in index joint structure, as determined by the presence of osteochondral changes (subchondral cysts, surface erosions or cartilage loss) on MRI. The compatible MRI scoring system [14,15] that was used for evaluation of hemophilic arthropathy in this study includes one additive (A-) component (maximum score, 20) and one progressive (P-) component (maximum score, 10) for each index joint. An osteochondral abnormality was defined as an MRI score of at least 7, according to the P- MRI score, or at least 1 according to the osteochondral component of the A- MRI score.

Secondary outcomes included evidence of prior index-joint bleeds ( hemosiderin deposition) on MRI and orthopedic joint scores determined by physical examination [16]. MRI-based evidence of hemosiderin deposition was defined as an MRI score of at least 4 (P- MRI score) or of 1 (A- MRI score). The P- MRI score follows the concept of the Denver MRI scale [17], which considers different levels of severity for different components of the soft tissue domain. According to the P- MRI score the effusion/hemarthrosis item should receive a score of 0 if not present and a score ranging from 1 to 3 (according to amount of fluid seen) if present. Conversely, the synovial hypertrophy and hemosiderin deposition items should receive scores of 0 if not present and scores ranging from 4 to 6

(according to amount of synovium or hemosiderin seen, respectively) if present. Therefore, the synovial hypertrophy and hemosiderin deposition items receive larger weights than the effusion/hemarthrosis item at comparative scale levels. Conversely, according to the A- MRI score the synovial hypertrophy item should receive a score of 0 if not present and scores ranging from 1 to 3 (according to amount of synovium seen) if present. Conversely, the hemosiderin deposition item should receive a score of 0 if not present and a score of 1 if present (regardless of the amount of hemosiderin seen). No joint effusion/hemarthrosis item exists in the soft tissue domain of the compatible A- MRI scale.

Presence of joint change on physical examination was determined by orthopedic joint scores of at least 1 according to a modified version of the Colorado Child Physical Examination instrument [16], consisting of 10 items (maximum score of 24 for each elbow and 28 for each ankle and knee); total score ranges from 0 (normal) to 160 (most severe damage).

#### *MR imaging acquisition and interpretation*

The study protocol was performed on 1.5 T MRI scanners in all centers and included preferentially, but not exclusively if other sequences were required for clinical purposes, T2\* gradient echo images (TR, 600 ms; TE, 20 ms; flip angle, 20°; bandwidth, 15.63; matrix, 256 × 192; NEX, 2; average field-of-view, 12 cm (to be adjusted according to the patient's joint size; slice thickness, 4 mm; gap, 0 mm)) in coronal and sagittal planes for ankles and knees, and axial, sagittal and coronal planes for elbows. Total time for scanning the six index joints using the suggested gradient echo protocol was approximately 50 min. No contrast material was used, except for one patient who had intravenous administration of gadolinium for clinical indication. Elbows were imaged separately with surface coils; both knees and both ankles were imaged simultaneously with extremity or head coils, respectively, according to joint size. The images from all centers were collected and stored in the Picture Archiving and Communication System (PACS) Unit at one of the centers (Toronto).

#### *MR imaging interpretation*

All MRI examinations of this study were considered as presenting with acceptable quality for interpretation. They were independently evaluated by two pediatric radiologists (PB and JK), blinded to all clinical information. Discrepant readings were adjudicated by a third pediatric radiologist (ASD). The third reader independently scored the MRI examinations in which discrepant sub-scores were noted between the two pediatric radiologists, blinded to the results of previous sub-scores. The final sub-scores for discrepant cases represented the agreement of two out of three readers. If no agreement on a given sub-score was reached between the three readers, the third reader (adjudicator) made a decision on the final score, not

blinded to the results of that particular sub-score that were provided by the other two readers.

#### *Physical examination*

In each center, patients were examined by a physical therapist every 3 months during the first 5 years of study and every 6 months thereafter. The physical therapists received standardized training prior to the commencement of the study.

#### *Clinical information*

Descriptive clinical information included the number and location of index joint hemorrhages, before entry into the study and up to the time of the MRI examination, age at study entry, the number of days on study, and age at time of MRI study.

#### *Statistical analysis*

The lifetime frequency of clinically evident index joint bleeds prior to the MRI examination (0 or ≥ 1) and clinical and MRI parameters were compared using the chi-square test. The association between the number of prior lifetime index joint bleeds and clinical information (age at time of MRI, age at start of prophylaxis, physical examination joint scores) was investigated with Spearman correlation coefficients ( $r_s$ ). The inter-reader reliability of interpretation of the Compatible MRI scale in this study was tested using intraclass correlation coefficients (ICC) [17,18]. ICC and  $r \leq 0.40$  indicated poor,  $> 0.40$  and  $\leq 0.60$  moderate,  $> 0.60$  and  $\leq 0.80$  substantial and  $> 0.80$  excellent agreement/correlation [18,19]. All comparisons were two sided and  $P$  values  $\leq 0.05$  were considered statistically significant. SAS version 9.2 (SAS Institute, Cary, NC, USA) was used for the analysis and data manipulation.

## **Results**

Twenty-four boys underwent MRI examinations of index joints: 23 of elbows, knees and ankles and one of ankles only as he was unable to cooperate for completion of the MRI. The median age of subjects at the time of the MRI examination was 8.8 years (range 6.2–11.5 years). The median age of boys at study entry was 1.6 years (range 1–2.5 years), corresponding to a median duration on study of 7.1 years (range 5–9 years) before the MRI study was performed. At the time of the MRI study, 25% of boys (6/24) were on once weekly prophylaxis (Step 1: 50 IU kg<sup>-1</sup> once weekly), 37.5% (9/24) on twice weekly prophylaxis (Step 2: 30 IU kg<sup>-1</sup> twice weekly) and 37.5% (9/24) on 'full-dose' (alternate day) prophylaxis (Step 3: 25 IU kg<sup>-1</sup> every other day). The median interval of time between the MRI study and joint assessments by physical examination was 2 months (range 0–4 months) for the study cohort. Clinical characteristics of study subjects, including numbers of index joints with and without a history of clinically evident bleeding before the MRI study, are presented in Table 1.

**Table 1** Demographic and clinical characteristics of study subjects ( $n = 24$ )

	Lifetime number of joint bleeds at time of MRI study			
	0		$\geq 1$	
	Per joint (%)	Overall (all joints) (%)	Per joint (%)	Overall (all joints) (%)
Number of cases/total number joints evaluated	65/140 (46)		75/140 (54)	
Ankles	16/48 (33)		32/48 (67)	
Knees	17/46 (37)		29/46 (63)	
Elbows	32/46 (70)		14/46 (30)	
Lifetime number of joint bleeds at time of MRI study				
Median (range)	0 (0)		2 (1–42)	
Ankles	0 (0)		3 (1–26)	
Knees	0 (0)		2 (1–7)	
Elbows	0 (0)		3 (1–42)	
Orthopedic joint scores				
Median (range) (1–160)	0 (0–9)		1 (0–10)	
Ankles	1 (0–9)		1 (1–8)	
Knees	0 (0–1)		0 (0–2)	
Elbows	0 (0–1)		0 (0–10)	

Twelve (50%) of the 24 subjects on the dose escalation prophylaxis regimen, one (8%) receiving once weekly prophylaxis (Step 1), five (42%) receiving twice weekly prophylaxis (Step 2) and six (50%) receiving full-dose alternate day prophylaxis, had detectable osteochondral changes in index joints at the time of the MRI examination (Table 2). Out of the 24 study subjects, osteochondral changes were detected by MRI in the ankles of eight (33%) patients and in the elbows of five (21%) patients, but not in the knees of any patients.

Of the 140 index joints examined by MRI, 65 (46%) had a negative clinical history of bleeding into the joints before the MRI study (Table 3). None of these joints had evidence of osteochondral joint damage on MRI examination. Of the 75 (54%) index joints with a life-time history of any

bleeding before the MRI study, 13 (17%) had evidence of osteochondral changes on MRI; cartilage loss was detected in 11 of the 75 joints (15%) and subchondral bone changes in seven (9%) (Table 4). Details of the osteochondral changes, identified with either the Progressive (P) or the Additive (A) MRI scale, are provided in Table 2. Osteochondral damage detected on MRI by the Progressive Score correlated only moderately with the lifetime number of hemarthroses in ankles ( $r = 0.4$ ,  $P = 0.006$ ) and elbows ( $r = 0.63$ ,  $P = 0.0001$ ).

Soft tissue changes involving ankles ( $n = 22$ ; Fig. 1), elbows ( $n = 10$ ; Fig. 2) and knees ( $n = 3$ ; Fig. 3) were detected by MRI in 22 of 24 (92%) subjects. Details of soft tissue changes are presented in Tables 3 and 4. The frequency of soft tissue changes was 47% (35/75) of index joints with a lifetime history of any bleeding before the MRI study (Table 4). Specific changes included hemosiderin deposition in 40% (30/75), synovial hypertrophy in 37% (28/75) and joint effusion/hemarthrosis in 19% (14/75) of joints. Of interest, and not anticipated, soft tissue changes were detected in 31% (20/65) of joints without any lifetime history of bleeding before the MRI examination (Table 3). Specific changes included hemosiderin deposition in 26% (17/65), synovial hypertrophy in 25% (16/65) and joint effusion/hemarthrosis in 12% (8/65) of joints. Soft tissue abnormalities observed on MRI examination (as per the Progressive Score) correlated moderately with the number of hemarthroses in elbows ( $r = 0.59$ ,  $P = 0.001$ ), but poorly with the number of hemarthroses in knees ( $r = 0.19$ ,  $P = 0.21$ ) and ankles ( $r = 0.19$ ,  $P = 0.21$ ). Figure 4 illustrates that some joints with no lifetime history of bleeding had high soft tissue scores on MRI examination; however, none of these joints had osteochondral changes detected by MRI (Table 3).

Orthopedic joint scores assessed per protocol (every 3 months during the first 5 years of the study and every 6 months thereafter) showed little evidence of joint damage in the study cohort at the time of the MRI examinations. The

**Table 2** Frequency of osteochondral changes detected by MRI in the study cohort. Only sub-items of the MRI scoring system that were reported as presenting with abnormalities are described below. Osteochondral changes:  $n = 12/24$  (50%). Surface erosions:  $n = 5/24$  (21%). Subchondral cysts:  $n = 7/24$  (29%). Cartilage loss:  $n = 11/24$  (46%)

Types of changes		Number of affected patients ( $n = 24$ )*	Number of affected joints		
Item	Sub-item		Elbows ( $n = 46$ ) <sup>†</sup>	Ankles ( $n = 48$ ) <sup>†</sup>	Knees ( $n = 46$ ) <sup>†</sup>
Subchondral bone or joint margins (%)	Any surface erosion	3 (13)	1 (2)	2 (4)	0
	Any surface erosion in at least two bones	2 (8)	1 (2)	1 (2)	0
	At least one subchondral cyst	4 (17)	1 (2)	3 (6)	0
	More than one subchondral cyst	2 (8)	1 (2)	1 (2)	0
	Subchondral cysts in at least two bones	1 (4)	1 (2)	0	0
Cartilage loss (%)	Any loss of cartilage height	5 (21)	3 (7)	2 (4)	0
	Any loss of cartilage height in at least two bones	5 (21)	1 (2)	4 (8)	0
	Any loss of cartilage height involving more than one-third of the joint surface in at least two bones	1 (4)	0	1 (2)	0

\*Number of boys studied. <sup>†</sup>Number of joints studied.

**Table 3** Soft tissue and osteochondral changes in index joints with no history of any clinically evident bleeds before the MRI study

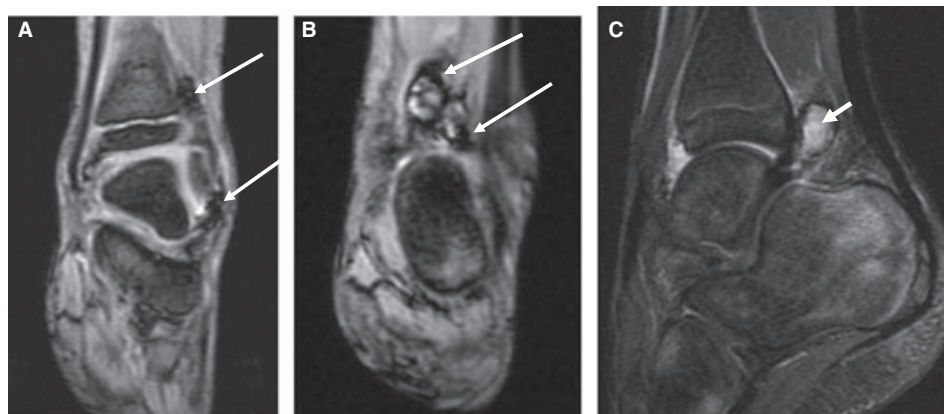
	Ankles ( <i>n</i> = 16)	Elbows ( <i>n</i> = 32)	Knees ( <i>n</i> = 17)	All index joints ( <i>n</i> = 65)
Soft tissue changes (%)	12/16 (75)	6/32 (19)	2/17 (12)	20/65 (31)
Median (range) score P scale	4 (1–5)	4 (4–4)	4 (4–4)	4 (1–5)
Median (range) score A scale	2 (0–3)	2 (1–2)	2 (2–2)	2 (0–3)
Hemosiderin (%)	10/16 (63)	5/32 (16)	2/17 (12)	17/65 (26)
Median (range) score P scale	4 (4–5)	4 (4–4)	4 (4–4)	4 (4–5)
Median (range) score A scale	1 (1–1)	1 (1–1)	1 (1–1)	1 (1–1)
Synovial hypertrophy (%)	10/16 (63)	4/32 (13)	2/17 (12)	16/65 (25)
Median (range) score P scale	4 (4–5)	4 (4–4)	4 (4–4)	4 (4–5)
Median (range) score A scale	1 (1–2)	1 (1–1)	1 (1–1)	1 (1–2)
Joint effusion/hemarthrosis (%)	7/16 (44)	1/32 (3)	0/17 (0)	8/65 (12)
Median (range) score A scale	1 (1–2)	1 (1–1)	0 (0–0)	1 (1–2)
Osteochondral joint change (%)	0/16 (0)	0/32 (0)	0/17 (0)	0/65 (0)
Median (range) score P scale	0 (0–0)	0 (0–0)	0 (0–0)	0 (0–0)
Median (range) score A scale	0 (0–0)	0 (0–0)	0 (0–0)	0 (0–0)

*n*, number of index joints.

**Table 4.** Soft tissue and osteochondral changes in index joints with a lifetime history of one or more bleeds at the time of the study

	Ankles ( <i>n</i> = 32)	Elbows ( <i>n</i> = 14)	Knees ( <i>n</i> = 29)	All index joints ( <i>n</i> = 75)
Soft tissue changes (%)	24/32 (75)	7/14 (50)	4/29 (14)	35/75 (47)
Median (range) score P scale	4 (1–6)	5 (1–6)	2 (0–4)	4 (1–6)
Median (range) score A scale	2 (0–4)	3 (0–4)	1 (0–1)	2 (0–4)
Hemosiderin (%)	23/32 (72)	5/14 (36)	2/29 (7)	30/75 (40)
Median (range) score P scale	4 (4–6)	5 (4–6)	4 (4–4)	4 (4–6)
Median (range) score A scale	1 (1–1)	1 (1–1)	1 (1–1)	1 (1–1)
Synovial hypertrophy (%)	23/32 (72)	5/14 (36)	0/29 (0)	28/75 (37)
Median (range) score P scale	4 (4–6)	5 (4–6)	0 (0–0)	4 (4–6)
Median (range) score A scale	1 (1–3)	2 (1–3)	0 (0–0)	1 (1–3)
Joint effusion/hemarthrosis (%)	6/32 (19)	6/14 (43)	2/29 (7)	14/75 (19)
Osteochondral joint changes (%)	8/32 (25)	5/14 (36)	0/29 (0)	13/75 (17)
Median (range) score P scale	9 (7–10)	8.5 (7–9)	0 (0–0)	9 (7–10)
Median (range) score A scale	2 (1–4)	1.5 (1–5)	0 (0–0)	2 (1–5)

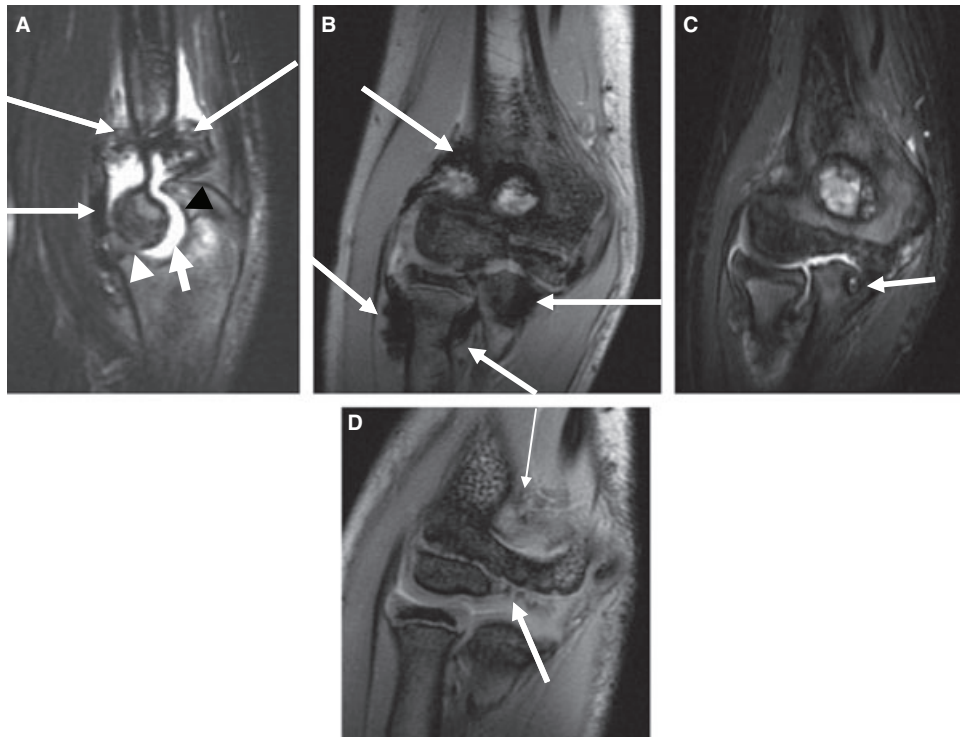
*n*, number of index joints.



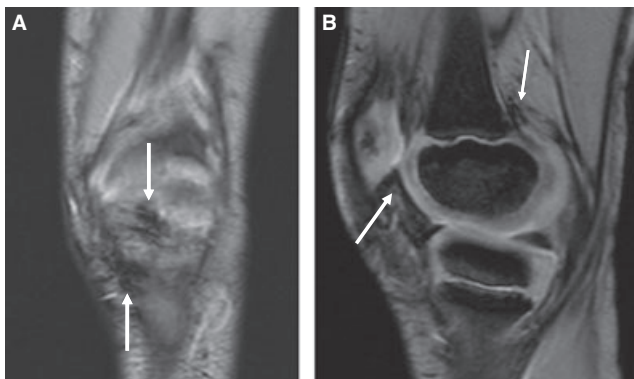
**Fig. 1.** Ten-year-old boy with severe hemophilia A and no history of previous bleeds into the left ankle. MRI images of the patient's left ankle show moderate synovial proliferation (score 2, A-scale; score 5, P-scale), hemosiderin deposition (score 1, A-scale; score 5, P-scale) (long arrows; A, B) and joint effusion (short arrow; C). No obvious osteochondral abnormalities were identified.

median orthopedic joint score for the 24 study subjects, based on the physical examination nearest to the MRI study, was 0 out of a possible score of 160 (range, 0–10). Joint scores in ankles, knees and elbows in subjects with and without a lifetime

history of clinically evident bleeds were overall very low (Table 1). Boys with abnormal soft tissue scores on MRI had higher physical examination joint scores as compared with boys with normal MRI scores. Joint scores demonstrated



**Fig. 2.** Ten-year-old boy with severe hemophilia A, seven reported intra-right elbow joint bleeds (A–C) and no history of previous bleeds into the left elbow (D–F). Sagittal (A) and coronal (B) MR images of the patient's right elbow show marked synovial hypertrophy (score 3, A-scale; score 6, P-scale) and hemosiderin deposition (score 1, A-scale; score 6, P-scale) around the joint (long arrows). Also noted in this joint are a small joint effusion (score 1, P-scale) (A) (short arrow), a subchondral cyst seen in the coronoid process of the proximal ulna on coronal T2-weighted (C) image (arrow) (score 1, A-scale; score 7, P-scale), and cartilage loss at the coronoid process of the proximal ulna (A) (arrowhead) (score 2, A-scale; score 9, P-scale). In the patient's left elbow, minimal hemosiderin deposition is noted on the coronal MR (D) image (arrows); however, no other soft tissue or osteochondral abnormalities are identified.



**Fig. 3.** Six-year-old boy with severe hemophilia A and no history of prior intra-articular bleeds. Coronal (A) and sagittal (B) multiphase gradient-echo images show mild hemosiderin deposition in the left knee (score 1, A-scale; score 4, P-scale) (arrows). Otherwise, no significant findings were identified.

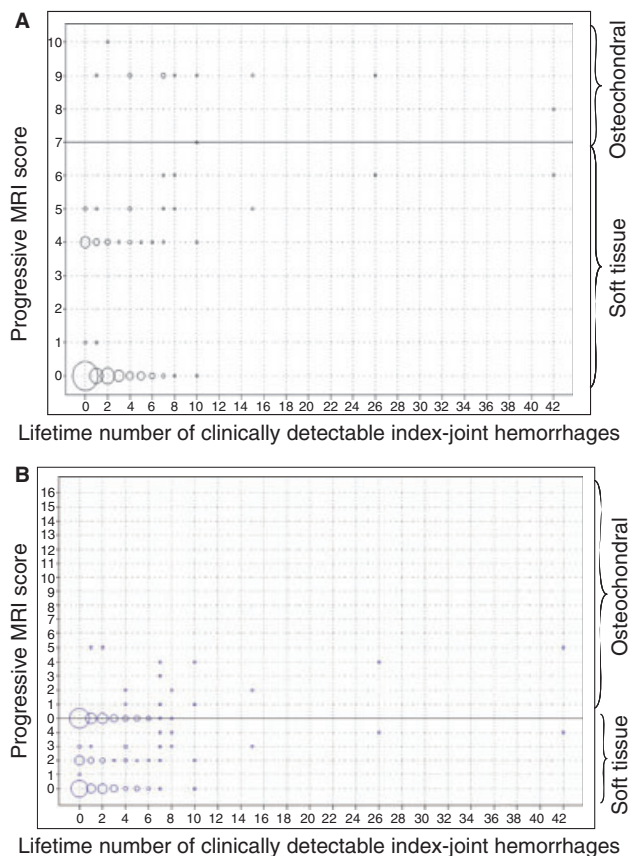
positive and moderate correlations with the two MRI scales in examinations of the elbows (soft tissue scores,  $r = 0.6/r = 0.75$ ,  $P = 0.001$ , P-/A- scores; osteochondral scores,  $r = 0.58/r = 0.58$ ,  $P < 0.0001$ , P-/A- scores), and borderline positive and weak correlations with soft tissue MRI scores of the two scales in ankle examinations only ( $r = 0.28/r = 0.28$ ,  $P = 0.05$ , P-/A- scores).

#### Reliability of interpretation of MRI scores

The overall inter-reader reliability of the compatible MRI scale was excellent for ankles (ICC for P-score, 0.81 (95% CI, 0.69–0.89); ICC for A-score, 0.84 (95% CI 0.73–0.91)) and elbows (ICC for P-score, 0.89 (95% CI, 0.81–0.94); ICC for A-score, 0.92 (95% CI 0.86–0.95)), but was poor for knees (for P- and A- scores).

#### Discussion

The use of MRI in this study enabled us to differentiate osteochondral and soft tissue changes: within the soft tissue domain to discriminate between hemosiderin deposition, synovial hypertrophy and hemarthrosis/joint effusion, and within the osteochondral domain to evaluate the severity of cartilage loss and bony changes. In our cohort of 24 boys, soft tissue changes (joint effusion/hemarthrosis, synovial hypertrophy and hemosiderin deposition) were detected in 92% of subjects and 39% of joints. Soft tissue changes were detected by MRI in index joints with and without a history of clinical bleeding. Of note, synovial hypertrophy was detected in 63% of ankles, 13% of elbows and 12% of knees without a history of prior life-time joint bleeding (Table 3). Comparable findings for hemosiderin deposition were 63% of ankles, 16% of elbows



**Fig. 4.** MRI scores for index joints according to the lifetime number of hemorrhages in that joint. The y-axes of A and B show the progressive and additive MRI scores, respectively, and the x-axes, the number of lifetime bleeds in joints. In A, a score of 0 indicates a normal joint and scores of 7–10 osteochondral changes. In B a score of 0 indicates a normal joint, scores of 1–4 (lower aspect of the graph) indicate soft tissue changes and scores of 1–16 (upper aspect of the graph) indicate osteochondral changes. The size of each circle corresponds to the number of cases. The larger bubbles represent more than one joint. A (progressive score) shows 28 joints with soft tissue changes and 13 joints with osteochondral changes. B (additive score) shows 45 joints with soft tissue changes and 13 joints with osteochondral changes. Some joints with no clinically reported hemarthroses had high soft tissue scores (progressive (A) and additive score (B)), but none of these cases demonstrated osteochondral abnormalities on MRI. On the other hand, some cases had normal MRI scores despite many hemarthroses.

and 12% of knees. Our findings, especially hemosiderin deposition, confirm the important finding of subclinical joint bleeding reported by Manco-Johnson *et al.* [7] and offer an explanation for the weaker than anticipated correlation between clinically recorded index joint hemorrhages and MRI findings. Note is made, however, that in cases of severe hemosiderin deposition, the ‘blooming artifact’ effect from gradient-echo MR images obscured visualization of the underlying synovium, resulting in an inaccurate assessment of the synovial hypertrophy sub-item of the MRI scoring system. In these cases, based on expert opinion, the maximum score (= 3) was given for both hemosiderin and synovial hypertrophy sub-items, which may have overestimated the sub-scores for synovial hypertrophy in this study.

In this study all the MRI examinations were performed on 1.5 T MRI scanners. However, it is well known that the effect of susceptibility variations on gradient-echo MRI sequences which generate undesirable ‘blooming artifacts’ are proportional to the MRI field strength (i.e. twice as large variations are found at 3 T than at 1.5 T) [20]. Thus, we anticipate that scores of hemosiderin deposition using the compatible MRI scoring system may be overestimated in MRI examinations performed at 3 T or higher field strength MRI scanners in future studies.

The MRI threshold [21] used to define treatment failure in the USA Joint Outcome Study reported by Manco-Johnson *et al.* [7] was set to detect early cartilage loss and osteochondral changes in index joints. The failure rate for full-dose primary prophylaxis in this prospective randomized clinical trial was 7%, as compared with 45% for enhanced episodic therapy [7]. While these findings are important and support the superiority of full-dose primary prophylaxis over enhanced episodic (‘on demand’) treatment in preventing very early cartilage and bone changes in the index joints of young boys with severe hemophilia, it should be noted that the long-term functional consequences of such early musculoskeletal changes, detected by a very sensitive imaging modality (MRI), remain to be determined. Such information is essential to assess the cost benefit of full-dose primary prophylaxis as compared with individualized (‘tailored’) prophylaxis that is based on the pattern of early bleeding in individual patients. Hemophilic arthropathy is a chronic problem in which the longitudinal progression of joint changes seen by MRI is unknown at the present time. Moreover, our findings cannot be directly compared with the USA Joint Outcome Study as our subjects were, on average, 2 years older and therefore more likely to have developed osteochondral changes, detectable by MRI. At this point no detailed information is available in the literature with regard to the normal appearance of growing joints on MR imaging. As a result, mild cartilage and soft tissue changes including hemosiderin deposition as described in this study may require reassessment in the future upon comparison with age-matched and MRI sequence-matched imaging of joints of healthy subjects once this information becomes available. Such an approach will enable confirmation of the mild soft tissue and cartilage results reported in this study.

Based on the soft tissue and osteochondral findings in this prospective study, we speculate that presence of persistent early joint swelling (as a measure of synovitis) detected by careful serial physical examination and confirmed by ultrasound and/or MRI may be important in identifying those joints that are likely to progress to more significant osteochondral damage. Alteration in the prophylaxis regimens in such cases, targeted at reducing the time spent with a FVIII level below 1% (a risk factor for spontaneous bleeding), may be warranted [22].

The inter-reader reliability for the MRIs in this study was excellent for evaluation of ankles and elbows, as previously reported [23]. However, the inter-reader reliability for knees was not strong. The fact that only soft tissue changes were



found in MRI examinations of knees in this study may have accounted for this result.

In summary, the results of this study show that MRI is able to detect chronic subclinical bleeding in the joints of young boys with severe hemophilia A who have no clinical history of joint bleeding. These results suggest that MRI can be a useful tool in assessing early joint changes in boys with severe hemophilia. Overall MRI scores correlated moderately with prior lifetime index joint hemarthroses. The correlations between physical examination and MRI joint scores were poor or moderate, confirming a relative insensitivity of physical therapy scores to depict the earliest joint changes of hemophilic arthropathy as previously demonstrated [7]. Therefore, outcome measures of primary prophylaxis studies should include not only joint scores by physical examination, but also sensitive imaging methods. Finally, although tailored primary prophylaxis may be inferior to full-dose prophylaxis (25 IU kg<sup>-1</sup> every other day) for the prevention of early osteochondral abnormalities detected by a very sensitive imaging technique (MRI), the long-term effect of this less intense regimen on the patients' quality of life and clinically significant musculoskeletal status is unknown at this time and warrants ongoing study. Whether the significant extra cost of full-dose prophylaxis vs. a 'tailored' primary prophylaxis approach is 'worth it' depends on whether the very early soft tissue and osteochondral changes detectable by MRI can reliably predict clinically significant hemophilic arthropathy in adolescence and adulthood. A longer period of follow-up is clearly needed to fully assess the long-term clinical significance of the musculoskeletal changes described in this study cohort.

### Acknowledgements

We would like to thank the Association of Hemophilia Clinic Directors of Canada, the Canadian Association for Nurses in Hemophilia Care and the Canadian Physiotherapists in Hemophilia Care for their continued support of the Canadian Hemophilia Primary Prophylaxis Study, A. Nicholson for assisting in the coordination of the imaging studies, and Man-Chiu Poon (Departments of Medicine, Pediatrics and Oncology, Alberta Children's Hospital, University of Calgary, Calgary, AB), V. Price (Division of Pediatric Hematology/Oncology, Izaak Walton Killam Hospital, Halifax, NS), R. Klaassen (Division of Hematology/Oncology, Children's Hospital of Eastern Ontario, Department of Pediatrics, University of Ottawa, Ottawa, ON) and J. Wu (Department of Pediatrics, BC Children's Hospital, University of British Columbia, Vancouver, BC) for contributing to patients' material for this study. This study is a tribute to the boys and their families who gave so generously of their time over a period that now approaches 14 years.

### Funding

The investigators gratefully acknowledge funding support from the Medical Research Council of Canada/PMAC (industry partner Bayer, Inc.) and the Bayer/Canadian Blood Services/

Hema-Quebec Partnership Fund for the CHPS study. The CHPS Extension Study and the MRI Study were funded by Bayer Healthcare Pharmaceuticals, Canada. A. Doria is a recipient of a Career Development Award from the Canadian Child Health Clinician-Scientist Program. B. Feldman is supported by the Canada Research Chair in Childhood Arthritis.

### Disclosure of Conflict of Interests

The authors state that they have no conflict of interest.

### References

- 1 Arnold WD, Hilgartner MW. Hemophilic arthropathy. Current concepts of pathogenesis and management. *J Bone Joint Surg Am* 1977; **59**: 287–305.
- 2 Fischer K, Valentino L, Ljung R, Blanchette V. Prophylaxis for severe haemophilia: clinical challenges in the absence as well as in the presence of inhibitors. *Haemophilia* 2008; **14**(Suppl. 3): 196–201.
- 3 Fischer K, van der Bom JG, Mauser-Bunschoten EP, Roosendaal G, Prejs R, De Kleijn P, Grobbee DE, van den Berg M. The effects of postponing prophylactic treatment on long-term outcome in patients with severe hemophilia. *Blood* 2002; **99**: 2337–41.
- 4 Feldman BM, Pai M, Rivard GE, Israels S, Poon MC, Demers C, Robinson S, Luke KH, Wu JK, Gill K, Lilliercap D, Babyn P, McLimont M, Blanchette VS. Tailored prophylaxis in severe hemophilia A: interim results from the first 5 years of the Canadian Hemophilia Primary Prophylaxis Study. *J Thromb Haemost* 2006; **4**: 1228–36.
- 5 Nilsson IM, Berntorp E, Lofqvist T, Pettersson H. Twenty-five years' experience of prophylactic treatment in severe haemophilia A and B. *J Intern Med* 1992; **232**: 25–32.
- 6 Petrini P, Lindvall N, Egberg N, Blomback M. Prophylaxis with factor concentrates in preventing hemophilic arthropathy. *Am J Pediatr Hematol Oncol* 1991; **13**: 280–7.
- 7 Manco-Johnson MJ, Abshire TC, Shapiro AD, Riske B, Hacker MR, Kilcoyne R, Ingram JD, Manco-Johnson ML, Funk S, Jacobson L, Valentino LA, Hoots WK, Buchanan GR, DiMichele D, Recht M, Brown D, Leissing C, Bleak S, Cohen A, Mathew P, *et al.* Prophylaxis versus episodic treatment to prevent joint disease in boys with severe hemophilia. *N Engl J Med* 2007; **357**: 535–44.
- 8 Nuss R, Kilcoyne RF, Geraghty S, Wiedel J, Manco-Johnson M. Utility of magnetic resonance imaging for management of hemophilic arthropathy in children. *J Pediatr* 1993; **123**: 388–92.
- 9 Kilcoyne RF, Nuss R. Radiological evaluation of hemophilic arthropathy. *Semin Thromb Hemost* 2003; **29**: 43–8.
- 10 Kilcoyne RF, Nuss R. Radiological assessment of haemophilic arthropathy with emphasis on MRI findings. *Haemophilia* 2003; **9**(Suppl. 1): 57–63.
- 11 Gilbert MS. Prophylaxis: musculoskeletal evaluation. *Semin Hematol* 1993; **30**: 3–6.
- 12 Pettersson H, Ahlberg A, Nilsson IM. A radiologic classification of hemophilic arthropathy. *Clin Orthop Relat Res* 1980; **149**: 153–9.
- 13 Ota S, McLimont M, Carcao MD, Blanchette VS, Graham N, Paradis E, Feldman BM. Definitions for haemophilia prophylaxis and its outcomes: the Canadian consensus study. *Haemophilia* 2007; **13**: 12–20.
- 14 Lundin B, Babyn P, Doria AS, Kilcoyne R, Ljung R, Miller S, Nuss R, Rivard GE, Pettersson H. Compatible scales for progressive and additive MRI assessments of haemophilic arthropathy. *Haemophilia* 2005; **11**: 109–15.
- 15 Doria AS, Babyn PS, Lundin B, Kilcoyne RF, Miller S, Rivard GE, Moineddin R, Pettersson H. Reliability and construct validity of

- the compatible MRI scoring system for evaluation of haemophilic knees and ankles of haemophilic children. Expert MRI working group of the international prophylaxis study group. *Haemophilia* 2006; **12**: 503–13.
- 16 Hacker MR, Funk SM, Manco-Johnson MJ. The Colorado Haemophilia Paediatric Joint Physical Examination Scale: normal values and interrater reliability. *Haemophilia* 2007; **13**: 71–8.
  - 17 Nuss R, Kilcoyne RF, Geraghty S, Shroyer AL, Rosky JW, Mahwinney S, Wiedel J, Manco-Johnson M. MRI findings in haemophilic joints treated with radiosynoviorthesis with development of an MRI scale of joint damage. *Haemophilia* 2000; **6**: 162–9.
  - 18 Fleiss JL. *Statistical Methods for Rates and Proportions*. New York: Wiley, 1981.
  - 19 Altman D. *Practical Statistics for Medical Research*. London: Chapman and Hall, 1991.
  - 20 Dietrich O, Reiser MF, Schoenberg SO. Artifacts in 3-T MRI: physical background and reduction strategies. *Eur J Radiol* 2008; **65**: 29–35.
  - 21 Nuss R, Kilcoyne RF, Rivard GE, Murphy J. Late clinical, plain X-ray and magnetic resonance imaging findings in haemophilic joints treated with radiosynoviorthesis. *Haemophilia* 2000; **6**: 658–63.
  - 22 Collins PW, Blanchette VS, Fischer K, Bjorkman S, Oh M, Fritsch S, Schroth P, Spotts G, Astermark J, Ewenstein B. Break-through bleeding in relation to predicted factor VIII levels in patients receiving prophylactic treatment for severe hemophilia A. *J Thromb Haemost* 2009; **7**: 413–20.
  - 23 Doria AS, Lundin B, Miller S, Kilcoyne R, Dunn A, Thomas S, Rivard G, Moineddin R, Babyn PS. Reliability and construct validity of the compatible MRI scoring system for evaluation of elbows in haemophilic children. *Haemophilia* 2008; **14**: 303–14.