

UC Irvine

UC Irvine Previously Published Works

Title

Wiskott-Aldrich Syndrome

Permalink

<https://escholarship.org/uc/item/07v8483s>

Journal

Journal of Pediatric Hematology/Oncology, 37(7)

ISSN

1077-4114

Authors

Yoonessi, Leila
Randhawa, Inderpal
Nussbaum, Eliezer
et al.

Publication Date

2015-10-01

DOI

10.1097/mpH.0000000000000392

Copyright Information

This work is made available under the terms of a Creative Commons Attribution License, available at <https://creativecommons.org/licenses/by/4.0/>

Peer reviewed

Wiskott-Aldrich Syndrome: Description of a New Gene Mutation With Normal Platelet Volume

Leila Yoonessi, MD,* Inderpal Randhawa, MD,* Eliezer Nussbaum, MD,*
Samah Saharti, MD,† Paul Do, MD,* Terry Chin, MD,*
and Ted Zwerdling, MD‡

METHODS

A literature search was conducted in PubMed under the search terms “Wiskott-Aldrich Syndrome, clinical presentation, genotypes, gene mutations, mean platelet volume, diagnosis, etiology.”

Genomic DNA was isolated from the patient’s peripheral blood mononuclear cells by standard techniques. Recovered DNA was then subjected to polymerase chain reaction amplification of exons 1 to 10 and their flanking splice sites. Bidirectional sequencing of the polymerase chain reaction amplification products was performed and subsequent results compared with published reports using the cDNA reference sequence NM_000377.2.

Analysis of bone marrow specimens, peripheral blood, and skin biopsy were all performed by standard laboratory techniques.

WAS protein expression in peripheral blood lymphocytes was analyzed at Cincinnati Children’s Hospital (Cincinnati, OH) in the Diagnostic Immunology Laboratory using a multiparametric flow cytometry assay. Patient WAS protein expression is reported as the ratio of mean channel fluorescence (MCF) compared with normal controls (normal range, 0.71-1.31 MCF).

Platelet volume (PV) in our laboratory ranges from 7.5 to 9.9 fL for males aged 0 to 5 years. As reported in the National Health and Nutrition Examination Survey 2002, PV normal range is 6.7 to 9.9 fL.⁵

RESULTS

Case Report and Clinical Outcome

The patient first presented at 6 weeks of age as a previously healthy full-term male, with 1 week of blood-streaked stools and thrombocytopenia, normal growth parameters, and erythematous diaper rash. The rest of the examination was normal. Laboratory evaluation included a complete blood count which was normal except for platelets of 33 K/ μ L with a MPV of 7.9 fL. A colonoscopy and bone marrow biopsy to evaluate underlying etiology of lower gastrointestinal bleeding and thrombocytopenia were performed. Increased eosinophils in the rectal biopsy material and distorted crypts in colonic tissue were felt to be consistent with milk protein allergy changes. Results of the bone marrow biopsy were normal except for slightly increased megakaryocytes. The patient had formula changed and received 4 days of intravenous γ -globulin (IVIg), 2 platelet transfusions, and 1 U packed red blood cells. The remainder of evaluations, including for infectious agents, were negative.

At 3 months of age, the patient was hospitalized for a croup-like illness, noted to have left shoulder and subglottic

Summary: Wiskott-Aldrich syndrome (WAS) is a rare X-linked primary immunodeficiency characterized by an increased incidence of autoimmunity, malignancy, microthrombocytes with thrombocytopenia, eczema, and recurrent infections. In this case report, we present a novel mutation, hemizygous for c.1125_1129delTGGAC mutation in the *WAS* gene, and a unique clinical presentation. Our patient was initially diagnosed with a milk protein allergy after presenting with a lower gastrointestinal bleed, leukopenia, and thrombocytopenia with normal platelet volume. However, signs of vasculitis and detection of microthrombocytes required additional testing and consideration of WAS. This case report illustrates the importance of retaining a high index of clinical suspicion despite normal platelet volume, as well as adding to the growing number of known mutations associated with WAS.

Key Words: Wiskott-Aldrich syndrome, new mutation, normal platelet volume

(*J Pediatr Hematol Oncol* 2015;37:515–518)

Wiskott-Aldrich syndrome (WAS) is rare disease characterized by microthrombocytopenia, infectious complications secondary to immunodeficiency, autoimmune phenomena, and increased incidence of malignancy.^{1,2} The *WAS* gene is located at Xp11.22-p11p23. An important hallmark of this disorder is the presence of small platelets which can be observed on a blood film and now quantitated with modern blood analyzers. This disorder can be difficult to diagnose in first-affected males because patients may not present with classic signs and symptoms, which is only heightened by overlap with other more common causes of thrombocytopenia in this age group.³ Furthermore, mutations in the same gene are also associated with other disorders such as X-linked thrombocytopenia and X-linked neutropenia.^{3,4}

We detail the presentation of a patient who was initially felt to have a milk protein allergy and normal size platelets. Only after several weeks did he manifest other signs of vasculitis which eventually lead to the diagnosis of WAS and the uncovering of a new gene mutation.

Received for publication August 14, 2014; accepted June 17, 2015.
From the Departments of *Pulmonology; †Pathology; and ‡Hematology/Oncology, Jonathan Jaques Children’s Cancer Center, Miller Children’s Hospital, Long Beach, CA.
The authors declare no conflict of interest.
Reprints: Ted Zwerdling, MD, Department of Hematology/Oncology, Jonathan Jaques Children’s Cancer Center, Miller Children’s Hospital, 2801 Atlantic Avenue, Long Beach, CA 90802 (e-mail: ted.zwerdling@gmail.com).
Copyright © 2015 Wolters Kluwer Health, Inc. All rights reserved.

TABLE 1. Immunophenotyping Results Performed on Peripheral Blood

Cell Type	CD	Absolute Count (K/ μ L)	Percentage
B-lineage	19	122	15
Lymphocyte (total)	3	490	60
Helper/inducer	4	449	55
Cytotoxic/suppressor	8	33	4
Natural killer cells	56	180	22

White blood cell count = 5200 K/ μ L, lymphocyte percent = 10 (absolute 0.832 K/ μ L).

hemangiomas, and persistent thrombocytopenia now microcytic (6.5 fL). He was also described as irritable without obvious cause and an eczematous rash on the face. During the hospitalization, a vesicular scalp rash developed, followed by scalp swelling and an intermittent erythematous rash on the lower extremities. A petechial rash was noted mostly on the face and lower extremities. Infectious evaluation was again negative and dermatology was consulted. Hemotoxylin and eosin staining of the biopsy material found small thin-walled, muscular vessels with evidence of leukocytoclastic vasculitis. Features of the vasculitis included infiltrating neutrophils, occasional lymphocytes, and surrounding the walls of small vessels, associated karyorrhectic nuclear debris. No nodular inflammatory reaction, evidence of vessel wall necrosis, or eosinophilia was present. Staining for the presence of immunoglobulin, C3, C1q, and fibrinogen was negative. Results of investigations of the immune system by flow cytometry are shown in Table 1. The diagnosis of WAS was entertained and sequencing for the *WAS* gene performed (Figs. 1, 2). A WAS protein (WASp) expression assay confirmed the diagnosis of WAS with the MCF ratio of 0.15 in peripheral blood lymphocytes.

The patient was started on trimethoprim-sulfamethoxazole, IVIg infusions, and platelet transfusions (Fig. 3)

for bleeding episodes which most frequently involved skin around the neck area. Human leukocyte antigen typing was performed but a full sibling was not a match. Given the patient’s high-risk features (vasculitis), he was referred for allogeneic stem cell transplantation. The patient was conditioned with busulfan, fludarabine, clofarabine, and alemtuzumab for a 10/12 matched unrelated donor transplant. Unfortunately the patient rejected the graft and a second transplant was successful with alemtuzumab, melphalan, thiotepea, and fludarabine. Engraftment occurred on day 34. He has had multiple complications including viral, fungal and bacterial infections, eczema, weight loss, and graft-versus-host disease.

DISCUSSION

Currently, there are 3 WASp mutation-associated syndromes including classic WAS, X-linked thrombocytopenia, and congenital neutropenia without other WAS features.⁶ A scoring system, based on clinical manifestations of the disease has been developed, and correlated with molecular lesions.⁷ Patients who do not express the WAS protein or express a mutant form, as demonstrated in this case report, are more likely to have a high score than patients with missense mutations. Application of this scoring system from 1 (low) to 5 (high) has been suggested to be a useful clinical guide for estimating future clinical severity and helping to recommend therapeutic options. Patients with low scores may be watched with conservative management, whereas patients with high score are likely to have serious manifestations of WAS, including intracranial hemorrhage. These patients may be better treated with stem cell transplantation. The patient reported herein was assigned a score of 5 because of clinical and histologic evidence of vasculitis.

Several aspects of this case deserve comment. Early recorded MPV of 7.9 fL, are well above lower limit of normal for our laboratory (7.5 fL) and larger than published reports (6.7 fL) occurred before any platelet or IVIg

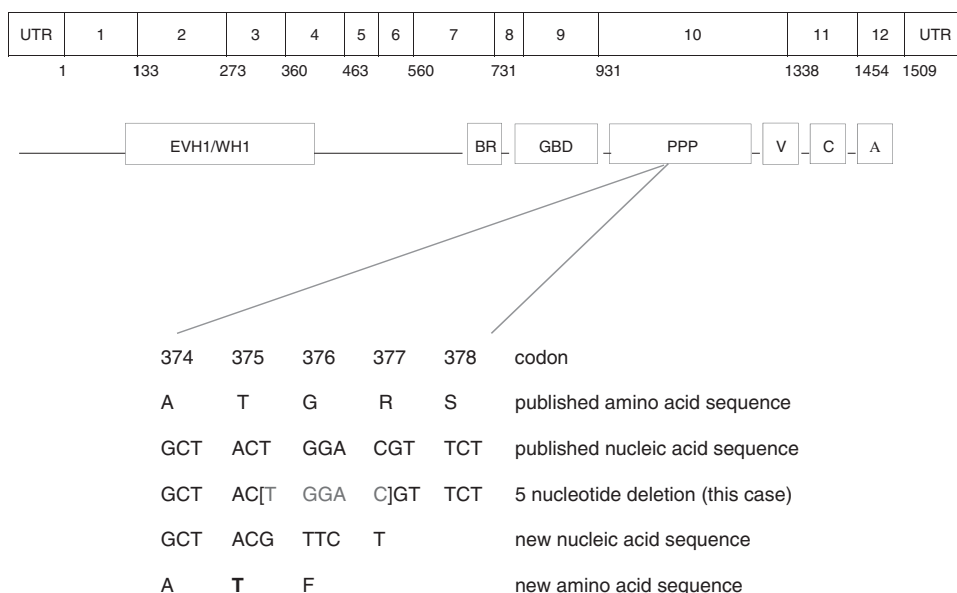


FIGURE 1. WAS gene structure, protein domains and mutation analysis. A 5-nucleotide deletion resulting in a frameshift in the PPP domain and downstream change in amino acid sequence. WAS indicates Wiskott-Aldrich syndrome.

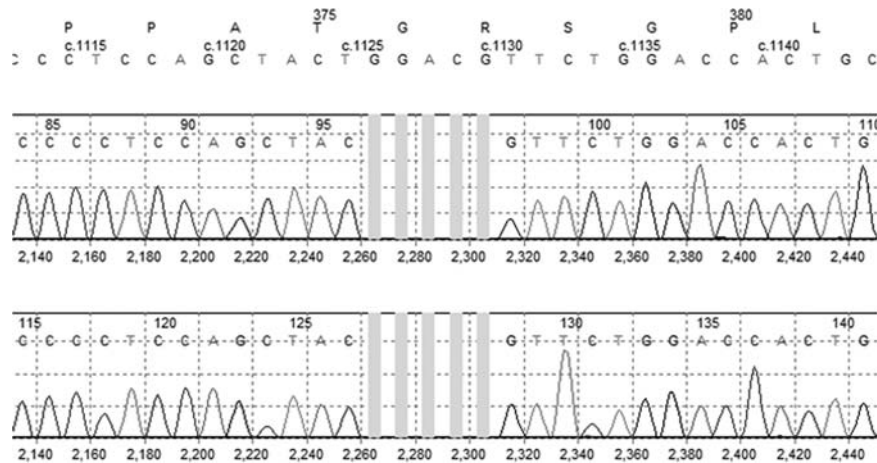


FIGURE 2. Results of DNA sequence analysis demonstrating 5-base pair T-G-G-A-C deletion. Gray bars represent 5-base deletion detected by gene sequence analysis.

infusions.⁵ Some platelet infusions appeared to increase the platelet count or stop skin bleeding; whereas other infusions did not have any effect. It was only after IVIg, given 1 to 3 weeks before platelet infusion, which resulted in a predictable increase. Although the platelet count rapidly decreased thereafter, the MPV continued to rise, suggesting an effect of the IVIg on the patient’s own platelets. Studies in the literature report similar observations after splenectomy where MPV can increase transiently.⁸ Several theories that have been forwarded to explain this phenomenon include immunologic changes or altered splenic function, however, this remains conjecture.

This patient also had other manifestations of autoimmune phenomenon which were variable. Diarrhea, initially felt to represent milk protein allergy phenomena was without infectious etiology and demonstrated a waxing and waning course. He also had episodes of irritability without identifiable cause. During this time, a skin biopsy suggested

a leukocytoclastic reaction consistent with vasculitis and raised the possibility of WAS.⁹

WAS gene codes for a 502 amino acid protein known only to be expressed in cells of the lymphohematopoietic lineage. The protein is responsible for signal transduction from cell surface to the cytoplasm where it participates in binding to actin.³ The new mutation described in this patient resides in exon 10, an area known as the PPP domain. Badour et al¹⁰ have demonstrated the requirement of this domain for proper formation of the immunologic synapse needed for T-cell function. Several SH3 domains are present in this area and allow binding of other adapter proteins such as BTK and TEC, among others. The 5-base deletion found by gene sequencing eliminated part of codons 375 (threonine) and 377 (arginine) and all of codon 376 (glycine). Even though the nucleic acid sequence changed, due to degeneracy, codon 375 still coded for threonine, but codon 376 was mutated to phenylalanine. As a result of the frameshift, a downstream change in protein sequence involving the remaining 127 amino acids is predicted as well as introduction of a premature stop codon. This truncated form of the WASp would have little in the way of actin or other adapter-binding properties, as described in other mutations with a severe phenotype. Indeed, this patient’s clinical score was estimated to be 5, indicative of severe disease, lead us to recommend matched unrelated donor stem cell transplantation early on in the course of treatment.¹¹

Finally, we are aware of only one other well-documented report of a patient with WAS who had a normal MPV that did not subsequently downtrend. Patel et al¹² reported a 10-month old with WAS and PV of 7.1 to 9.8 fL (normal, 8 to 12 fL). Of the 24 blood counts reviewed from this patient, only 1 was microcytic (7.1 fL), with the remainder ≥ 7.8 fL. These authors also reported a novel mutation in exon 9 (nonsense mutation, c.862A > T [K288X]).

In conclusion, we report a patient with WAS and a new gene mutation which would disrupt WASp function within the PPP domain, a severe phenotype, and several normal MPV. IVIg infusions on several occasions resulted in increased MPV, without increased in platelet numbers. This report adds to the growing number of mutations and increasing complex clinical manifestations associated with WAS.

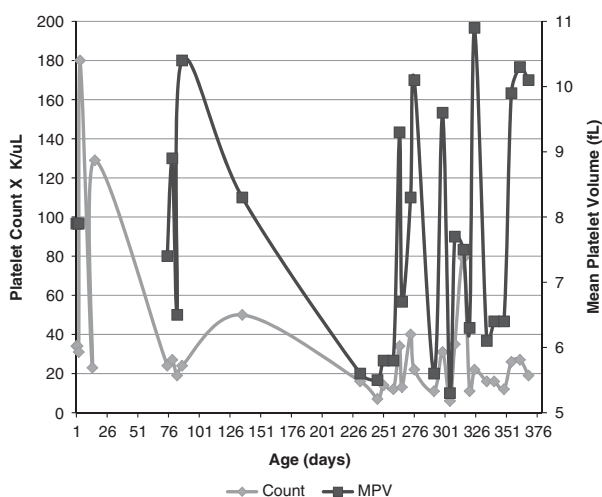


FIGURE 3. Graphic representation of patient age versus platelet count (k/ μ L) and mean platelet volume (MPV) (fL). Platelets transfused at days 4, 79, and 273. Intravenous γ -globulin (IVIg) infused at days 3, 26, and 275.

REFERENCES

1. Aldrich R, Steinberg A, Campbell D. Pedigree demonstrating a sex-linked recessive condition characterized by draining ears, eczematoid dermatitis and bloody diarrhea. *Pediatrics*. 1954;13:133–139.
2. Massaad MJ, Ramesh N, Geha RS. Wiskott-Aldrich syndrome: a comprehensive review. *Ann NY Acad Sci*. 2013;1285:26–43.
3. Blundell MP, Worth A, Bouma G, et al. The Wiskott-Aldrich syndrome: the actin cytoskeleton and immune cell function. *Dis Markers*. 2010;29:157–175.
4. Knox-Macaulay HH, Bashawri L, Davies KE. X-linked recessive thrombocytopenia. *J Med Genet*. 1993;30:968–969.
5. Laboratory Procedure Manual Complete Blood Count (CBC) With Five-Part Differential: National Health and Nutrition Examination Survey. 2001–2002; 29–30.
6. Ochs HD, Rosen FS. Wiskott-Aldrich syndrome. In: Ochs HD, Smith CIE, Puck JM, eds. *Primary Immunodeficiency Diseases, a Molecular and Genetic Approach*. New York: Oxford University Press; 2007:454–469.
7. Ochs H. Mutations of the Wiskott-Aldrich syndrome protein affect protein expression and dictate the clinical phenotypes. *Immunol Res*. 2009;44:84–88.
8. Litzman J, Jones A, Hann I, et al. Intravenous immunoglobulin, splenectomy, and antibiotic prophylaxis in Wiskott-Aldrich syndrome. *Arch Dis Child*. 1996;75:436–439.
9. Al-Herz W, Nanda A. Skin manifestations in primary immunodeficient children. *Pediatr Dermatol*. 2011;28:494–501.
10. Badour K, Marvin MKH, Zhang J, et al. Interaction of the Wiskott-Aldrich syndrome protein with sorting nexin 9 is required for CD28 endocytosis and co-signaling in T cells. *Proc Natl Acad Sci USA*. 2007;104:1593–1598.
11. Moratto D, Giliani S, Bonfim C, et al. Long-term outcome and lineage-specific chimerism in 194 patients with Wiskott-Aldrich syndrome treated by hematopoietic cell transplantation in the period 1980-2009: an international collaborative study. *Blood*. 2011;118:1675–1684.
12. Patel PD, Samanich JM, Mitchell WB, et al. A unique presentation of Wiskott-Aldrich syndrome in relation to platelet size. *Pediatr Blood Cancer*. 2011;56:1127–1129.