

UC Davis

Dermatology Online Journal

Title

Wolf isotopic response: immunotherapy-related lichenoid eruption localizing to prior radiation site

Permalink

<https://escholarship.org/uc/item/0733g17s>

Journal

Dermatology Online Journal, 30(6)

Authors

Jafari, Alexander J
Kuraitis, Drew

Publication Date

2024

DOI

10.5070/D330664696

Copyright Information

Copyright 2024 by the author(s). This work is made available under the terms of a Creative Commons Attribution-NonCommercial-NoDerivatives License, available at

<https://creativecommons.org/licenses/by-nc-nd/4.0/>

Peer reviewed

Wolf isotopic response: immunotherapy-related lichenoid eruption localizing to prior radiation site

Alexander J Jafari¹ MD MPH, Drew Kuraitis^{2,3} MD PhD

Affiliations: ¹Department of Dermatology, University of Texas Health McGovern Medical School, Houston, Texas, USA,

²Department of Dermatology, Roswell Park Comprehensive Cancer Center, Buffalo, New York, USA, ³Department of Dermatology, Tulane University School of Medicine, New Orleans, Louisiana, USA

Corresponding Author: Drew Kuraitis MD PhD FAAD, Department of Dermatology, Roswell Park Comprehensive Cancer Center, 665 Elm Street, Buffalo, NY 14203, Email: dkuraiti@tulane.edu

Abstract

Wolf isotopic response refers to a new skin disorder manifesting in the area of a previous skin lesion that has healed. A variety of disease processes and dermatoses have been described that evoke an isotopic response. We report a man with metastatic hepatocellular carcinoma who received palliative radiation and later experienced a pembrolizumab-induced lichenoid dermatitis at the same site of radiation, representing a cutaneous immune-related adverse event displaying an isotopic response.

Keywords: adverse event, cutaneous, immune-related, immunotherapy, isomorphic response, isotopic, lichen planus, lichenoid dermatitis, Wolf

Introduction

In 1985, Wolf and Wolf first described an isotopic response, characterized as the occurrence of a new skin disorder at the site of previous skin lesion that has already healed [1]. To-date, many of the descriptions of Wolf isotopic response (WIR) have been of dermatoses or lesion development at the site of a healed viral infection.

Case Synopsis

A man in his 60s presented to dermatology clinic for evaluation of a rash. He had a past medical history of metastatic hepatocellular carcinoma and had

received palliative radiation to the left side of his back for bony metastases a few months prior to starting pembrolizumab immunotherapy for treatment of his malignancy. Shortly after starting pembrolizumab, he developed a pruritic, scaly rash on the trunk. To the left side of his back, there was a well demarcated hyperpigmented patch in the site of previous radiation, with numerous colonizing and coalescing erythematous-to-violaceous scaly papules (**Figure 1**). A biopsy demonstrated a lichenoid infiltrate with numerous eosinophils (**Figure 2**). A lichenoid cutaneous immune-related adverse event (cirAE) localized to a site of previous radiation was diagnosed, representing an isotopic response. The patient passed away shortly after evaluation of the cirAE and no outcome regarding this diagnosis is available.

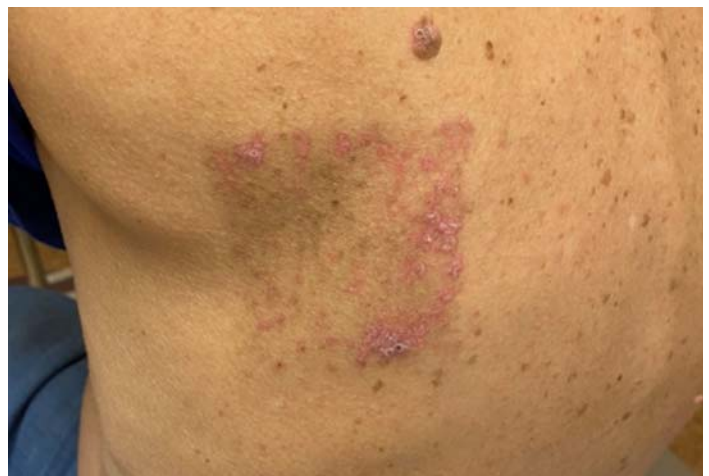

Figure 1. Coalescing erythematous-to-violaceous scaly papules localized to a well demarcated hyperpigmented patch at the site of previous radiation therapy on the back.

Case Discussion

In 2017, Wolf and Wolf altered their definition of WIR, given that the original requirement for a new disease appearing on apparently healthy and unaffected skin may not fit, as previously affected or injured skin may exhibit ongoing damage or long-lasting changes to the local microenvironment [2]. The updated and expanded definition of WIR notes that “an isotopic response occurs when the site of the healed disease determines the site of the second entirely unrelated disease.” The first disease may now include pigmentary changes, scars, or other minimal changes left by the first disease. It is postulated that the second dermatosis follows a “path of least resistance” and appears at sites that carry memory from previous inflammation or injury. It is important to differentiate WIR from the isomorphic response of Koebner, which describes the appearance of an existing disease at another location, such as in patients with psoriasis or lichen planus who may develop new lesions of the same disease at sites of injury.

Conclusion

Cutaneous immune-related adverse events secondary to immunotherapy have diverse clinical presentations with variable timing of onset [3], but they are not commonly known to display isomorphic or isotopic responses. Post-radiation changes are also not commonly reported as the first disease that dictates the location of the second disease in WIR. Many cirAEs, such as lichenoid eruptions, spongiotic dermatitides, or bullous pemphigoid, may mimic their idiopathic counterparts clinically. Although lichenoid dermatitides are known to exhibit isomorphic responses, they have rarely been reported to display isotopic responses [4]. It is presumed that the patient’s lichenoid cirAE in the case discussed here followed the “path of least resistance” and its presence was determined by the site of previous radiation therapy. Herein, we report a lichenoid cirAE dictated by the site of cutaneous radiation changes, representing Wolf isotopic response.

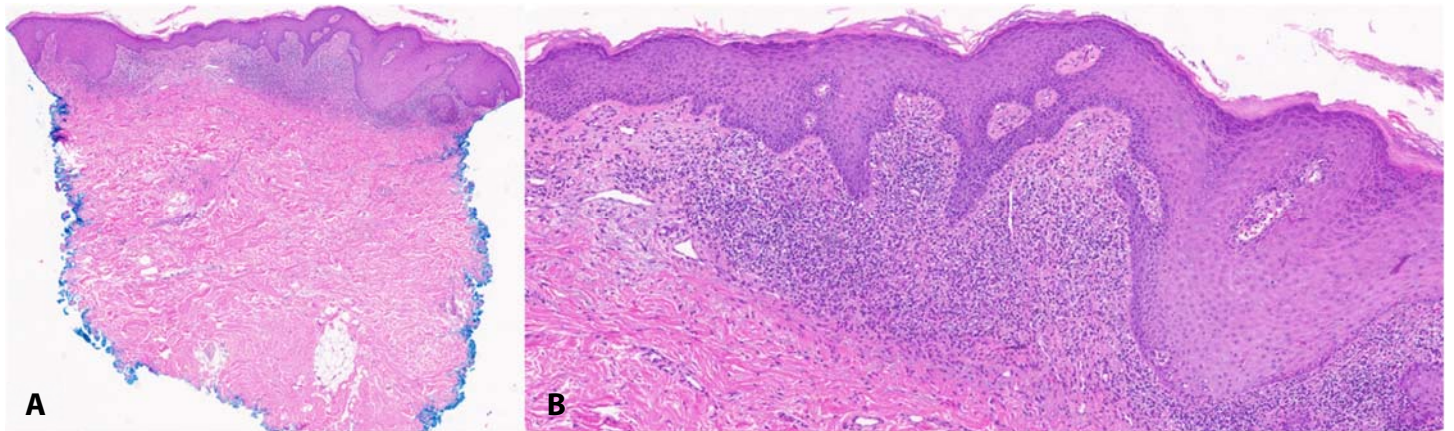


Figure 2. H&E histopathology of biopsy of rash on patient’s back demonstrating a lichenoid infiltrate **A)** at low power, 12x; **B)** with the presence of eosinophils, 42x.

Potential conflicts of interest

The authors declare no conflicts of interest.

References

1. Wolf R, Wolf D. Tinea in a site of healed herpes zoster (isolici response?). *Int J Dermatol.* 1985;24:539. [PMID: 4066096].
2. Wolf R, Wolf D. “Wolf’s isotopic response”: the originators speak their mind and set the record straight. *Clin Dermatol.* 2017;35:416-418. [PMID: 28709573].
3. Wongvibulsin S, Pahalyants V, Kalinich M, et al. Epidemiology and risk factors for the development of cutaneous toxicities in patients treated with immune-checkpoint inhibitors: A United States population-level analysis. *J Am Acad Dermatol.* 2022;86:563-572. [PMID: 33819538].
4. Wolf R, Wolf D, Ruocco E, Brunetti G, Ruocco V. Wolf’s isotopic response. *Clin Dermatol.* 2011;29:237-40. [PMID: 21396564].