

# UC Irvine

## UC Irvine Previously Published Works

### Title

Fluid imbibition at the bone-cartilage interface is associated with need for early chondroplasty following osteochondral allografting of the knee

### Permalink

<https://escholarship.org/uc/item/0729s1nq>

### Journal

Journal of Clinical Orthopaedics and Trauma, 10(Suppl 1)

### ISSN

0976-5662

### Authors

Balazs, George C  
Wang, Dean  
Burge, Alissa J  
[et al.](#)

### Publication Date

2019-10-01


### DOI

10.1016/j.jcot.2019.03.023

### Copyright Information

This work is made available under the terms of a Creative Commons Attribution License, available at <https://creativecommons.org/licenses/by/4.0/>

Peer reviewed



# Fluid imbibition at the bone-cartilage interface is associated with need for early chondroplasty following osteochondral allografting of the knee<sup>☆</sup>

George C. Balazs<sup>a,\*</sup>, Dean Wang<sup>b</sup>, Alissa J. Burge<sup>c</sup>, Riley J. Williams III<sup>d</sup>

<sup>a</sup> Sports Medicine and Shoulder Service, Hospital for Special Surgery, 620 John Paul Jones Cir, Portsmouth, 23708, VA, USA

<sup>b</sup> Department of Orthopaedic Surgery, University of California, Irvine, USA

<sup>c</sup> Department of Radiology, Hospital for Special Surgery, New York-NY, USA

<sup>d</sup> Sports Medicine and Shoulder Service, Hospital for Special Surgery, New York, NY, USA

## ARTICLE INFO

### Article history:

Received 27 October 2018

Received in revised form

9 March 2019

Accepted 28 March 2019

Available online 30 March 2019

### Keywords:

Osteochondral allograft

Osteochondral autograft

Cartilage

## ABSTRACT

**Purpose:** To determine the clinical significance of fluid imbibition at the bone-cartilage interface seen on postoperative MRI scans after osteochondral grafting of chondral lesions of the knee.

**Methods:** Retrospective review of patients enrolled in a prospective cartilage repair registry. Included patients underwent osteochondral autografting or allografting of the knee, had minimum one year of clinical follow-up, and underwent at least two postoperative MRI scans. The primary outcome was reoperation for arthroscopic debridement and chondroplasty or graft revision. Secondary outcomes included the radiographic fate of fluid imbibition.

**Results:** A total of 48 knees in 46 patients were analyzed, with mean 39 months clinical follow-up. Nine patients (19%) had fluid imbibition on at least one postoperative MRI scan, all of whom received allograft. Of these, two (22%) required eventual graft revision, four (45%) underwent arthroscopic chondroplasty but did not require revision, and three (33%) did not require any additional surgery by final follow-up. No demographic or surgical variable was associated with the presence of fluid imbibition. Fluid imbibition was significantly associated with need for chondroplasty ( $p = 0.05$ ), but not graft revision.

**Conclusions:** Fluid imbibition on postoperative MRI following osteochondral allografting of the knee is associated with the need for arthroscopic chondroplasty, but should not be interpreted as a sign of a failing graft.

**Level of evidence:** Level IV, Case Series.

© 2019 Delhi Orthopedic Association. All rights reserved.

## 1. Introduction

Osteochondral allograft or autograft transplantation is a reliable treatment for large chondral defects of the knee, especially when lesions are unconstrained or there is evidence of diseased subchondral bone.<sup>1</sup> Medium- and long-term survival rates are high, and the procedure reliably relieves pain and improves function even in high-demand patients.<sup>2,3</sup> Nonetheless, reported

reoperation rates are as high as 37%,<sup>4</sup> and patients who do ultimately fail will often first undergo one or more arthroscopic surgeries for synovectomy, chondroplasty, and graft assessment prior to revision grafting or arthroplasty.

Magnetic resonance imaging (MRI) provides a non-invasive method for monitoring graft incorporation and articular surface healing following osteochondral grafting. Utilizing modern pulse sequences, clinicians may monitor both the articular surface of the graft as well as the subchondral bone. MRI permits assessment of graft integration, articular step-off, health of the chondral surface, as well as reliably diagnosing osteonecrosis and host-immune response.

There are several reported MRI-based scoring systems with excellent interobserver reliability and validity, including the 3D MOCART<sup>5</sup> and OCAMRISS.<sup>6</sup> These systems assess multiple aspects

<sup>☆</sup> Investigation performed at Hospital for Special Surgery, New York, NY (Hospital for Special Surgery IRB #2013–024).

\* Corresponding author.

E-mail addresses: [gcbalazs@gmail.com](mailto:gcbalazs@gmail.com), [george.c.balazs.mil@mail.mil](mailto:george.c.balazs.mil@mail.mil) (G.C. Balazs), [deanwangmd@gmail.com](mailto:deanwangmd@gmail.com) (D. Wang), [BurgeA@hss.edu](mailto:BurgeA@hss.edu) (A.J. Burge), [WilliamsR@hss.edu](mailto:WilliamsR@hss.edu) (R.J. Williams).

of graft health and integration. However, despite many series assessing MRI appearance of osteochondral grafts, correlation of imaging scores to clinical failure or patient reported outcome measures remains elusive. In most series assessing imaging and clinical correlation, only a few subscores seem related to clinical outcomes, and these frequently differ between studies.

Anecdotally, we have noted that the presence of fluid at the graft bone-cartilage interface is a not uncommon finding on surveillance post-operative MRI following osteochondral grafting. This is frequently interpreted in our institution as “impending delamination of the chondral surface” in our institution. This finding is not part of any commonly used MRI scoring system following cartilage repair, and to the best of our knowledge this finding has not previously been critically assessed in the orthopaedic literature.

The purpose of this study was to assess the frequency of fluid signal at the bone-cartilage interface following osteochondral grafting, the radiographic fate of this fluid signals, and determine whether this finding correlated with need for reoperation. We hypothesized that fluid imbibition at the bone-cartilage interface seen on MRI following osteochondral allografting predicts early graft failure.

## 2. Methods

Since 1999, our institution has maintained a prospective registry tracking patients undergoing cartilage procedures. As part of the Institutional Review Board-approved protocol, all patients enrolled in the registry sign an informed consent form prior to surgery. Baseline assessment is completed, and patients are approached for follow-up at 1, 2, 3, 4, 5, and 10 years postoperatively. Demographic, surgical, and radiologic data are also recorded. This registry was queried for all patients undergoing osteochondral allografting or autografting for focal chondral lesions of the knee between January 2010–December 2015. Patients were indicated for osteochondral grafting based on their activity level, characteristics of the cartilage lesion, involvement of subchondral bone, and patient/surgeon preference.

### 2.1. Inclusion and exclusion criteria

Inclusion criteria were (1) one or more symptomatic focal chondral lesions of the knee classified as Outerbridge grade 4 lesions at the time of index surgery, (2) treatment with fresh osteochondral allograft or autograft, (3) minimum one year clinical follow-up with an orthopaedic surgeon at our facility, and (4) two or more post-operative MRIs of the affected knee post-operatively completed within our facility. Exclusion criteria were the presence of metallic implants interfering with interpretation of post-operative MRI scans, and post-operative MRI scans completed at outside facilities. No patient had a ligamentous knee injury or required meniscal repair or transplantation. We chose to include patients who underwent concurrent procedures such as proximal tibial or distal femoral osteotomies as long as the MRI scans were interpretable. Additionally, when patients identified during our query were found to have had osteochondral grafting of the contralateral knee, we included the second knee even if surgery occurred outside our specified time frame.

### 2.2. Patients

Demographic, intraoperative, and clinical outcome data were collected for all patients. Where specific data fields were not recorded in the registry, we searched available electronic medical records to minimize the occurrence of missing data. Demographic data included age at the time of surgery, sex, race, and surgeon.

Intraoperative data included the affected side, location of lesion, type and number of grafts, any prior cartilage repair procedures, and any secondary procedures at the time of index surgery. Clinical outcome data included the date and nature of any reoperations, clinical failure (defined as undergoing graft removal, revision, or conversion to arthroplasty), and length of follow-up. While patient reported outcome measures (PROMs) are collected as part of our registry, only about half of the patients in this cohort had provided follow-up responses, and so this data was not included in the study.

### 2.3. Surgical indications and procedure

Osteochondral grafting was indicated based on the clinical judgment of the treating surgeon depending on the nature and size of the chondral lesion. Generally, osteochondral autografting was performed for smaller, full-thickness lesions <2 cm<sup>2</sup>. Osteochondral allografting was usually reserved for lesions >2 cm<sup>2</sup>. Failure of prior cartilage repair procedures was not considered a contraindication. Autologous chondrocyte implantation (ACI) and related procedures are rarely performed in our institution due to the need for two procedures, slower rehabilitation and return to sport, and surgeon preference.

All procedures were performed by one of five fellowship-trained orthopaedic surgeons with extensive experience in cartilage repair procedures. All patients initially underwent diagnostic arthroscopy to confirm the presence of chondral pathology seen on MRI, and to assess and treat any other intraarticular injuries.

Once complete, arthroscopic instruments were removed and a small parapatellar arthrotomy made (medial or lateral, depending on the location treated). The patella was everted only in cases where patellar lesions were treated. The chondral lesion was debrided to stable margins, sized, and reamed to a bed or normal bone. Where autograft was deemed appropriate, grafts were harvested from the non-weight bearing portion of the trochlea or intercondylar notch. Where allograft was required, donor tissue was obtained from commercial sources adhering to processing and screening guidelines set forth by the American Association of Tissue Banks. All allografts were transplanted between 16 and 30 days after harvest. Grafts were cut to the appropriate depth following careful measurement of the recipient site at three or four points around the lesion, and impacted into place.

Post-operatively, patients were made toe-touch or non-weight bearing for at least 1–2 weeks, but were permitted full range of motion immediately. Continuous passive motion was instituted in most cases. A hinged knee brace was worn continuously until adequate quadriceps strength had been regained (typically 2–6 weeks postoperatively). All patients underwent a structured physical therapy program until normal gait and quadriceps function was restored, as well as sport-specific rehabilitation as required. Return to sport was allowed based on individual progression, usually starting with a return-to-running program at six months post-operatively.

In all cases of reoperation for either arthroscopy with debridement/chondroplasty or revision of graft, the decision to proceed with surgery was made solely on the basis of clinical symptoms.

### 2.4. Imaging assessment

All post-operative MRI scans were obtained at our facility on a 1.5–3.0T MR imaging system (General Electric Healthcare, Waukesha, WI) utilizing a dedicated extremity coil and standardized clinical imaging protocol consistent with ICRS guidelines for assessment of articular cartilage. Fluid sensitive fat suppressed images (inversion recovery [IR] or T2 with fat saturation [T2 FS]) were obtained in the sagittal plane. High resolution proton density

(PD) weighted fast spin echo (FSE) images were obtained in the axial, sagittal, and coronal planes, with an effective echo time (TE) of approximately 25 ms selected for generation of tissue contrast ideal for evaluation of hyaline articular cartilage.

Post-operative MRI scans were reviewed by an orthopaedic sports medicine fellow and fellowship-trained musculoskeletal radiologist. All sequences were reviewed for evidence of fluid imbibition between the cartilaginous and bony surfaces of the autograft or allograft, or fluid imbibition directly beneath the subchondral lamina, as characterized by linear hyperintense fluid signal along the interface between the articular cartilage and underlying subchondral plate, or along the interface between the subchondral plate and underlying trabecular bone. An example is shown in Fig. 1. The presence of fluid imbibition was recorded as a binary “yes” or “no”. The presence of synovitis and a joint effusion was similarly recorded. Additionally, the time from surgery to MRI scan was also recorded, as was the time between follow-up MRI scans.

### 2.5. Statistical analysis

Cohort features were reported descriptively using counts, means, and ranges. The primary outcomes were need for arthroscopic chondroplasty and revision following osteochondral grafting. Univariate associations between the primary outcomes and candidate risk factors were determined using the chi square test or Fisher’s exact test for categorical variables as appropriate, and the Mann-Whitney *U* test for continuous variables. All analysis was performed using IBM SPSS Statistics for Mac, Version 25 (Armonk, NY).

## 3. Results

### 3.1. Cohort characteristics

During the study period, 931 patients were enrolled in our institutional registry, of whom 173 underwent osteochondral allografting or autografting. Of these, 50 patients met all inclusion criteria and had at least two surveillance MRIs completed as part of their routine post-operative care. Two patients were excluded as the presence of prior metallic implants around the knee obscured complete visualization of their chondral surfaces.

The final study cohort comprised 48 knees in 46 patients. Cohort

characteristics are summarized in Table 1. Mean follow-up was 39 months. The majority of patients were male (79%), Caucasian (90%). A total of 57 lesions were treated, most of which were on the medial femoral condyle (35%) and lateral femoral condyle (25%). Eleven patients (23%) were treated using osteochondral allografts, while the remaining 37 received autografts. Patients receiving allograft were significantly more likely to be younger (18.3 years vs. 28.6 years,  $p = 0.001$ ) and have smaller chondral lesions (243 mm<sup>2</sup> vs. 434 mm<sup>2</sup>,  $p = 0.01$ ).

### 3.2. Imaging and clinical follow-up

The demographic and surgical characteristics of patients requiring and not requiring reoperation are given in Table 2.

Nine of the 48 (19%) study patients had evidence of fluid imbibition at the bone-cartilage interface of their osteochondral grafts on follow-up MRI scan. Fluid imbibition was present at mean 14.6 months (range: 6–22 months) post-operatively. All nine cases were osteochondral allograft; no patient receiving an autograft had fluid imbibition. The presence of fluid imbibition was not significantly associated with any demographic variable, the anatomic location of the chondral lesion, or the size of the treated lesion (all with  $p > 0.05$ ).

Two of the nine cases (22%) with fluid imbibition ultimately underwent graft revision due to progressive collapse with pain and persistent effusion at mean 26.5 months (range: 20–33 months). Four (45%) underwent arthroscopy with debridement and chondroplasty at mean 20.8 months (range: 10–31 months) after index surgery. Three cases (33%) did not require any further surgery. Only one of the three cases not requiring further surgery had a subsequent MRI performed showing complete resolution of the fluid imbibition (Fig. 2A and B).

### 3.3. Association with reoperation

The overall reoperation rate in the study cohort was 42% (20/48), with 19% (9/48) of patients requiring arthroscopic debridement and chondroplasty, 13% (6/48) requiring revision osteochondral grafting, and 10% (5/48) requiring reoperation for other reasons (manipulation under anesthesia, removal of hardware, etc).

The presence of fluid imbibition was associated with the need for subsequent chondroplasty ( $p = 0.05$ ). No other demographic or surgical factor was significant, including age, sex, race, affected side,

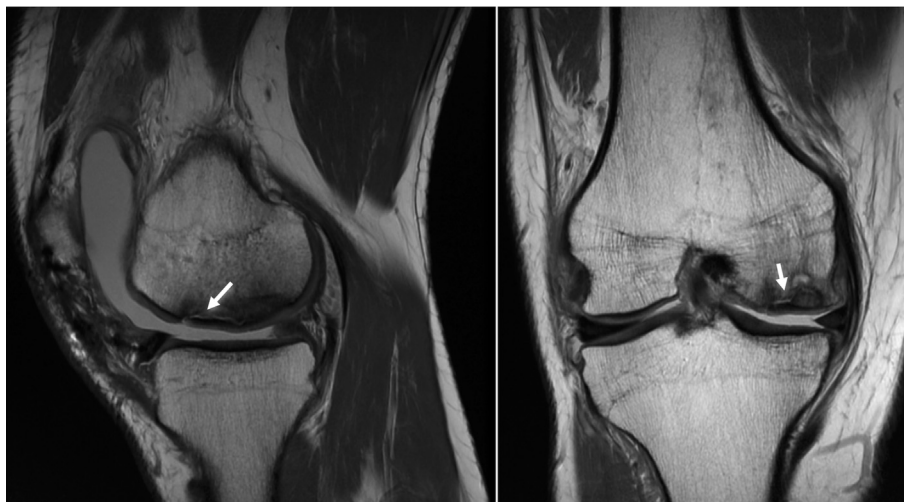

Fig. 1. Example sagittal and coronal proton density MRI showing fluid imbibition beneath the subchondral lamina of an osteochondral allograft.

**Table 1**  
Demographic and injury characteristics of study cohort.

	Whole Cohort (n = 48)	Fluid Imbibition on MRI (n = 9)	No Fluid Imbibition on MRI (n = 39)
Mean Age	26.2 years (range: 13–49 years)	28.4 years (range: 17–49 years)	25.7 years (range: 13–44 years)
Sex			
Male	38 (79%)	8 (89%)	30 (77%)
Female	10 (21%)	1 (11%)	9 (23%)
Race			
Caucasian	43 (90%)	9 (100%)	34 (87%)
Other	5 (10%)	0 (0%)	13 (%)
Side			
Right	23 (48%)	6 (67%)	17 (44%)
Left	25 (52%)	3 (33%)	22 (56%)
Lesion Size	390 mm <sup>2</sup>	556 mm <sup>2</sup>	351 mm <sup>2</sup>
Procedure Type			
Primary	43 (90%)	9 (100%)	34 (87%)
Revision	5 (10%)	0 (0%)	5 (13%)
Graft Type			
Autograft	11 (23%)	9 (100%)	11 (28%)
Allograft	37 (77%)	0 (0%)	28 (72%)
Graft Location			
MFC	17 (35%)	3 (33%)	14 (36%)
LFC	12 (25%)	3 (33%)	9 (23%)
Trochlea	11 (23%)	1 (11%)	10 (26%)
Patella	3 (6%)	1 (11%)	2 (5%)
Multiple	5 (11%)	1 (11%)	4 (10%)
Mean Follow-up	39 months (range: 12–101 months)	39 months (range: 19–72 months)	39 months (range: 12–101 months)

**Table 2**  
Demographic, injury, and radiologic characteristics of patients based on need for reoperation.

	No Reoperation (n = 28)	Arthroscopic Chondroplasty (n = 9)	Graft Revision (n = 6)
Mean Age	26 years (range: 14–44 years)	27.6 years (range: 13–44 years)	23.7 years (range: 15–49 years)
Sex			
Male	24 (86%)	7 (78%)	4 (67%)
Female	4 (14%)	2 (22%)	2 (33%)
Race			
Caucasian	25 (89%)	8 (89%)	6 (100%)
Other	3 (11%)	1 (11%)	0 (0%)
Side			
Right	15 (54%)	5 (56%)	2 (33%)
Left	13 (46%)	4 (44%)	4 (67%)
Mean Lesion Size	391 mm <sup>2</sup>	356 mm <sup>2</sup>	404 mm <sup>2</sup>
Procedure Type			
Primary	24 (86%)	9 (100%)	6 (100%)
Revision	4 (14%)	0 (0%)	0 (0%)
Fluid Imbibition Present?			
Yes	3 (11%)	4 (44%)	2 (33%)
No	25 (89%)	5 (56%)	4 (67%)
Graft Location			
MFC	11 (39%)	2 (22%)	2 (33%)
LFC	6 (21%)	2 (22%)	2 (33%)
Trochlea	8 (29%)	0 (0%)	2 (33%)
Patella	1 (4%)	2 (22%)	0 (0%)
Multiple	2 (7%)	3 (33%)	0 (0%)

primary versus revision procedure, allograft versus autograft, lesion size, or lesion location.

The presence of synovitis was associated with reoperation for any reason ( $p = 0.002$ ). Within the subgroup of cases with fluid imbibition, the presence of synovitis or a joint effusion was not associated with reoperation for chondroplasty/debridement or revision surgery.

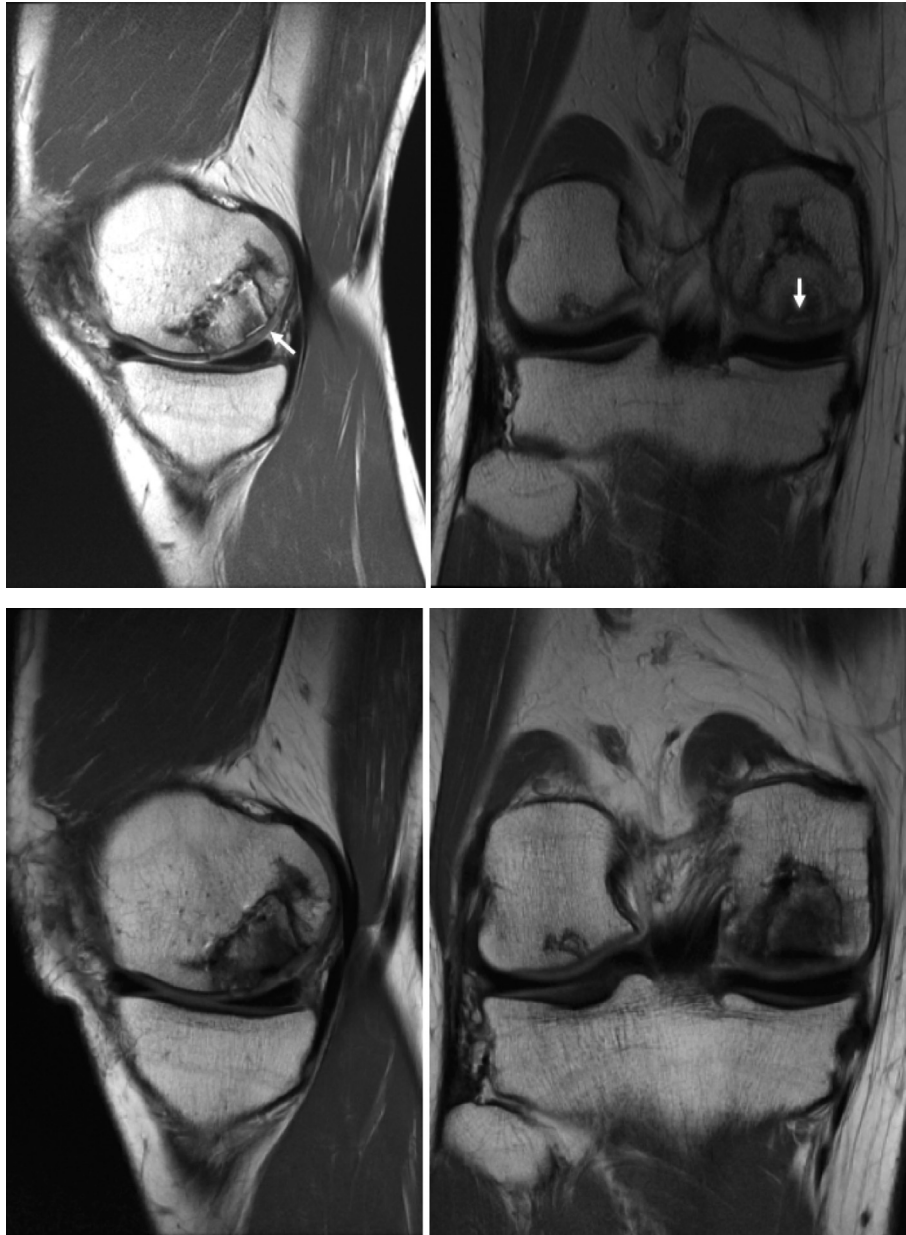#### 4. Discussion

The major finding of this study is that the presence of fluid imbibition on follow-up post-operative MRI is associated with the need for arthroscopic debridement and chondroplasty. Fluid imbibition was present in nearly 20% of cases, of which two (22%) ultimately required revision procedure. The remaining seven (78%)

did not. In one case, we were able to document resolution of fluid imbibition despite no further surgical treatment.

Osteochondral grafting (autograft or allograft) has proven to be a reliable treatment for symptomatic chondral lesions of the distal femur. Published series report consistently good short-, mid-, and long-term results in a variety of patient subpopulations.<sup>7–9</sup> Reoperation, however, is quite common, with many patients requiring manipulation under anesthesia for persistent knee stiffness, arthroscopic synovectomy for persistent effusion and pain, or arthroscopic chondroplasty for delaminating cartilage from the graft.<sup>10,11</sup> The reoperation rate has been reported as high as 37%,<sup>4</sup> which is similar to our cohort where 42% underwent reoperation and 32% required reoperation to address complications related to the graft.

MRI is a commonly used tool for assessing the health and



**Fig. 2.** A Sagittal and coronal proton density MRI scans of a patient 10 months after osteochondral allografting showing fluid imbibition at the bone-cartilage interface of the graft (white arrows). B Repeat MRI 22 months after surgery showing complete resolution of fluid imbibition.

integrity of osteochondral grafts post-operatively, either through routine surveillance studies performed at specified intervals after surgery, or in response to clinical complaints in the post-operative period. The MRI appearance of osteochondral grafts has been relatively well-described, with autograft tissue showing bony edema up to one year after surgery in half of patients and progressive fill of fissures at the graft-host interface, and a longer period of bony edema with development of an advancing front as graft bone is incorporated.<sup>12</sup> Additionally, complications such as bony collapse, host-immune reaction, and avascular necrosis of implanted grafts are readily identifiable on MRI, and provide diagnostic value to the surgeon during clinical decision-making. Several MRI-based scoring systems are commonly used in the cartilage repair literature to report the health of the graft based on the appearance of the subchondral bone, subchondral lamina, incorporation of transplanted tissue, and surrounding structures

(MOCART, CROAKS, OCAMRISS).<sup>6,13,14</sup>

Less clear, however, is the relationship between post-operative imaging findings and clinical outcomes. Meric et al. (2015) reported a correlation between the cartilage section of the OCAMRISS score as well as the total score with post-operative IKDC function scores.<sup>15</sup> They also identified a correlation between individual COOS subscores and the ancillary section scores of the OCAMRISS. They did not, however, find any relationship between the subchondral bone feature scores of OCAMRISS and any clinical outcome measure. Krusche-Mandl et al. (2012) found a correlation between Lysholm scores and T2-mapping of transplanted grafts, but no direct correlation between MOCART score and clinical outcome.<sup>16</sup> In contrast, Maracacci et al. (2007) identified a correlation between the IKDC and most features of the MOCART score including defect filling, subchondral bone changes, and the presence of a joint effusion.<sup>17</sup> Kokkinos's et al. (2008) found no

relationship between Lysholm score and subchondral lamina irregularity, subchondral bone edema, or articular step-off.<sup>18</sup> The apparent lack of correlation between post-operative imaging findings and clinical outcome has led some to question its utility as a routine surveillance tool.

In the present study, we sought to correlate an imaging finding not typically captured by conventional MRI scoring systems with the clinical success of osteochondral grafts. We have noted relatively high rates of fluid imbibition signal on post-operative MRI. These findings, often interpreted by our radiology colleagues as “impending chondral delamination” of transplanted grafts, raise significant dilemmas in the clinical setting. It has been unclear to us whether such a finding should prompt early arthroscopic chondroplasty to prevent propagation of the delamination, counseling of the patient on a likely need for reoperation in the future, or watchful waiting with intervention only if the patient develops clinical symptoms. We have elected to proceed with the last option, making clinical decisions solely on the basis of patient symptoms and physical examination.

The results of our study seem to support our course of action. Fluid imbibition is associated with the need for arthroscopic debridement and chondroplasty. We did not find an association between fluid imbibition and eventual graft revision, but our cohort is likely too small to detect such an association given our overall low revision rate. Nearly half of the patients with a fluid imbibition signal ultimately underwent an arthroscopic chondroplasty, but none of those patients progressed to graft failure/revision. MRI follow-up after chondroplasty did not show further propagation of the fluid signal or progressive chondral delamination. Additionally, one-third of the patients with such a signal required no further surgery, and one of those patients showed resolution of the fluid signal on follow-up MRI.

Synovitis was associated with need for reoperation, though a joint effusion was not. We interpret this finding as indicative of an inhospitable joint environment that may lead to a need for further surgery. The expanding field of biologic therapies may be useful in altering this abnormal joint homeostasis, and we will frequently use platelet-rich plasma injections post-operatively in an attempt to control synovitic knees. Research in this field is ongoing and has shown promise.<sup>19,20</sup>

There are several limitations to this study. First, by only including patients with at least two post-operative MRIs, we reduced our study cohort to only about one-third of the patients receiving an osteochondral graft who were enrolled in our registry over the specified time period. With a larger cohort, we might have potentially identified a correlation between fluid imbibition and eventual failure. However, intuitively we believe this is unlikely. Patients undergoing multiple MRI scans post-operatively are more likely to be experiencing clinical symptoms, and therefore more likely to require secondary procedures. We suspect, but cannot prove, that the remaining patients with one or zero post-operative MRIs are more likely to be clinical “successes” who chose not to keep routine annual follow-ups in our clinic. This rationale is supported by the relatively higher failure rate we found in this cohort, versus other populations we have reported from our registry.

Second, while we have described our criteria for the identification of fluid imbibition on MRI, this definition is novel and has not been previously described in the orthopaedic or radiology literature that we are aware of. It is possible that the findings we report here are indicative of some other process other than fluid imbibition, despite its characteristic appearance. Further review and possible external validation of these findings would be helpful to support our conclusions.

Finally, because this was a retrospective review of prospectively collected data, there are a variety of potential sources of bias

inherent in our conclusions. The lack of uniform follow-up, varying time points for post-operative MRI scans, and lack of validated patient-reported outcome scores all limiting the strength of our conclusions, though we do not feel that these limitations refute our findings.

## 5. Conclusions

Our data suggests an association between the presence of a fluid imbibition signal on post-operative MRI following osteochondral grafting and the need for eventual arthroscopic chondroplasty. This signal was only present in osteochondral allografts, and did not appear to be associated with graft failure or need for revision procedures or arthroplasty. This information may prove useful when evaluating post-operative MRI scans following osteochondral grafting, and counseling patients on the potential consequences of their imaging findings.

## Declaration of conflicting interest

The Authors declare that there is no conflict of interest.

## Acknowledgements

The authors wish to acknowledge and thank Dr. Scott Rodeo, Dr. Russell Warren, and Dr. Frank Cordasco for their assistance with this study.

## Appendix A. Supplementary data

Supplementary data related to this article can be found at <https://doi.org/10.1016/j.jcot.2019.03.023>.

## References

1. Familiari F, Cinque ME, Chahla J, et al. Clinical outcomes and failure rates of osteochondral allograft transplantation in the knee: a systematic review. *Am J Sports Med.* 2017; 363546517732531.
2. McCarthy MA, Meyer MA, Weber AE, et al. Can competitive athletes return to high-level play after osteochondral allograft transplantation of the knee? *Arthroscopy.* 2017;33:1712–1717.
3. Campbell AB, Pineda M, Harris JD, Flanigan DC. Return to sport after articular cartilage repair in athletes' knees: a systematic review. *Arthroscopy.* 2016;32:651–668 e651.
4. Frank RM, Lee S, Levy D, et al. Osteochondral allograft transplantation of the knee: analysis of failures at 5 years. *Am J Sports Med.* 2017;45:864–874.
5. Welsch GH, Zak L, Mamisch TC, et al. Advanced morphological 3D magnetic resonance observation of cartilage repair tissue (MOCART) scoring using a new isotropic 3D proton-density, turbo spin echo sequence with variable flip angle distribution (PD-SPACE) compared to an isotropic 3D steady-state free precession sequence (True-FISP) and standard 2D sequences. *J Magn Reson Imaging.* 2011;33:180–188.
6. Chang EY, Pallante-Kichura AL, Bae WC, et al. Development of a comprehensive osteochondral allograft MRI scoring system (OCAMRISS) with histopathologic, micro-computed tomography, and biomechanical validation. *Cartilage.* 2014;5:16–27.
7. Aubin PP, Cheah HK, Davis AM, Gross AE. Long-term followup of fresh femoral osteochondral allografts for posttraumatic knee defects. *Clin Orthop Relat Res.* 2001;S318–S327.
8. Emmerson BC, Gortz S, Jamali AA, Chung C, Amiel D, Bugbee WD. Fresh osteochondral allografting in the treatment of osteochondritis dissecans of the femoral condyle. *Am J Sports Med.* 2007;35:907–914.
9. Raz G, Safir OA, Backstein DJ, Lee PT, Gross AE. Distal femoral fresh osteochondral allografts: follow-up at a mean of twenty-two years. *J Bone Joint Surg Am.* 2014;96:1101–1107.
10. Cameron JJ, Pulido PA, McCauley JC, Bugbee WD. Osteochondral allograft transplantation of the femoral trochlea. *Am J Sports Med.* 2016;44:633–638.
11. Sadr KN, Pulido PA, McCauley JC, Bugbee WD. Osteochondral allograft transplantation in patients with osteochondritis dissecans of the knee. *Am J Sports Med.* 2016;44:2870–2875.
12. Hayashi D, Li X, Murakami AM, Roemer FW, Trattng S, Guermazi A. *Understanding Magnetic Resonance Imaging of Knee Cartilage Repair: A Focus on Clinical Relevance.* *Cartilage.* 2017; 1947603517710309.
13. Welsch GH, Zak L, Mamisch TC, Resinger C, Marlovits S, Trattng S. Three-

- dimensional magnetic resonance observation of cartilage repair tissue (MOCART) score assessed with an isotropic three-dimensional true fast imaging with steady-state precession sequence at 3.0 Tesla. *Investig Radiol.* 2009;44:603–612.
14. Hunter DJ, Guermazi A, Lo GH, et al. Evolution of semi-quantitative whole joint assessment of knee OA: MOAKS (MRI Osteoarthritis Knee Score). *Osteoarthritis Cartilage.* 2011;19:990–1002.
  15. Meric G, Gracitelli GC, McCauley JC, et al. Osteochondral allograft MRI scoring system (OCAMRISS) in the knee: interobserver agreement and clinical application. *Cartilage.* 2015;6:142–149.
  16. Krusche-Mandl I, Schmitt B, Zak L, et al. Long-term results 8 years after autologous osteochondral transplantation: 7 T gagCEST and sodium magnetic resonance imaging with morphological and clinical correlation. *Osteoarthritis Cartilage.* 2012;20:357–363.
  17. Marcacci M, Kon E, Delcogliano M, Filardo G, Busacca M, Zaffagnini S. Arthroscopic autologous osteochondral grafting for cartilage defects of the knee: prospective study results at a minimum 7-year follow-up. *Am J Sports Med.* 2007;35:2014–2021.
  18. Kokkinakis M, Kafchitsas K, Rajeev A, Mortier J. Is MRI useful in the early follow-up after autologous osteochondral transplantation? *Acta Orthop Belg.* 2008;74:636–642.
  19. Caviglia H, Landro ME, Daffuncho C, et al. Platelet rich plasma for chronic synovitis treatment in patients with haemophilia. *Hemophilia.* 2017;23:613–619.
  20. Kanwat H, Singh DM, Kumar CD, Alka B, Biman S, Aman H. The effect of intra-articular allogenic platelet rich plasma in Dunkin-Hartley Guinea pig model of knee osteoarthritis. *Muscles Ligaments Tendons J.* 2017;7:426–434.