

UC San Diego

UC San Diego Previously Published Works

Title

Oblique anterior column realignment with a mini-open posterior column osteotomy for minimally invasive adult spinal deformity correction: illustrative case.

Permalink

<https://escholarship.org/uc/item/04j7h59n>

Authors

Pennington, Zach

Brown, Nolan

Pishva, Seyedamirhossein

et al.

Publication Date

2024-03-11

DOI

10.3171/CASE23680

Peer reviewed

Oblique anterior column realignment with a mini-open posterior column osteotomy for minimally invasive adult spinal deformity correction: illustrative case

Zach Pennington, MD,¹ Nolan J. Brown, MBA,² Seyedamirhossein Pishva, BS,³ Hernán F. J. González, MD, PhD,⁴ and Martin H. Pham, MD⁴

¹Department of Neurologic Surgery, Mayo Clinic, Rochester, Minnesota; ²Department of Neurosurgery, University of California-Irvine, Orange, California; ³Kansas City University College of Medicine, Kansas City, Missouri; and ⁴Department of Neurosurgery, University of California San Diego School of Medicine, San Diego, California

BACKGROUND Adult spinal deformity (ASD) occurs from progressive anterior column collapse due to disc space desiccation, compression fractures, and autofusion across disc spaces. Anterior column realignment (ACR) is increasingly recognized as a powerful tool to address ASD by progressively lengthening the anterior column through the release of the anterior longitudinal ligament during lateral interbody approaches. Here, we describe the application of minimally invasive ACR through an oblique antepsoas corridor for deformity correction in a patient with adult degenerative scoliosis and significant sagittal imbalance.

OBSERVATIONS A 65-year-old female with a prior history of L4–5 transforaminal lumbar interbody fusion and morbid obesity presented with refractory, severe low-back and lower-extremity pain. Preoperative radiographs showed significant sagittal imbalance. Computed tomography showed a healed L4–5 fusion and a vacuum disc at L3–4 and L5–S1, whereas magnetic resonance imaging was notable for central canal stenosis at L3–4. The patient was treated with a first-stage L5–S1 lateral anterior lumbar interbody fusion with oblique L2–4 ACR. The second-stage posterior approach consisted of a robot-guided minimally invasive T10–iliac posterior instrumented fusion with a mini-open L2–4 posterior column osteotomy (PCO). Postoperative radiographs showed the restoration of her sagittal balance. There were no complications.

LESSONS Oblique ACR is a powerful minimally invasive tool for sagittal plane correction. When combined with a mini-open PCO, substantial segmental lordosis can be achieved while eliminating the need for multilevel PCO or invasive three-column osteotomies.

<https://thejns.org/doi/abs/10.3171/CASE23680>

KEYWORDS adult spinal deformity; adult degenerative scoliosis; sagittal imbalance; anterior column realignment; oblique; posterior column osteotomy; ALIF; neurosurgery

Adult spinal deformity (ASD) is a degenerative disease characterized by progressive sagittal imbalance and/or kyphoscoliotic deformity. It affects up to two-thirds of patients older than 60 years of age and can have a significant negative impact on quality of life (QOL),^{1–5} with Bess et al.⁶ finding that it negatively impacts QOL scores in a manner similar to malignancy (cancer) or having limited use of the arms or legs. Although not all patients require surgical intervention, with the continued aging of the United States population,

the absolute number of patients with indications for operative management is likely to increase.^{7,8}

As a degenerative disease, idiopathic ASD is characterized by progressive malalignment due to sequential disc space collapse, often accompanied by compression deformities of the vertebral bodies, resulting in an asymmetrical shortening of the anterior column relative to the posterior column.⁷ Autofusion across the disc spaces and asymmetrical disc height loss can lead to coronal as well as

ABBREVIATIONS ACR = anterior column realignment; ALIF = anterior lumbar interbody fusion; ALL = anterior longitudinal ligament; ASD = adult spinal deformity; BMI = body mass index; CT = computed tomography; LL = lumbar lordosis; LLIF = lateral lumbar interbody fusion; MISDEF2 = minimally invasive spinal deformity surgery algorithm; MRI = magnetic resonance imaging; OLIF = oblique lumbar interbody fusion; PCO = posterior column osteotomy; PI = pelvic incidence; POD = postoperative day; PSO = pedicle subtraction osteotomy; PT = pelvic tilt; QOL = quality of life; SVA = sagittal vertical axis.

INCLUDE WHEN CITING Published March 11, 2024; DOI: 10.3171/CASE23680.

SUBMITTED November 19, 2023. **ACCEPTED** February 6, 2024.

© 2024 The authors, CC BY-NC-ND 4.0 (<http://creativecommons.org/licenses/by-nc-nd/4.0/>)

sagittal malalignment.^{9,10} Surgical correction is technically difficult and has conventionally focused on invasive, open posterior-only approaches with multilevel osteotomies, which often have a morbid complication profile.^{11,12} This risk profile is further exacerbated in the ASD population, which commonly has extensive health comorbidities including diabetes, frailty, obesity, osteoporosis, and limited mobility in the setting of their disability.^{13–15} One increasingly attractive option for these patients is the use of anterior column realignment (ACR) with a minimally invasive approach. This approach has lower associated trauma to the paraspinal musculature¹⁶ and attempts to physiologically reverse the deformity through selective anterior column elongation. Although purely minimally invasive approaches may not be feasible for rigid deformities, they can be preferable in patients with flexible or smaller deformities, especially in light of advances in preoperative planning software.^{17–20}

ACR can be achieved through an antepsoas/oblique lumbar interbody fusion (OLIF) or a lateral lumbar interbody fusion (LLIF) approach, which allow for the placement of lordotic, large-footprint implants after concomitant release of the anterior longitudinal ligament (ALL). Even greater sagittal realignment can be achieved with selective osteotomies at the ACR levels for posterior column shortening.²¹ In the present study, we present the case of a 65-year-old female with a prior L4–5 instrumented fusion and significant sagittal imbalance secondary to flat back deformity. Using a combination of oblique ACR and selective posterior column osteotomy (PCO), we illustrate successful grade 2 ACR for correction of the deformity using a circumferential minimally invasive technique, emphasizing the benefits of this approach and the evolving importance of preoperative planning software in modern ASD surgery.

Illustrative Case

History and Examination

A 65-year-old female with a body mass index (BMI) of 38.0 kg/m² and prior L4–5 instrumented fusion presented with severe, progressive low-back and leg pain that had chronically reduced her QOL and limited her ability to engage in activities of daily living. The patient's history was notable for morbid obesity and a previous gastric bypass. Despite more than 1 year of attempted optimization of lifestyle changes

and dietary modification, she continued to have great difficulty with her obesity. Additionally, the patient's low-back pain was refractory to 6 months of physical therapy and epidural steroid injections. She had no prior history of smoking or diabetes. Dual energy x-ray absorptiometry noted a T-score of -1.2, Z-score of -0.1, and bone mineral density of 0.870 g/cm². At baseline, her neurological examination showed 5/5 strength in the bilateral upper extremities and 5/5 strength in the bilateral lower extremities except for the right tibialis anterior/extensor hallucis longus, which showed 3/5 strength. Otherwise, the patient's sensation was full and intact throughout, and she was not hyperreflexic. She stood in a notable forward posture requiring the use of a cane, and she had a significant residual pannus related to her high BMI.

Standing scoliosis radiographs were obtained and demonstrated significant sagittal imbalance with a sagittal vertical axis (SVA) of 20.4 cm, pelvic incidence (PI) of 79°, lumbar lordosis (LL) 27°, PI-LL mismatch of 52°, and pelvic tilt (PT) of 26° (Fig. 1). According to the minimally invasive spinal deformity surgery (MISDEF2) algorithm, the patient was classified as class III and would require advanced techniques if a minimally invasive surgical approach was pursued.²⁰ Computed tomography (CT) confirmed prior L4–5 fusion with residual spondylolisthesis and segmental kyphosis. It also demonstrated a vacuum disc at the L3–4 and L5–S1 interbody spaces. Magnetic resonance imaging (MRI) demonstrated pronounced central stenosis at L3–4 with favorable great vessel anatomy at L5–S1.

Stage 1 Surgery

The decision was made to perform this surgery in two stages because a long anesthesia time was anticipated and staging the surgery would enable assessment of potential neurological improvements and/or deficits after interbody placement. The patient was positioned on a Jackson table in the right lateral decubitus position (left side up). A lateral L5–S1 anterior lumbar interbody fusion (ALIF) was performed first, followed by the L3–4 and L2–3 oblique ACR (Fig. 2).

Oblique ACR Technique

An oblique antepsoas approach for performing ACR allows for direct visualization of the ALL. Once a discectomy has been performed, the retractor is moved further anterior, and the longitudinal

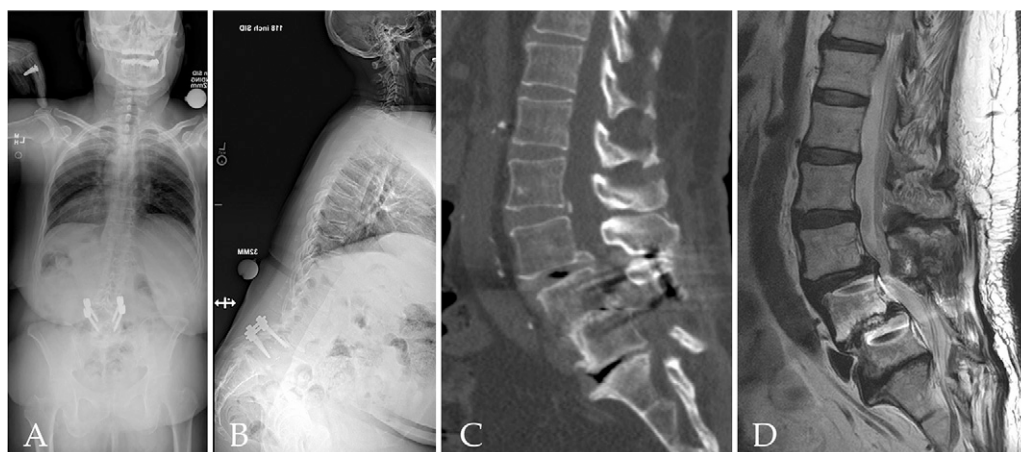

FIG. 1. Preoperative standing scoliosis radiographs, anteroposterior (A) and lateral (B) views, showing significant sagittal malalignment. Supine CT (C) and MRI (D) demonstrating a healed L4–5 fusion in slight kyphosis, along with L3–4 central stenosis and vacuum disc phenomenon at L3–4 and L5–S1.

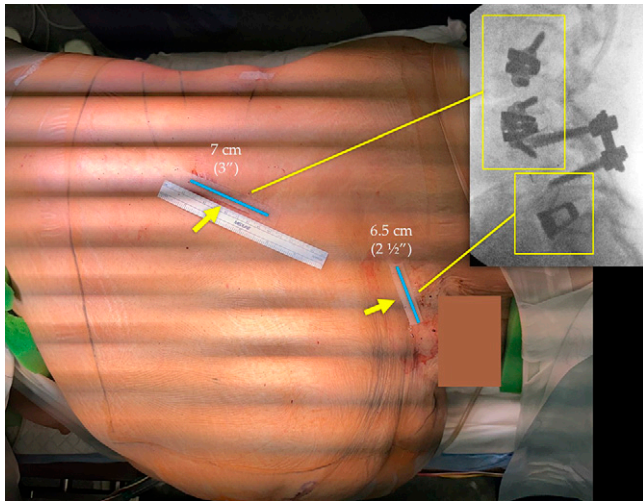


FIG. 2. Intraoperative image after the first stage showing the two minimally invasive incisions that allowed for the oblique ACR at L2–4 (7 cm) and lateral ALIF at L5–S1 (6.5 cm).

sectioned with a sharp disc knife, and the remaining soft tissue is removed with Kerrison and pituitary rongeurs. Serial trials and an expandable trial are then used to gently tear the contralateral ALL for full anterior release of the interspace. We use an expandable hyperlordotic cage to dial that is fixed into position and expanded to size and subsequently backfilled with bone graft.

Stage 2 Surgery

The patient was positioned prone on the Jackson table for robot-assisted minimally invasive posterior pedicle screw fixation and rod placement. The preoperative plan included minimally invasive T10–ilium posterior spinal fusion with mini-open L2–4 PCOs without any planned removal of her prior L4–5 transforaminal lumbar interbody fusion implants (Fig. 4). Screws were placed with robotic assistance, followed by a mini-open PCO at L2–4 and subsequent placement of a patient-specific precontoured rod. This was serially reduced into place, and final intraoperative radiographs showed appropriate realignment and achievement of surgical goals.

Postoperative Course

There were no intraoperative or postoperative complications following either stage of the surgery. Stage 2 was performed on postoperative day (POD) 2, and the patient was discharged to an acute rehabilitation facility on POD 5, 3 days after her second stage. She did not require blood transfusions or intensive care unit level of

fibers of the ALL are subsequently identified; fluoroscopy can be helpful to confirm exposure and visualization of the ipsilateral third to half of the anterior disc space (Fig. 3). This is then directly

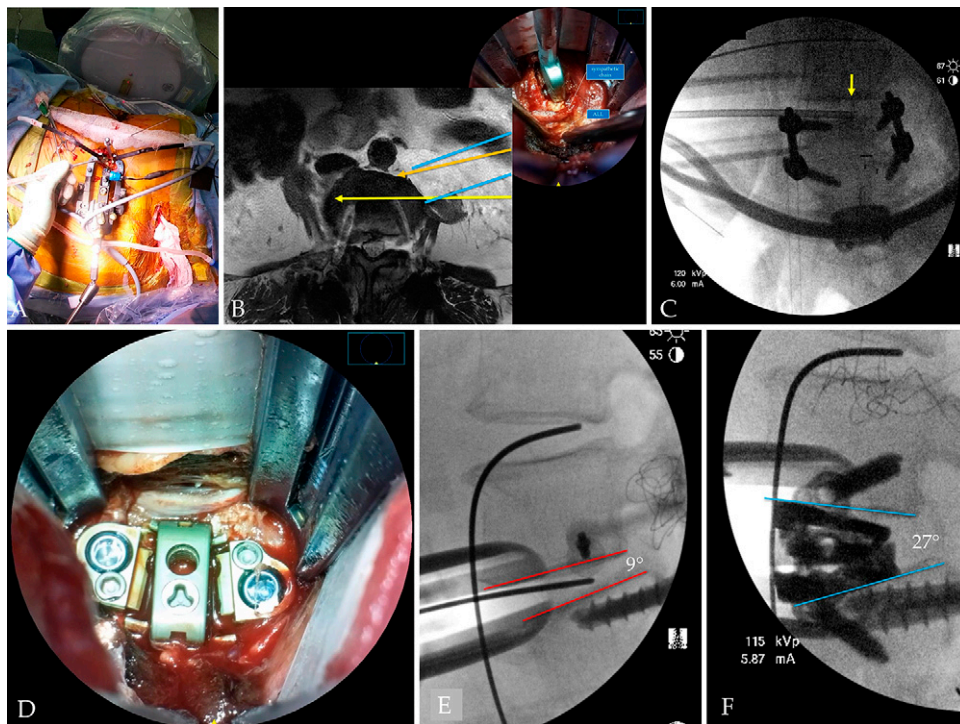


FIG. 3. Shoulder view (A) of the operative field showing the minimally invasive retractor at the L3–4 level with a trial inside the disc space. Axial MRI (B) of L3–4 with a schematic showing the antepsoas retractor placement (blue lines), trial (yellow line), and visualization of the ALL (orange line). Retractor camera view (inset B) showing the trial in the disc space with the labeled sympathetic chain and ALL. Intraoperative fluoroscopy (C) showing a suction tip at the midline (yellow arrow) that is anterior to the disc space and confirms visualization all the way to the middle ALL. Retractor camera view (D) of a hyperlordotic expandable cage at L3–4. Intraoperative fluoroscopy before (E) and after (F) placement of the hyperlordotic expandable cage after oblique ALL release, showing 18° of segmental correction.

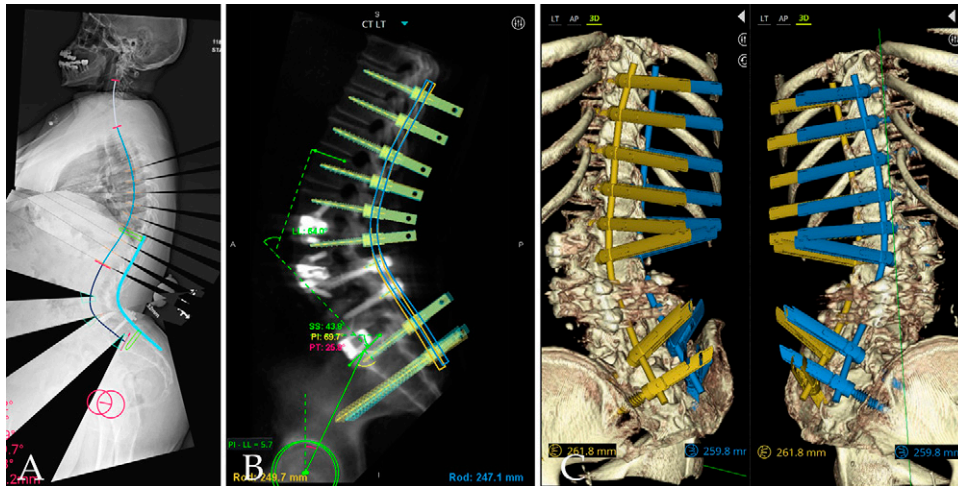


FIG. 4. Predictive analytics (A) simulating a lateral L5–S1 ALIF and L2–4 ACR. Robotic software planning showing simulated screws and L2–4 PCO correction (B) with three-dimensional reconstructions (C) to plan and avoid tower collisions during minimally invasive placement of pedicle screws.

care. Standing scoliosis radiographs were obtained and demonstrated significant improvement in sagittal balance (Fig. 5). Postoperative SVA improved to 5.5 cm, LL increased to 78°, PI-LL mismatch decreased to 1°, and PT decreased to 16°. At the 4-month follow-up, she reported a significant reduction in pain, a feeling that she is standing straighter with increased standing tolerance, and an ability to walk unassisted.

Patient Informed Consent

The necessary patient informed consent was obtained in this study.

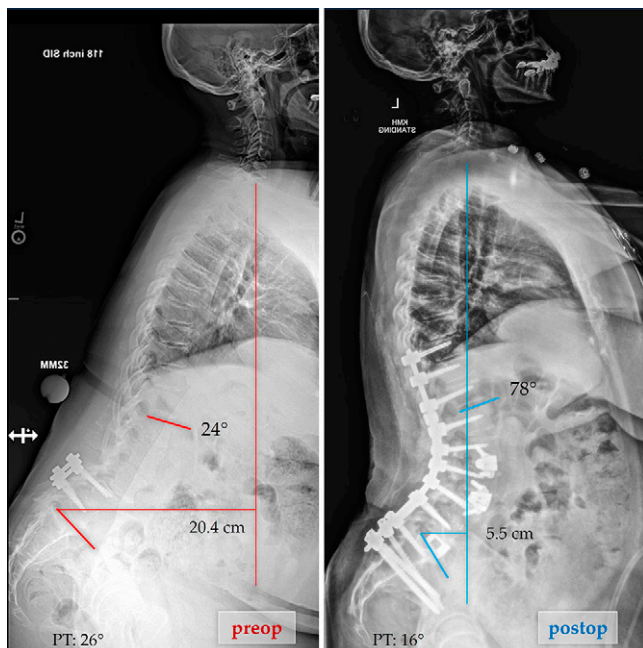


FIG. 5. Preoperative (left) and postoperative (right) standing radiographs showing correction of the patient's sagittal malalignment.

Discussion

Observations

In the present case, achieving realignment hinged on successful correction of the patient's flat back deformity in the setting of a high sacral slope and prior L4–5 fusion. Matching a patient's LL to their PI—the natural anatomical relationship between the sacrum and bony pelvis—has been held to be key to effective deformity correction.²² This has led to the argument that sagittal plane correction should be maximized at the distal end of the construct, which in prior fusions will involve a pedicle subtraction osteotomy (PSO) at L4 or L5. This is consistent with prior work that has observed approximately two-thirds of LL cases to occur between the L3–4 and L5–S1 interspaces with a lordosis distribution index of 0.6 to 0.7.²³

According to the Roussouly classification, our patient displayed type 4 lordosis, having a higher sacral slope; consequently, the natural LL apex would be expected to fall at the level of L3.²⁴ The combination of an L4 PSO with the L5–S1 lateral ALIF was considered; however, it was believed that the PSO would carry with it significant morbidity especially in a higher risk patient such as ours. To this end, a recent series on 312 patients published by Lee et al.²⁵ noted the 2-year complication rate to exceed 60% for PSO. By comparison, minimally invasive deformity correction techniques have been correlated with lower perioperative complication rates and thus may be preferable in high-risk patients such as the present case, and we proceeded with this strategy.²⁶ We have included salient studies that contributed to this thought process in Supplementary Table 1.

Advances in minimally invasive surgical technology, including preoperative planning software,¹⁰ spinal robotics, percutaneous instrumentation systems,¹⁹ and anterolateral/lateral approaches for interbody placement have significantly broadened the indications for minimally invasive approaches in ASD surgery. The present case helps to illustrate this by highlighting the application of a grade 2 ACR through an oblique antepsoas approach (OLIF).

Several groups have described the utilization of multilevel ACR for sagittal plane deformity. Experiences such as these build on prior surgical paradigms, notably the MISDEF algorithm,⁴ leading to

the development of the MISDEF2 algorithm, which recommends the use of minimally invasive corrective techniques, including ACR for the correction of nonrigid deformities.²⁰ Contemporaneous to this, Godzik et al.⁸ overviewed the application of conventional ACR in modern deformity surgery. They noted that in the absence of any PCOs, ACR can produce 10° of segmental lordosis; with the addition of a PCO, ACR could provide 73% more lordosis. Another biomechanical study by Godzik et al.²⁷ sought to compare various fixation strategies in ACR and whether lateral screw fixation with one versus two screws would affect lordosis correction if posterior osteotomies were subsequently performed. They found that lateral two-screw fixation constructs were more stable in flexion, extension, and axial rotation and, more importantly, did not differ from one-screw fixation constructs in radiographic correction or compressive forces to close subsequent grade 1 or grade 2 posterior osteotomies. For these reasons, we used two-screw fixation laterally for our ACR levels, which still allowed a regional increase of 16° across L2–4 after our PCO (32° to 48°). Larger multicenter experiences, including that of Chan et al.,²⁸ have similarly reported good radiographic results after minimally invasive surgical correction of ASD. Comparing circumferential minimally invasive to hybrid open–minimally invasive management, these authors noted similar improvements in sagittal balance and PI-LL mismatch at the ≥2-year follow-up. Oswestry Disability Index outcomes and back pain scores at the 2-year follow-up both favored the circumferential approach, which also had lower mean intraoperative blood loss, shorter operative times, and fewer complications. The rates of proximal junctional kyphosis were also lower in the circumferential group, though at the expense of higher rates of radiographic nonunion.

In the present case, we describe the application of an oblique antepsoas approach for ACR compared to the transpsoas approach described by prior groups. This oblique approach offers the advantages of direct en face ALL visualization, and it avoids traversing the psoas muscle and lumbar plexus contained therein. Injury to the lumbar plexus along with psoas weakness is a relatively common complication of the transpsoas approach, with psoas weakness occurring in approximately 26% of patients.²⁹ Although most psoas weakness is transient³⁰ and likely related to muscle trauma during dilator passage, permanent motor deficits are still noted in at least 1% of patients in modern series.³¹ By avoiding the psoas, the oblique ACR minimizes the risk of motor injury. Park et al.³² previously described the application of OLIF for severe sagittal plane deformity correction with successful realignment at 2-year follow-up. In previous descriptions of the OLIF for severe sagittal plane deformity correction, authors have consistently touted the potential increased safety of the oblique approach to ACR compared to the conventional LLIF approach because of the ability to directly visualize the ALL and great vessels.

Although the present report highlights the potential power of ACR for sagittal plane correction, it is limited. The follow-up of our patient was 4 months at the time of publication, and longer follow-up is merited to determine the long-term efficacy of this approach especially as it applies to proximal junctional kyphosis and pseudarthrosis, which are still known issues for minimally invasive surgery. There are also still limitations within the preoperative software predictions for interbody correction; the decision to proceed with PCOs was made because ideal lordosis had not been achieved with the first stage, which had otherwise been predicted in a purely simulated environment. Ultimately, although this approach was

shown to be safe and successful in the short term for this selected patient, it remains unknown whether wider adoption of this technique would be beneficial for the broader ASD population at large, which is heterogeneous and complex.

Lessons

ACR attempts to physiologically realign the spine through selective anterior column lengthening through the release of the ALL. The oblique antepsoas corridor allows for direct visualization of this release and serves as a natural space familiar to surgeons opting to perform OLIF. For patients who are unlikely to tolerate open deformity correction without significant morbidity, minimally invasive oblique ACR can provide significant spinal realignment while maintaining a low periprocedural morbidity.

References

1. Smith JS, Singh M, Klineberg E, et al. Surgical treatment of pathological loss of lumbar lordosis (flatback) in patients with normal sagittal vertical axis achieves similar clinical improvement as surgical treatment of elevated sagittal vertical axis: clinical article. *J Neurosurg Spine*. 2014;21(2):160–170.
2. Baaj AA, Mummaneni PV, Uribe JS, Vaccaro AR, Greenberg MS, eds. *Handbook of Spine Surgery*. Georg Thieme Verlag; 2016.
3. Mummaneni PV, Hussain I, Shaffrey CI, et al. The minimally invasive interbody selection algorithm for spinal deformity. *J Neurosurg Spine*. 2021;34(5):741–748.
4. Mummaneni PV, Shaffrey CI, Lenke LG, et al. The minimally invasive spinal deformity surgery algorithm: a reproducible rational framework for decision making in minimally invasive spinal deformity surgery. *Neurosurg Focus*. 2014;36(5):E6.
5. Schwab F, Dubey A, Gamez L, et al. Adult scoliosis: prevalence, SF-36, and nutritional parameters in an elderly volunteer population. *Spine (Phila Pa 1976)*. 2005;30(9):1082–1085.
6. Bess S, Line B, Fu KM, et al. The health impact of symptomatic adult spinal deformity: comparison of deformity types to United States population norms and chronic diseases. *Spine (Phila Pa 1976)*. 2016;41(3):224–233.
7. Diebo BG, Shah NV, Boachie-Adjei O, et al. Adult spinal deformity. *Lancet*. 2019;394(10193):160–172.
8. Godzik J, Pereira BA, Hemphill C, et al. Minimally invasive anterior longitudinal ligament release for anterior column realignment. *Global Spine J*. 2020;10(2 suppl):101S–110S.
9. Chen JW, Martini M, Pennington Z, et al. Characterizing the current clinical trial landscape in spinal deformity: A retrospective analysis of trends in the Clinicaltrials.gov registry. *World Neurosurg*. 2023;174:e92–e102.
10. Pennington Z, Brown NJ, Quadri S, Pishva S, Kuo CC, Pham MH. Robotics planning in minimally invasive surgery for adult degenerative scoliosis: illustrative case. *J Neurosurg Case Lessons*. 2023;5(10):CASE22520.
11. Deukmedjian AR, Le TV, Baaj AA, Dakwar E, Smith DA, Uribe JS. Anterior longitudinal ligament release using the minimally invasive lateral retroperitoneal transpsoas approach: a cadaveric feasibility study and report of 4 clinical cases. *J Neurosurg Spine*. 2012;17(6):530–539.
12. Smith JS, Saulle D, Chen CJ, et al. Rates and causes of mortality associated with spine surgery based on 108,419 procedures: a review of the Scoliosis Research Society Morbidity and Mortality Database. *Spine (Phila Pa 1976)*. 2012;37(23):1975–1982.
13. Bradford DS, Tay BK, Hu SS. Adult scoliosis: surgical indications, operative management, complications, and outcomes. *Spine (Phila Pa 1976)*. 1999;24(24):2617–2629.

14. Bridwell KH, Lewis SJ, Edwards C, et al. Complications and outcomes of pedicle subtraction osteotomies for fixed sagittal imbalance. *Spine (Phila Pa 1976)*. 2003;28(18):2093–2101.
15. Park P, Fu KM, Mummaneni PV, et al. The impact of age on surgical goals for spinopelvic alignment in minimally invasive surgery for adult spinal deformity. *J Neurosurg Spine*. 2018;29(5):560–564.
16. Srinivasan ES, Wang TY, Rapoport A, et al. Minimally invasive lateral retroperitoneal transpsoas approach for lumbar corpectomy and fusion with posterior instrumentation. *Neurosurg Focus Video*. 2022;7(1):V7.
17. Shahrestani S, Ton A, Brown NJ, et al. Radiographic outcomes following ACDF with hyperlordotic implants to achieve cervical anterior column realignment. *World Neurosurg*. 2023;174:e1–e7.
18. Gendreau JL, Nguyen A, Brown NJ, et al. External validation of the Global Alignment and Proportion score as prognostic tool for corrective surgery in adult spinal deformity: A systematic review and meta-analysis. *World Neurosurg*. 2023;177:e600–e612.
19. Brown NJ, Pennington Z, Kuo CC, et al. Retrospective single-surgeon study of prone versus lateral robotic pedicle screw placement: a CT-based assessment of accuracy. *J Neurosurg Spine*. 2023;39(4):490–497.
20. Mummaneni PV, Park P, Shaffrey CI, et al. The MISDEF2 algorithm: an updated algorithm for patient selection in minimally invasive deformity surgery. *J Neurosurg Spine*. 2019;32(2):221–228.
21. Uribe JS, Schwab F, Mundis GM, et al. The comprehensive anatomical spinal osteotomy and anterior column realignment classification. *J Neurosurg Spine*. 2018;29(5):565–575.
22. Schwab F, Lafage V, Patel A, Farcy JP. Sagittal plane considerations and the pelvis in the adult patient. *Spine (Phila Pa 1976)*. 2009;34(17):1828–1833.
23. Yilgor C, Sogunmez N, Yavuz Y, et al. Relative lumbar lordosis and lordosis distribution index: individualized pelvic incidence-based proportional parameters that quantify lumbar lordosis more precisely than the concept of pelvic incidence minus lumbar lordosis. *Neurosurg Focus*. 2017;43(6):E5.
24. Roussouly P, Gollogly S, Berthonnaud E, Dimnet J. Classification of the normal variation in the sagittal alignment of the human lumbar spine and pelvis in the standing position. *Spine (Phila Pa 1976)*. 2005;30(3):346–353.
25. Lee A, Lucasti C, Scott MM, et al. The surgical outcomes of pedicle subtraction osteotomy per different first assistant: Retrospective analysis of 312 cases. *J Am Acad Orthop Surg*. 2024;32(1):e33–e43.
26. Chou D, Lafage V, Chan AY, et al. Patient outcomes after circumferential minimally invasive surgery compared with those of open correction for adult spinal deformity: initial analysis of prospectively collected data. *J Neurosurg Spine*. 2021;36(2):1–12.
27. Godzik J, Pereira BA, Newcomb AGUS, et al. Optimizing biomechanics of anterior column realignment for minimally invasive deformity correction. *Spine J*. 2020;20(3):465–474.
28. Chan AK, Eastlack RK, Fessler RG, et al. Two- and three-year outcomes of minimally invasive and hybrid correction of adult spinal deformity. *J Neurosurg Spine*. 2021;36(4):595–608.
29. Ohiorhenuan I, Deviren V, Uribe JS. MIS lateral ACR for spinal deformity correction: technique and complication avoidance. *Neurosurg Focus Video*. 2020;2(1):V1.
30. Cummock MD, Vanni S, Levi AD, Yu Y, Wang MY. An analysis of postoperative thigh symptoms after minimally invasive transpsoas lumbar interbody fusion. *J Neurosurg Spine*. 2011;15(1):11–18.
31. Spiessberger A, Arvind V, Dietz N, et al. A comparison of complications and clinical and radiologic outcome between the mini-open prepsaos and mini-open transpsoas approaches for lumbar interbody fusion. *Clin Spine Surg*. 2020;33(7):271–279.
32. Park SW, Ko MJ, Kim YB, Le Huec JC. Correction of marked sagittal deformity with circumferential minimally invasive surgery using oblique lateral interbody fusion in adult spinal deformity. *J Orthop Surg Res*. 2020;15(1):13.

Disclosures

Dr. Pham reported grants and personal fees from Medtronic, and grants from Globus, Thompson Surgical, and NovApproach outside the submitted work.

Author Contributions

Conception and design: Brown, Pham. Acquisition of data: Brown, González, Pham. Analysis and interpretation of data: Brown, Pishva, Pham. Drafting the article: Brown, Pennington, Pishva, Pham. Critically revising the article: all authors. Reviewed submitted version of manuscript: all authors. Approved the final version of the manuscript on behalf of all authors: Brown. Administrative/technical/material support: Pishva. Study supervision: Brown, Pham.

Supplemental Information

Online Only Content

Supplemental material is available with the online version of the article. *Supplementary Table 1*. <https://thejns.org/doi/suppl/10.3171/CASE23680>.

Correspondence

Nolan J. Brown: UC Irvine Health, Orange, CA. nolanb@uci.edu.