

# UCSF

## UC San Francisco Previously Published Works

### Title

Focal Cerebral Arteriopathy of Childhood

### Permalink

<https://escholarship.org/uc/item/02t2953m>

### Journal

Stroke, 49(11)

### ISSN

0039-2499

### Authors

Fullerton, Heather J  
Stence, Nicholas  
Hills, Nancy K  
[et al.](#)

### Publication Date

2018-11-01

### DOI

10.1161/strokeaha.118.021556

Peer reviewed

# Focal Cerebral Arteriopathy of Childhood

## Novel Severity Score and Natural History

Heather J. Fullerton, MD, MAS; Nicholas Stence, MD; Nancy K. Hills, PhD; Bin Jiang, MD; Catherine Amlie-Lefond, MD; Timothy J. Bernard, MD; Neil R. Friedman, MBChB; Rebecca Ichord, MD; Mark T. Mackay, MBBS, PhD; Mubeen F. Rafay, MBBS; Stéphane Chabrier, MD; Maja Steinlin, MD; Mitchell S.V. Elkind, MD, MS; Gabrielle A. deVeber, MD, MSc; Max Wintermark, MD; and the VIPS Investigators\*

**Background and Purpose**—Focal cerebral arteriopathy (FCA)—a common cause of arterial ischemic stroke in previously healthy children—often progresses over days to weeks, increasing the risk of recurrent stroke. We developed a novel severity scoring system designed to quantify FCA progression and correlate with clinical outcomes.

**Methods**—The VIPS study (Vascular Effects of Infection in Pediatric Stroke) prospectively enrolled 355 children with arterial ischemic stroke (2010–2014), including 41 with centrally confirmed FCA. Two neuroradiologists independently reviewed FCA cerebrovascular imaging, assigning a graded severity score of zero (no involvement) to 4 (occlusion) to individual arterial segments. The FCA severity score (FCASS) was the unweighted sum. In an iterative process, we modeled scores derived from different combinations of arterial segments to identify the model that optimized correlation with clinical outcome, simplicity, and reliability.

**Results**—The optimal FCASS summed scores from 5 arterial segments: supraclinoid internal carotid artery, A1, A2, M1, and M2. The median (interquartile range) baseline FCASS was 4 (2–6). Of 33 children with follow-up imaging, the maximum FCASS (at any time point) was 7 (5–9). Twenty-four (73%) had FCA progression on follow-up with their maximum FCASS at a median of 8 (5–35.5) days poststroke; their median FCASS increase was 4 (2.5–6). FCASS did not correlate with recurrent arterial ischemic stroke. Maximum (but not baseline) FCASS correlated with 1-year pediatric stroke outcome measures ( $P=0.037$ ).

**Conclusions**—Our novel scoring system for FCA severity correlates with neurological outcomes in the VIPS cohort and provides a tool for FCA treatment trials under development. (*Stroke*. 2018;49:2590-2596. DOI: 10.1161/STROKEAHA.118.021556.)

**Key Words:** brain ischemia ■ cerebrovascular disorders ■ child ■ follow-up studies ■ humans

Focal cerebral arteriopathy (FCA) of childhood, also known as transient cerebral arteriopathy, is an acute, monophasic disease causing unilateral stenosis of the intracranial cerebral arteries, mainly involving the anterior circulation. One of the most common causes of arterial ischemic stroke (AIS) in a previously healthy child, FCA, has also been described in young adults.<sup>1–4</sup> It confers a high risk of recurrent stroke ( $\leq 25\%$  within 1 year), compounding poststroke

lifelong disability.<sup>5,6</sup> Most cases are presumed to be inflammatory; vessel wall imaging demonstrates enhancement of affected arterial segments.<sup>7</sup> In its early phase, FCA can rapidly progress over days to weeks. Children with progressive arteriopathies have a higher risk of recurrent ischemia,<sup>6,8,9</sup> and a single study suggests a link between elevated inflammatory biomarkers (hsCRP [high-sensitivity C-reactive protein] and SAA [serum amyloid A]), arteriopathy progression, and stroke

Received March 26, 2018; final revision received August 23, 2018; accepted August 30, 2018.

From the Department of Neurology (H.J.F., N.K.H.), Department of Pediatrics (H.J.F.), and Department of Biostatistics and Epidemiology (N.K.H.), University of California, San Francisco; Department of Radiology (N.S.) and Department of Pediatrics (T.J.B.), University of Colorado, Denver; Division of Neuroradiology, Department of Radiology, Stanford University, CA (B.J., M.W.); Department of Neurology, University of Washington, Seattle (C.A.-L.); Center for Pediatric Neurosciences, Neurological Institute, Cleveland Clinic, OH (N.R.F.); Department of Neurology, Children's Hospital of Philadelphia, Perelman School of Medicine of the University of Pennsylvania (R.I.); Department of Paediatrics, Royal Children's Hospital, Murdoch Children's Research Institute, University of Melbourne, Victoria, Australia (M.T.M.); Department of Pediatrics and Child Health, Children's Hospital, University of Manitoba, Winnipeg, Canada (M.F.R.); INSERM, UMR1059 Sainbiose, University of Lyon, CHU Saint-Étienne, France (S.C.); Department of Pediatric Neurology, University Children's Hospital, University of Bern, Switzerland (M.S.); Department of Epidemiology, Mailman School of Public Health (M.S.V.E.) and Department of Neurology, Vagelos College of Physicians and Surgeons (M.S.V.E.), Columbia University, New York, NY; and Division of Neurology, Hospital for Sick Children, Toronto, Canada (G.A.D.).

\*A list of all VIPS Investigators is given in Appendix in the [online-only Data Supplement](#).

The online-only Data Supplement is available with this article at <https://www.ahajournals.org/doi/suppl/10.1161/STROKEAHA.118.021556>.

Correspondence to Heather J. Fullerton, MD, MAS, Department of Neurology, University of California, San Francisco, San Francisco, CA 94143-0663. Email [heather.fullerton@ucsf.edu](mailto:heather.fullerton@ucsf.edu)

© 2018 American Heart Association, Inc.

*Stroke* is available at <https://www.ahajournals.org/journal/str>

DOI: 10.1161/STROKEAHA.118.021556

recurrence.<sup>8</sup> Varicella zoster virus (VZV) is a long-established cause of FCA,<sup>10–12</sup> yet other pathogens, including other herpes viruses, likely play a role as FCA continues to occur in VZV-vaccinated children.<sup>13</sup>

Corticosteroids are increasingly used to treat FCA, although in the absence of clinical trial data.<sup>14,15</sup> Equipoise remains: steroids might suppress the presumed focal inflammatory process but might also worsen the underlying infectious pathogenesis. A Delphi consensus identified this issue as the highest priority for a clinical trial in the field of childhood stroke.<sup>16</sup> Investigators currently developing FCA treatment trial protocols have realized the need for a quantitative measure of FCA severity to serve as a clinical trial surrogate end point and quantify temporal evolution of the arteriopathy. Using the subcohort of children with FCA enrolled in the VIPS study (Vascular Effects of Infection in Pediatric Stroke), our goals were (1) to develop an FCA severity score (FCASS) that correlates with clinical outcomes and (2) to apply the score to describe the natural history of FCA. We also performed exploratory analyses to determine whether the final FCASS correlated with previously reported VIPS study biomarkers of inflammation and infection.<sup>8,17</sup>

## Methods

In accordance with the National Institutes of Health-approved data sharing policy for the VIPS study, the data supporting this study are available from the corresponding author on request. The VIPS study was a prospective cohort study that enrolled 355 children (29 days to 18 years of age) with AIS at 37 international centers and collected clinical and imaging data and serum samples.<sup>2,4</sup> Ethics approval was obtained by the institutional review board at each center, and written informed consent was obtained for each enrollment. We centrally reviewed clinical data and all clinically obtained cerebral and vascular imaging to confirm the AIS diagnosis, estimate the infarct volume (using ABC/2), and classify cervical and cerebral arteriopathies.<sup>2,4</sup> A board-certified neuroradiologist (M.W.) delineated the infarct contour and the brain contour on fluid-attenuated inversion recovery (FLAIR) images and, taking into account FLAIR slice thickness, calculated the absolute infarct volume and brain volume. We then calculated the relative infarct volume (percentage of total brain volume) by dividing the absolute volume of the infarct by the absolute volume of the brain. As reported previously, we defined FCA as “unifocal and unilateral stenosis/irregularity of the large intracranial arteries of the anterior circulation (distal internal carotid artery [ICA] and/or its proximal branches),” and then subclassified as FCA inflammation type, FCA dissection type, and undetermined FCA.<sup>4</sup>

## Development of FCASS

For the current study, we designed an initial FCASS based on the vascular imaging appearance of 9 unilateral arterial segments: cervical, petrous, cavernous, and supraclinoid segments of the ICA; M1 and M2 segments of the middle cerebral artery; A1 and A2 segments of the anterior cerebral artery; and the posterior cerebral artery (either P1 or P2). Because FCA is a unilateral disease, we measured only the involved (symptomatic) side of the intracranial circulation. Two neuroradiologists (M.W. and N.S.) independently reexamined the vascular imaging for all 41 FCA cases in VIPS and applied the initial scoring system. Each segment was assigned a graded severity score: 0, no involvement; 1, irregularity or banding with no stenosis; 2, stenosis <50% reduction in diameter; 3, stenosis >50% reduction in diameter; and 4, occlusion. The small size of M2 and A2 branches precluded reliable scoring of stenosis severity, so any stenosis of those segments was initially scored as 3 (with no option to score as 2); hence, these segments were classified into 1 of only 4 categories (scored 0, 1, 3, or 4). The scores for the individual arterial

segments were summed without weighting to provide an initial total score. These methods would not capture changes over time that were within scoring categories (eg, for progression from 60% to 90% stenosis; both would be coded as 3). Hence, we devised the delta point: a single point that could be added/subtracted to indicate any interval worsening (+1) or improvement (–1) not otherwise captured by the sum total of the scored segments (only a single delta point could be applied, regardless of whether a single segment or multiple segments changed). We defined the maximum FCASS for each case as the highest total score at any time point. If only a single FCASS score was available (n=8), that score was also considered to be the maximum, unless otherwise indicated. One neuroradiologist (M.W.) scored all imaging twice in 2 separate sessions.

## Optimization of the FCASS

We then optimized the scoring system with the a priori goals of maximizing correlation with clinical outcomes while maintaining simplicity (user-friendliness) and achieving a high degree of intrarater and interrater reliability. Clinical outcomes included 1-year cumulative stroke recurrence rates, as defined previously,<sup>5</sup> and 1-year pediatric stroke outcome measures (PSOM). The PSOM is a validated outcome measure for childhood AIS, which quantifies neurological exam findings and can be estimated via a telephone parental questionnaire; scores range from 0 (no deficits) to 10 (profound deficits).<sup>18,19</sup> The VIPS study performed 1-year PSOMs (12±3 months poststroke) in clinic for the majority and via telephone when in-clinic assessments were not feasible.<sup>20</sup>

In an iterative process, we created different FCASS models by serially removing arterial segments (Methods in the [online-only Data Supplement](#)). We assessed each individual model, measuring the correlation of the FCASS (baseline and maximum scores) with clinical outcomes and determining intrarater and interrater reliability. We carried forward the optimal FCASS model to the final refinement step: determining whether it was possible to further collapse the numeric scoring system (0–4, for each arterial segment) into fewer categories. Instructions for the final (optimal) FCASS system are in Methods in the [online-only Data Supplement](#). We then analyzed the final FCASS in our cohort to describe its correlation with serum biomarkers and, in those with follow-up imaging, its evolution over time.

## Data Analysis

We computed intraclass correlation coefficients as estimates of intrarater and interrater reliability for the total FCASS and individual components using standard regression methods. We utilized Spearman rank-order correlation to assess for correlation between FCASS and relative infarct volume. In analyses of correlation with clinical outcomes, our predictor variables included both baseline and maximum FCASS, both including and excluding those without follow-up data. Using methods previously described for the VIPS cohort, we used Cox proportional hazards models to measure risk of stroke recurrence in children with FCA<sup>5</sup> and Spearman correlation coefficients to measure potential association with 1-year PSOM scores.<sup>20</sup> Because our specific purpose was to compare multiple models to find the one that best correlated with our chosen outcomes (rather than testing a particular hypothesis), we made no multiple comparison adjustments.

In exploratory analyses, we calculated Spearman correlation coefficients between FCASS (baseline and maximum) and the inflammatory and infectious biomarkers previously measured and reported in the VIPS cohort. Inflammatory markers included serum concentrations of hsCRP, SAA, MPO (myeloperoxidase), and TNF- $\alpha$  (tumor necrosis factor- $\alpha$ ).<sup>8</sup> Infectious biomarkers included serum IgM/IgG antibodies for herpes simplex virus 1 and 2, *Cytomegalovirus*, Epstein-Barr virus, and VZV.<sup>17</sup> We used our previously published algorithm for using acute and convalescent serologies to classify serological evidence of acute herpesvirus infection as a dichotomous variable;<sup>17</sup> we used Wilcoxon rank sum tests to compare FCASS scores in those with versus without infection. All

analyses were done using Stata v14 (Stata Corp, College Station, TX) with  $\alpha$  set at 0.05.

## Results

The 41 FCA cases in the VIPS cohort (25 FCA inflammation type, 7 FCA dissection type, and 9 undetermined FCA) had a median age of 11.3 years (interquartile range [IQR] 7.4–14.3 years; range, 5 months to 17.7 years) and were 46% men. The overall VIPS cohort had a median age of 7.2 (IQR, 2.8–14.3) years and was 56% men. FCA cases were racially diverse: 27 (66%) white, 4 (10%) Asian, 3 (7%) Hispanic, 2 (5%) black, and 5 (12%) other/unknown. Baseline vascular imaging was performed on the same day as the stroke in 41% of cases: median of 1 day (IQR, 0–2 days; range 0–14 days) after the stroke ictus. Magnetic resonance angiogram was the most common imaging modality, performed in 38 cases (93%) at baseline and 40 cases (98%) overall (including follow-up imaging); conventional angiography was performed in 14 (34%) and computed tomography angiogram in 15 (37%). At baseline, the median absolute infarct volume was 14.7 mL (IQR, 6.5–33.0 mL; range, 0.08–251 mL); the median relative infarct volume was 1.1% (IQR, 0.5%–2.3%; range, 0.005%–15.2 %).

## Development of the FCASS

Because we identified no posterior cerebral artery abnormalities, we excluded this segment from the model. Only 34 cases (83%) had cervical vascular imaging (at any time point), and 25 (73%) of these had no cervical arterial involvement; we, therefore, also excluded the cervical ICA from the model. Model A included all the remaining segments (petrous, cavernous, and supraclinoid segments of the ICA; M1, M2, A1, and A2), which were then removed in an iterative fashion (models B–E). We modeled both baseline and maximum FCASS; for this analysis, the baseline score of those with no follow-up imaging was also defined as the maximum score. Interrater and intrarater reliability was high for all models (Table I in the [online-only Data Supplement](#)). None of the models correlated with recurrent stroke (Table 1). In all models, the maximum FCASS score was more closely associated

with 1-year PSOMs than the baseline score; model B (supraclinoid ICA, M1, M2, A1, and A2 segments) for the maximum FCASS score was the only model that demonstrated a significant correlation with 1-year PSOMs (Table 1). Model B was, therefore, carried forward to the final refinement step of maximizing simplicity. We created additional models collapsing the numeric scoring system (0–4) into fewer categories: model B1 combining scores 1 through 4, model B2 combining scores 1 and 2 and scores 3 and 4, and model B3 combining scores 1 through 3. Each of these models demonstrated a weaker correlation with 1-year PSOMs (Table II in the [online-only Data Supplement](#)). Hence, we designated model B with the initial numeric scoring system (0–4, for each arterial segment) as the final (optimal) FCASS (Methods in the [online-only Data Supplement](#)). We used this model for all subsequent analyses.

## Change in FCASS Over Time

The baseline FCASS was a median of 4 (IQR, 2–6; range, 1–15; Figure 1). Of the 41 cases, 33 (80%) had at least 1 follow-up vascular imaging study, and 28 (68%) had >1. Those with versus without follow-up vascular imaging had similar absolute and relative infarct volumes, baseline FCASS scores, and 1-year PSOMs (Table III in the [online-only Data Supplement](#)). The median time from stroke to first follow-up imaging was 10 days (IQR, 5–52; range, 1–405) and from stroke to last follow-up was 112 days (IQR, 4–349; range, 0–674 days). The change in FCASS is summarized in Figure 1; representative imaging is shown in Figure 2. Our imaging reviewers did not apply the delta point for any case in this cohort. The maximum FCASS among all 41 cases, including those with a single assessment, was a median of 7 (IQR, 4–9; range, 1–16); the maximum FCASS among those 33 cases with follow-up vascular imaging was similar (median, 7; IQR, 5–9; range, 2–16). Among those 33 with multiple FCASS measurements, the score increased (indicating worsening arteriopathy) in 24 (73%), remained unchanged in 8 (24%), and decreased (without an initial increase) in 1 (3%). Among the 24 with increased scores, the median change was +4 (IQR, 2.5–6; range, 1–9), and the median time from stroke

**Table 1. Clinical Outcome Correlation of Iterative Models of the FCASS**

Model	Arterial Segments Excluded*	All FCA Subjects (n=41)				Subjects With Follow-up (n=33)			
		1-y PSOM†	Recurrent Stroke			1-y PSOM†	Recurrent Stroke		
HR	95% CI		P Value‡	HR	95% CI		P Value‡		
A	None excluded	0.13	1.1	0.97–1.14	0.19	0.19	1.05	0.97–1.13	0.24
B	Proximal (petrous/cavernous) ICA§	0.037	1.1	0.91–1.23	0.47	0.037	1.05	0.90–1.24	0.53
C	Proximal ICA, A1	0.089	1.10	0.92–1.32	0.30	0.12	1.10	0.91–1.34	0.32
D	Proximal ICA, A1, A2	0.087	1.1	0.92–1.35	0.26	0.14	1.10	0.91–1.34	0.34
E	Proximal ICA, A1, A2, M2	0.11	1.2	0.89–1.59	0.25	0.21	1.18	0.86–1.61	0.31

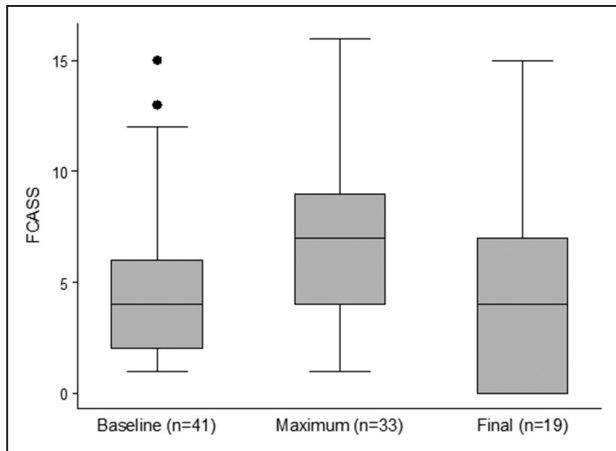
Data for maximum FCASS are shown. Model A includes petrous, cavernous, and supraclinoid segments of the ICA; M1 and M2 segments of the MCA; and A1 and A2 segments of the ACA. Subsequent models exclude arterial segments in an iterative fashion. ACA indicates anterior cerebral artery; AIS, arterial ischemic stroke; FCA, focal cerebral arteriopathy; FCASS, focal cerebral arteriopathy severity score; HR, hazard ratio; ICA, internal carotid artery; MCA, middle cerebral artery; PCA, posterior cerebral artery; and PSOM, pediatric stroke outcome measures.

\*PCA was normal in all cases and not included in any model.

†P values for trend test for correlation between maximum FCASS and 1-y PSOM categorical variable.

‡Cox proportional hazards for correlation between maximum FCASS and time to first recurrent AIS.

§Final (optimal) model.



**Figure 1.** Box and whisker plots summarizing baseline, maximum, and final focal cerebral arteriopathy severity score (FCASS) scores. Maximum FCASS includes only those with follow-up imaging ( $n=33$ ). Final FCASS includes only those 19 cases with follow-up imaging  $\geq 6$  mo poststroke (box represents interquartile range [IQR], line within box represents median, whiskers represent upper adjacent [75th percentile+1.5 $\times$ IQR] and lower adjacent [25th percentile–1.5 $\times$ IQR] values, and dots represent outliers).

to the imaging with the maximum FCASS was 8 days (IQR, 5–35.5; range, 2–189). The greatest change observed was in a case of FCA dissection type: baseline score of 7 and a maximum score of 16, 2 days later. Of 19 patients with their last follow-up imaging  $\geq 6$  months after the stroke, the last FCASS was a median of 4 (IQR, 0–7; range, 0–15); 26% of patients had complete normalization of their vascular imaging (final FCASS of 0; Figure 1).

### Correlation With Infarct Volume and Neurological Outcomes

Larger relative infarct volumes on baseline imaging correlated with higher FCASS scores: Spearman  $\rho$ , 0.41 ( $P=0.008$ ) for

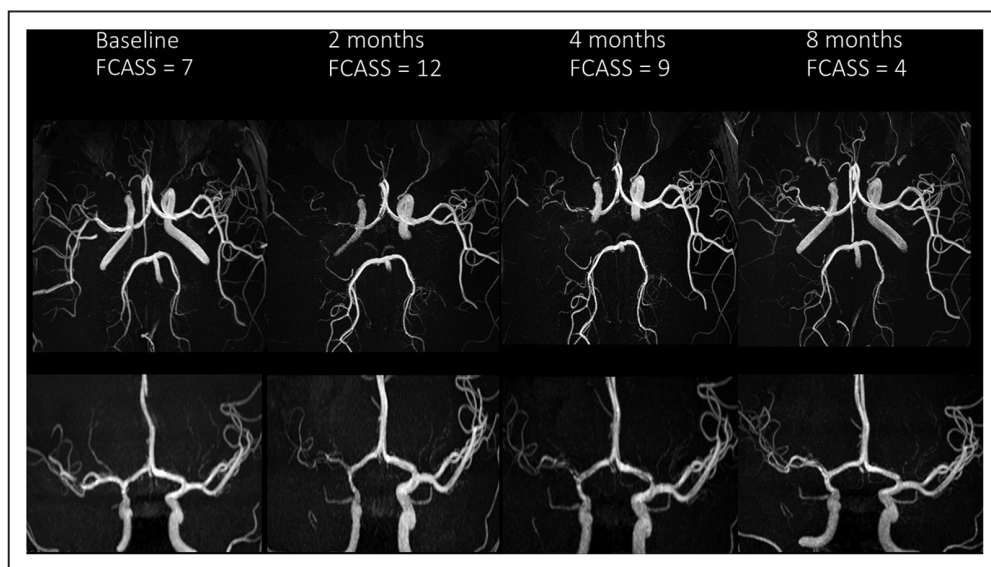
baseline FCASS (Figure 3) and 0.50 ( $P=0.0008$ ) for maximum FCASS. Children with ( $n=8$ ) versus without ( $n=33$ ) recurrent AIS during the study period had similar FCASS scores (Table 2). The median 1-year PSOM in our cohort ( $n=39$  with 1-year outcomes) was 1 (IQR, 0–1.5; range, 0–4.5). Higher 1-year PSOMs (indicating greater neurological deficits) correlated with higher maximum FCASS scores ( $P=0.037$ ; Table 2).

### Correlation With Inflammatory Biomarkers and Herpesvirus Exposure

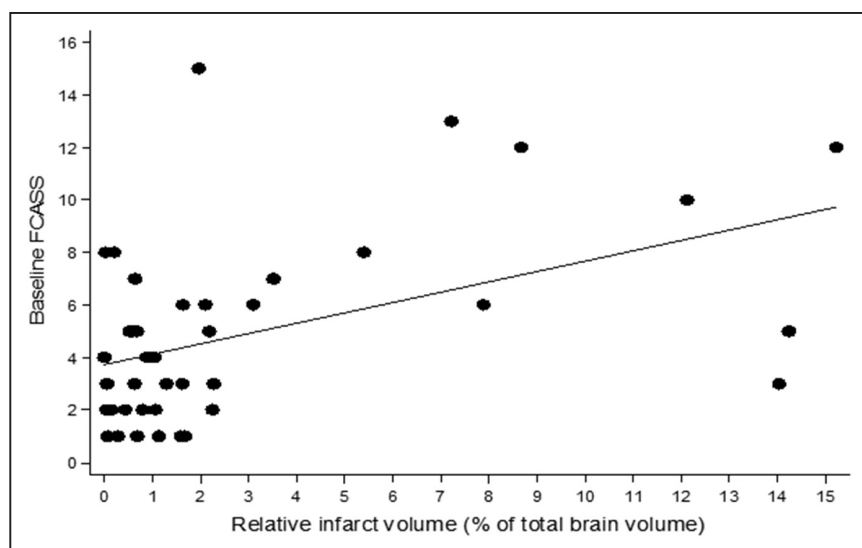
Acute serum samples were collected for 38 children at a median of 5 days poststroke (IQR, 3–10 days); 25 had convalescent serum samples collected at median 20 days poststroke (IQR, 14–32 days). Baseline and maximum FCASS scores (utilizing all subjects, including those without follow-up imaging) correlated with acute serum levels of hsCRP but not other levels of inflammatory biomarkers (Table 3). The median (IQR) hsCRP was 0.86 (0.48–1.56) for the quartile with the highest maximum FCASS scores, compared with 0.16 (0.16–0.25) for the lowest quartile. FCASS did not differ significantly by serological evidence of acute herpesvirus infection. Of 25 FCA cases with paired (acute and convalescent) serologies, 10 (40%) had evidence of an acute herpesvirus infection: 8 positive for herpes simplex virus (1 or 2) alone, 1 positive for VZV, and 1 positive for herpes simplex virus and VZV. The median (IQR) baseline FCASS was 5 (1–6) for the 10 herpes-positive cases and 3 (2–7) for the 15 herpes-negative cases ( $P=0.98$ ); maximum FCASS was 8 (6–12) for herpes-positive and 6 (2–8) for herpes-negative cases ( $P=0.13$ ).

### Discussion

By developing a novel tool for quantifying the severity, extent, and evolution of arterial disease in children with FCA—the



**Figure 2.** Cerebral magnetic resonance angiogram images demonstrating evolution of a typical case of focal cerebral arteriopathy inflammation type: axial views (top) and frontal views (bottom) at 4 time points. Baseline images demonstrate mild irregularity of the right supraclinoid internal carotid artery and M1 segment of the middle cerebral artery. The 2-mo images show progression to severe stenosis; the 4- and 8-mo images demonstrate subsequent improvement. FCASS, focal cerebral arteriopathy severity score



**Figure 3.** Scatter plot demonstrating the correlation between baseline focal cerebral arteriopathy severity score (FCASS) and relative infarct volume (percentage of total brain volume), also measured at baseline.

FCASS, we demonstrated a wide range of disease severity within our FCA cohort and found dynamic changes over time with doubling of the score during a matter of days in the most severely progressive cases. Children with higher maximum FCASS scores had significantly larger infarct volumes and worse neurological outcomes at 1 year. FCASS severity also correlated with 1 acute serum inflammatory biomarker, hsCRP, providing some additional evidence that FCA is an inflammatory disease. We could not confirm an association with evidence of acute herpesvirus infection, however.

Two published studies describe severity scores for childhood arteriopathies, although neither was specific to FCA.<sup>9,21</sup> Both examined the correlation with recurrent stroke. The cerebrovascular stenosis score used a similar quantitative scoring system (1 for low-grade stenosis, 2 for high-grade stenosis, or 3 for occlusion), scoring 18 bilateral arterial segments and summing the individual scores.<sup>21</sup> When applied to a cohort of 49 children with AIS and a variety of arteriopathies, the cerebrovascular stenosis score demonstrated good interrater reliability (intraclass correlation coefficient, 0.77; 95% CI,

**Table 2.** Natural History of FCASS Over Time Stratified by Focal Cerebral Arteriopathy Subtype, Recurrence, and 1-Year Neurological Outcomes (PSOM)

	Baseline			Maximum*			Final†		
	n	Median	Range	n	Median	Range	n	Median	Range
Overall	41	4	1–15	33	7	2–16	19	4	0–15
Subtype‡									
FCAi	25	3	1–8	22	6	2–13	12	3.5	0–7
FCA <sub>d</sub>	7	10	5–13	5	14	5–16	3	5	0–9
FCA <sub>u</sub>	9	3	1–15	6	8	2–15	4	3.5	0–15
Recurrent stroke									
Yes	8	4.5	1–8	8	7	3–16	4	4.5	0–9
No	33	4	1–15	25	7	2–16	15	4	0–15
1-y PSOM§									
0–1 (no/mild deficits)	25	4	1–15	21	6	2–15	13	3	0–15
1.5–3 (moderate)	12	5	1–13	9	9	3–16	5	7	1–9
3.5–6 (severe)	2	7	2–12	2	12	8–16	1	5	5–5
6.5–10 (profound)	0	...	...	0	...	...	0	...	...

FCA<sub>d</sub> indicates focal cerebral arteriopathy dissection type; FCA<sub>i</sub>, focal cerebral arteriopathy inflammation type; FCASS, focal cerebral arteriopathy severity score; FCA<sub>u</sub>, focal cerebral arteriopathy undetermined; IQR, interquartile range; and PSOM, pediatric stroke outcome measures.

\*Time from index stroke to imaging with maximum FCASS: median, 5 d (range, 0–189 days; IQR, 2–15); includes all of those with follow-up (n=33), with or without progression.

†The last FCASS score for those cases with follow-up imaging ≥6 mo poststroke.

§PSOM missing for 2 cases; trend test for correlation,  $P=0.68$  for baseline,  $P=0.037$  for maximum, and  $P=0.16$  for final FCASS score.

‡Differences between FCA<sub>i</sub> and FCA<sub>d</sub> are significant for baseline ( $P=0.001$ ) and maximum ( $P=0.0007$ ) but not for final FCASS ( $P=0.11$ ).

**Table 3. Correlation of FCASS With Acute Serum Levels of Inflammatory Markers Measured in the VIPS Study (Vascular Effects of Infection in Pediatric Stroke)\***

Serum Inflammatory Marker	Baseline FCASS		Maximum FCASS	
	n=36		n=36†	
	Spearman $\rho$	P Value	Spearman $\rho$	P Value
hsCRP	0.35	0.036	0.47	0.004
MPO	0.30	0.08	0.28	0.10
SAA	0.20	0.24	0.27	0.11
TNF- $\alpha$	-0.05	0.75	-0.16	0.34

FCA indicates focal cerebral arteriopathy; FCASS, focal cerebral arteriopathy severity score; hsCRP, high-sensitivity C-reactive protein; MPO, myeloperoxidase; SAA, serum amyloid A; and TNF- $\alpha$ , tumor necrosis factor- $\alpha$ .

\*Inflammatory markers were not available for 5 of the 41 patients with FCA.

†For those with no follow-up imaging, the baseline score was considered to be the maximum score.

0.63–0.87), although lower than that for FCASS (0.86; 95% CI, 0.81–0.90); cerebrovascular stenosis score intrarater reliability was not assessed. Higher cerebrovascular stenosis score predicted stroke recurrence amongst children with moyamoya but not other forms of arteriopathy. A British study of 43 children with AIS and abnormal magnetic resonance angiogram categorized the magnetic resonance angiogram abnormalities into 3 grades without scoring individual arterial segments; the authors did not assess intrarater or interrater reliability.<sup>9</sup> Although limited by variable timing of follow-up vascular imaging, they found that children with progressive arteriopathies (of any subtype) had triple the risk of recurrent ischemic events (stroke, transient ischemic attack, or silent infarcts) compared with those without evidence of arteriopathy progression.

In our overall VIPS cohort, including all types of cervical and cerebral arteriopathy (eg, FCA, moyamoya, cervical dissection, and genetic arteriopathies), we similarly found that arteriopathy progression predicted recurrent AIS.<sup>8</sup> In the FCA subcohort, however, FCASS scores did not predict recurrence, although higher maximum FCASS scores correlated with both larger infarct size and poorer 1-year neurological outcomes. We speculate that this finding may reflect the nature of progressive brain injury in children with accelerating FCA. Because FCA is a focal disease, its progression may result in expansion of the core infarct in the same ICA distribution and a slow worsening of the original deficits (eg, worsened hemiparesis) that may not be distinct enough from the index stroke to meet criteria for a recurrent stroke. However, we did not have adequate follow-up brain imaging to measure infarct expansion and test this hypothesis.

Limitations include our small sample size; we may have been underpowered to detect an association between FCASS and stroke recurrence, for example. Our cohort had only clinically obtained imaging, hence combining a mix of imaging modalities and variable performance and timing of follow-up imaging. The FCASS was developed primarily using magnetic resonance angiogram, which can overestimate arterial stenosis relative to conventional angiography and computed tomography angiogram; we were unable to study how different modalities may yield different results. The clinical decision

to perform follow-up imaging at a particular time may itself reflect greater severity of the disease or worse clinical outcomes (we may have been underpowered to detect a difference between those with and without follow-up imaging). We may have missed periods of arteriopathy progression, leading to misclassification of cases with versus without progression. Future studies would be improved by imaging collection at systematic time points among all patients. We developed the tool in a single patient cohort; however, a validation study is now underway, testing FCASS in an independent FCA cohort from the Swiss Neuropaediatric Stroke Study.<sup>22</sup>

Despite these limitations, the FCASS demonstrated high intrarater and interrater reliability and correlated with neurological outcomes in the VIPS cohort. After validation in an independent cohort, we anticipate it could serve as a clinically meaningful measurement and end point for FCA treatment trials. Our natural history data provide further evidence that FCA is a dynamic arteriopathy. Frequent progression in the first days to weeks suggests a window for therapeutic intervention to improve neurological outcomes. The recent Swiss/Australian observational study of FCA found that children who received corticosteroid therapy had better 6-month PSOMs than those who did not<sup>14</sup>; this compelling finding should now be tested in clinical trials.

### Acknowledgments

We wish to acknowledge the important contributions of the research coordinators at VIPS (Vascular Effects of Infection in Pediatric Stroke) sites and of the patients and their families.

### Sources of Funding

This study was supported by National Institutes of Health grant R01 NS062820 (principal investigators Drs Fullerton and DeVeber), statistical support by Marc and Lynne Benioff, and by American Heart Association Bugher Award (Dr Bernard).

### Disclosures

None.

### References

- Chabrier S, Rodesch G, Lasjaunias P, Tardieu M, Landrieu P, S ebire G. Transient cerebral arteriopathy: a disorder recognized by serial angiograms in children with stroke. *J Child Neurol*. 1998;13:27–32. doi: 10.1177/088307389801300105
- Wintermark M, Hills NK, deVeber GA, Barkovich AJ, Elkind MS, Sear K, et al; VIPS Investigators. Arteriopathy diagnosis in childhood arterial ischemic stroke: results of the vascular effects of infection in pediatric stroke study. *Stroke*. 2014;45:3597–3605. doi: 10.1161/STROKEAHA.114.007404
- Bulder MM, Braun KP, Leeuwis JW, Lo RT, van Nieuwenhuizen O, Kappelle LJ, et al. The course of unilateral intracranial arteriopathy in young adults with arterial ischemic stroke. *Stroke*. 2012;43:1890–1896. doi: 10.1161/STROKEAHA.112.653212
- Wintermark M, Hills NK, DeVeber GA, Barkovich AJ, Bernard TJ, Friedman NR, et al; VIPS Investigators. Clinical and imaging characteristics of arteriopathy subtypes in children with arterial ischemic stroke: results of the VIPS study. *AJNR Am J Neuroradiol*. 2017;38:2172–2179. doi: 10.3174/ajnr.A5376
- Fullerton HJ, Wintermark M, Hills NK, Dowling MM, Tan M, Rafay MF, et al; VIPS Investigators. Risk of recurrent arterial ischemic stroke in childhood: a Prospective International Study. *Stroke*. 2016;47:53–59. doi: 10.1161/STROKEAHA.115.011173
- Braun KP, Bulder MM, Chabrier S, Kirkham FJ, Uiterwaal CS, Tardieu M, et al. The course and outcome of unilateral intracranial arteriopathy in

- 79 children with ischaemic stroke. *Brain*. 2009;132(pt 2):544–557. doi: 10.1093/brain/awn313
7. Stence NV, Pabst LL, Hollatz AL, Mirsky DM, Herson PS, Poisson S, et al. Predicting progression of intracranial arteriopathies in childhood stroke with vessel wall imaging. *Stroke*. 2017;48:2274–2277. doi: 10.1161/STROKEAHA.117.017922
  8. Fullerton HJ, deVeber GA, Hills NK, Dowling MM, Fox CK, Mackay MT, et al; VIPS Investigators. Inflammatory biomarkers in childhood arterial ischemic stroke: correlates of stroke cause and recurrence. *Stroke*. 2016;47:2221–2228. doi: 10.1161/STROKEAHA.116.013719
  9. Danchaivijitr N, Cox TC, Saunders DE, Ganesan V. Evolution of cerebral arteriopathies in childhood arterial ischemic stroke. *Ann Neurol*. 2006;59:620–626. doi: 10.1002/ana.20800
  10. Kamholz J, Tremblay G. Chickenpox with delayed contralateral hemiparesis caused by cerebral angitis. *Ann Neurol*. 1985;18:358–360. doi: 10.1002/ana.410180317
  11. Sébire G, Meyer L, Chabrier S. Varicella as a risk factor for cerebral infarction in childhood: a case-control study. *Ann Neurol*. 1999;45:679–680.
  12. Lanthier S, Armstrong D, Domi T, deVeber G. Post-varicella arteriopathy of childhood: natural history of vascular stenosis. *Neurology*. 2005;64:660–663. doi: 10.1212/01.WNL.0000151851.66154.27
  13. Fullerton HJ, Hills NK, Elkind MS, Dowling MM, Wintermark M, Glaser CA, et al; VIPS Investigators. Infection, vaccination, and childhood arterial ischemic stroke: results of the VIPS study. *Neurology*. 2015;85:1459–1466. doi: 10.1212/WNL.0000000000002065
  14. Steinlin M, Bigi S, Stojanovski B, Gajera J, Regényi M, El-Koussy M, et al; Swiss NeuroPaediatric Stroke Registry. Focal cerebral arteriopathy: do steroids improve outcome? *Stroke*. 2017;48:2375–2382. doi: 10.1161/STROKEAHA.117.016818
  15. Elbers J, Armstrong D, Yau I, Benseler S. Vascular imaging outcomes of childhood primary angitis of the central nervous system. *Pediatr Neurol*. 2016;63:53–59. doi: 10.1016/j.pediatrneurol.2016.06.009
  16. Steinlin M, O'callaghan F, Mackay MT. Planning interventional trials in childhood arterial ischaemic stroke using a Delphi consensus process. *Dev Med Child Neurol*. 2017;59:713–718. doi: 10.1111/dmcn.13393
  17. Elkind MS, Hills NK, Glaser CA, Lo WD, Amlie-Lefond C, Dlamini N, et al; VIPS Investigators\*. Herpesvirus infections and childhood arterial ischemic stroke: results of the VIPS study. *Circulation*. 2016;133:732–741. doi: 10.1161/CIRCULATIONAHA.115.018595
  18. deVeber GA, MacGregor D, Curtis R, Mayank S. Neurologic outcome in survivors of childhood arterial ischemic stroke and sinovenous thrombosis. *J Child Neurol*. 2000;15:316–324. doi: 10.1177/088307380001500508
  19. Lo WD, Ichord RN, Dowling MM, Rafay M, Templeton J, Halperin A, et al; International Pediatric Stroke Study (IPSS) Investigators. The Pediatric Stroke Recurrence and Recovery Questionnaire: validation in a prospective cohort. *Neurology*. 2012;79:864–870. doi: 10.1212/WNL.0b013e318266fc9a
  20. Jordan LC, Hills NK, Fox CK, Ichord RN, Pergami P, deVeber GA, et al; VIPS Investigators. Socioeconomic determinants of outcome after childhood arterial ischemic stroke. *Neurology*. 2018;91:e509–e516. doi: 10.1212/WNL.0000000000005946
  21. Sultan SM, Beslow LA, Vossough A, Elkind MS, Kasner SE, Mirsky DM, et al. Predictive validity of severity grading for cerebral stenooclusive arteriopathy in recurrent childhood ischemic stroke. *Int J Stroke*. 2015;10:213–218. doi: 10.1111/ijs.12344
  22. Steinlin M, Pfister I, Pavlovic J, Everts R, Boltshauser E, Capone Mori A, et al; Swiss Societies of Paediatric Neurology and Neonatology. The first three years of the Swiss Neuropaediatric Stroke Registry (SNPSR): a population-based study of incidence, symptoms and risk factors. *Neuropediatrics*. 2005;36:90–97. doi: 10.1055/s-2005-837658