

# UC Davis

## UC Davis Previously Published Works

### Title

High-resolution 18F-FDG PET with MRI for monitoring response to treatment in rheumatoid arthritis

### Permalink

<https://escholarship.org/uc/item/02g7b8ps>

### Journal

European Journal of Nuclear Medicine and Molecular Imaging, 37(5)

### ISSN

1619-7089

### Authors

Chaudhari, Abhijit J.  
Bowen, Spencer L.  
Burkett, George W.  
[et al.](#)

### Publication Date

2010-05-01

### DOI

10.1007/s00259-009-1364-x

Peer reviewed

## High-resolution $^{18}\text{F}$ -FDG PET with MRI for monitoring response to treatment in rheumatoid arthritis

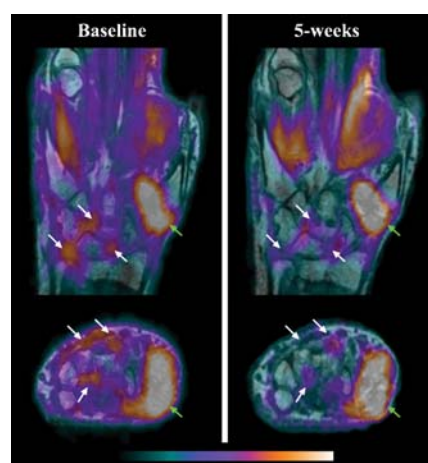
Abhijit J. Chaudhari · Spencer L. Bowen · George W. Burkett · Nathan J. Packard · Felipe Godinez · Anand A. Joshi · Stanley M. Naguwa · David K. Shelton · John C. Hunter · John M. Boone · Michael H. Buonocore · Ramsey D. Badawi

Received: 20 November 2009 / Accepted: 10 December 2009 / Published online: 30 January 2010  
© The Author(s) 2010. This article is published with open access at Springerlink.com

Molecular imaging can potentially provide means for monitoring response to therapy in rheumatoid arthritis (RA) early in the course of disease [1]. Quantitative measurements of RA disease activity made in the wrist by whole-body PET scanners, however, have inadequate accuracy because of limited spatial resolution [2]. A high-resolution PET/CT scanner for imaging extremities has been built at our institution [3]. In conjunction with a clinical MRI scanner, high-resolution PET/MR images can be obtained for the wrist. The CT image is used for PET/MR image coregistration.

A 57-year-old female with established RA was stable until a recent clinical flare-up in the right wrist. Clinical examination revealed synovitis, swelling, and diminished range of motion. The patient also had a history of osteoarthritis (OA). An extremity  $^{18}\text{F}$ -FDG PET/CT scan immediately following MRI at baseline was performed on this patient. Tumor necrosis factor alpha (TNF- $\alpha$ ) inhibitor (etanercept) therapy was then initiated as a part of the patient's standard of care. The patient was re-scanned 5 weeks after starting treatment.

The figure shows high-resolution  $^{18}\text{F}$ -FDG PET images (pseudocolor) overlaid on pre-contrast MRI images (gray



scale) at baseline (left column) and 5 weeks (right column). Significant reduction in PET signal (suggesting reduced inflammation) in the synovium and at sites of erosions (white arrows) is visible. The green arrow shows inflammation due to OA. Physician examination at 3 months confirmed that this patient responded positively to etanercept. This case illustrates the potential of high-resolution PET with MRI for quantitative visualization of early response to therapy in RA.

This work was funded by the NIH grants UL1-RR024146, R01CA129561, R01EB002138 and the UC Davis Imaging Research Center.

A. J. Chaudhari (✉) · S. L. Bowen · G. W. Burkett · N. J. Packard · F. Godinez · D. K. Shelton · J. C. Hunter · J. M. Boone · M. H. Buonocore · R. D. Badawi  
Department of Radiology,  
UC Davis Medical Center,  
Sacramento, CA, USA  
e-mail: ajchaudhari@ucdavis.edu

A. A. Joshi  
Department of Neurology, UCLA School of Medicine,  
Los Angeles, CA, USA

S. M. Naguwa  
Department of Internal Medicine,  
UC Davis Medical Center,  
Sacramento, CA, USA

**Open Access** This article is distributed under the terms of the Creative Commons Attribution Noncommercial License which permits any noncommercial use, distribution, and reproduction in any medium, provided the original author(s) and source are credited.

### References

1. Brenner W.  $^{18}\text{F}$ -FDG PET in rheumatoid arthritis: there still is a long way to go. *J Nucl Med.* 2004;45(6):927–9.
2. Beckers C, Ribbens C, André B, Marcellis S, Kaye O, Mathy L, et al. Assessment of disease activity in rheumatoid arthritis with  $^{18}\text{F}$ -FDG PET. *J Nucl Med.* 2004;45(6):956–64.
3. Bowen SL, Wu Y, Chaudhari AJ, Fu L, Packard NJ, Burkett GW, et al. Initial characterization of a dedicated breast PET/CT scanner during human imaging. *J Nucl Med.* 2009;50(9):1401–8.