

UC Davis

Dermatology Online Journal

Title

Certolizumab-induced guttate psoriasiform dermatitis

Permalink

<https://escholarship.org/uc/item/0197d9gk>

Journal

Dermatology Online Journal, 23(1)

Authors

Fischer, Ryan
DaCunha, Matthew
Rajpara, Anand

Publication Date

2017

DOI

10.5070/D3231033678

Copyright Information

Copyright 2017 by the author(s). This work is made available under the terms of a Creative Commons Attribution-NonCommercial-NoDerivatives License, available at <https://creativecommons.org/licenses/by-nc-nd/4.0/>

Peer reviewed

Certolizumab-induced guttate psoriasiform dermatitis

Ryan Fischer MD, Matthew DaCunha BS, Anand Rajpara MD

Affiliations: Division of Dermatology, University of Kansas Medical Center, Kansas City, KS.

Corresponding Author: Ryan Fischer, 3901 Rainbow Blvd., Kansas City, KS 66160, Email: ryanfischeruk@gmail.com

Abstract

Certolizumab is a TNF inhibitor that has shown great efficacy in chronic inflammatory diseases. We report a patient exhibiting a novel adverse effect of certolizumab: drug-induced guttate psoriasiform eruption. A review of the mechanism of psoriasiform drug eruptions is also included.

Keywords: certolizumab, guttate psoriasis, drug reaction, psoriasiform dermatitis

Case Synopsis

A 38-year-old man with history of Crohn disease and plaque psoriasis on the knees and elbows presented with a rash over the scalp, arms, back, chest, and thighs of two weeks duration. The patient was receiving certolizumab pegol (Cimzia) as treatment for Crohn disease as prescribed by

his gastroenterologist. One week after starting certolizumab, the patient developed a pruritic rash, which started on his chest and scalp and later spread to the back and extremities. After referral from the patient's gastroenterologist, the patient presented with a rash covering the scalp, arms, back, chest, and thighs. He had no preceding pharyngeal infection or other skin infections to otherwise explain a guttate psoriasis eruption, and so the patient was not tested for streptococcal infection.

Physical examination showed a diffuse erythematous, mildly scaly, guttate, macular eruption over the scalp (**Figure 1A**), arms, back (**Figure 1B**), and chest.

A shave biopsy was performed from a lower back lesion. Biopsy demonstrated regular psoriasiform epidermal hyperplasia, loss of the granular layer, and parakeratosis with neutrophils. There was a sparse perivascular lymphoid infiltrate surrounding dilated

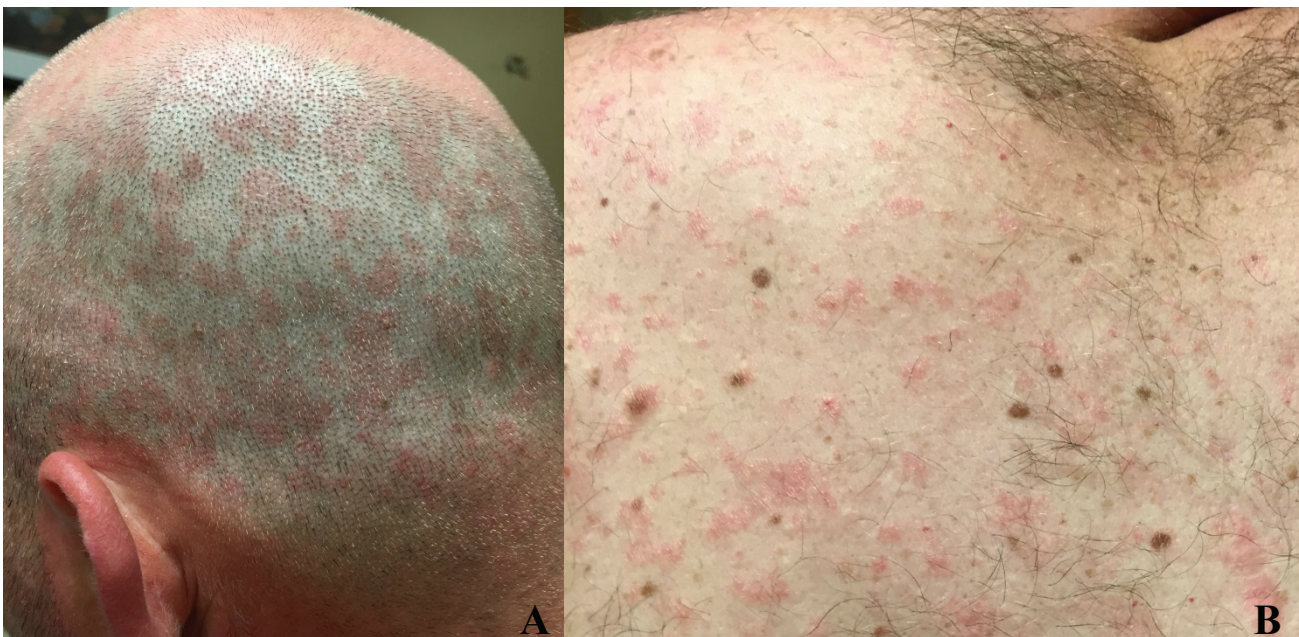

Figure 1. Guttate erythematous, scaly macules on the scalp (A) and upper back (B).

capillaries within the dermal papillae. Given the findings on pathology, guttate psoriasiform dermatitis was diagnosed (**Figure 2**).

Given the clear temporal association between medication initiation and the cutaneous eruption, the guttate psoriasiform eruption was attributed to the use of certolizumab. Other cases of drug-induced psoriasis have been documented related to the uses of adalimumab, etanercept, and infliximab as well. It is suggested that psoriasiform eruption is a drug class effect of TNF inhibitors [1].

Triamcinolone 0.1% ointment twice daily was prescribed for the cutaneous eruption. After addressing the issue of further use of certolizumab with the patient, the patient preferred to stop the medication because of the dermatologic symptoms. He was switched to infliximab and prednisone per the gastroenterology service, though it is also possible to develop a psoriasiform eruption related to infliximab [1, 2]. The topical triamcinolone was continued. The eruption, as well as the pruritus, gradually resolved over a period of two months after discontinuing the certolizumab.

Case Discussion

Certolizumab is a tumor necrosis factor (TNF) inhibitor and has been shown to have significant efficacy in chronic inflammatory diseases. Certolizumab is a pegylated humanized Fab fragment of an anti-TNF monoclonal antibody. Because of its nature as an Fab fragment, certolizumab lacks an Fc region. With the absence of an Fc region, certolizumab is able to bind and neutralize TNF without directly inducing complement activation, cellular toxicity, or apoptosis [3, 4]. Although there have been many studies on the various side effects of certolizumab, psoriasiform drug eruption (and in our case, guttate) related to certolizumab is a rare presentation [1]. Other reported adverse effects of certolizumab include drug-induced lupus-like syndrome (DILS), serious infections, and malignant neoplasms [5, 6, 7]. Despite its potential adverse effects, certolizumab is considered to be a well-tolerated alternative to both etanercept and infliximab due to its unique

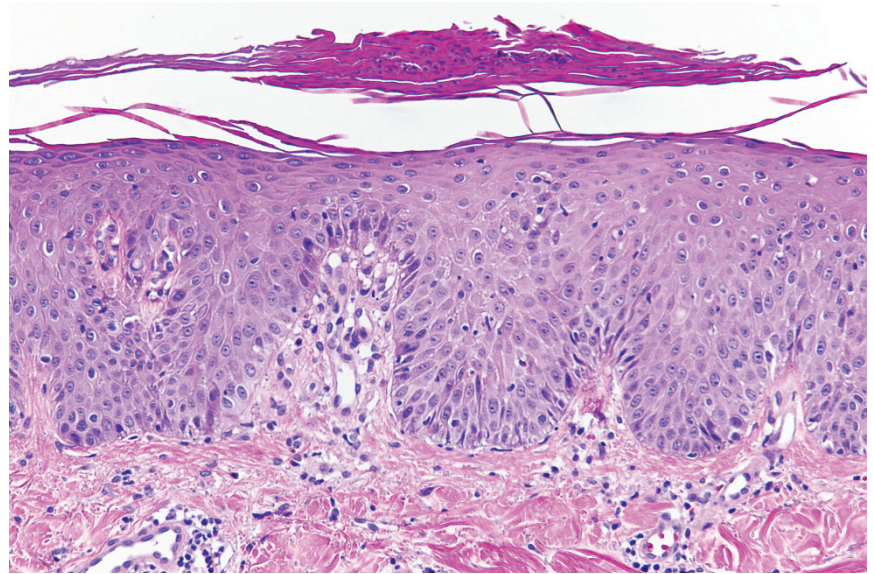


Figure 2. Shave biopsy demonstrated regular psoriasiform epidermal hyperplasia, loss of the granular layer and parakeratosis with neutrophils. There was a sparse perivascular lymphoid infiltrate surrounding dilated capillaries within the dermal papillae. (H&E, 100x).

structure [7, 8]. It has been shown in several studies that a small percentage of those on certolizumab may develop anti-certolizumab antibodies [5], which could result in lupus-like reactions [6, 7, 8]. Lupus-like reactions are related to a type III hypersensitivity reaction in which anti-certolizumab antibodies create complexes, deposit in capillary beds, and activate complement, leading to a skin eruption. However, this is not likely in our patient. In our case, it is more likely that the psoriasiform drug eruption was a result of a type IV hypersensitivity. This judgement is based upon similarities with other cases of drug-induced psoriasiform eruptions, including the length of time it took to first develop the rash (around one week after taking certolizumab). The time to resolution mostly depends on the half-life of the medication. Given the longer-lasting half-lives of the injectable TNF-alpha inhibitors (certolizumab has a half-life of 2 weeks), the drug-induced eruptions may take several months to clear completely, as was the case in our patient.

There are many proposed mechanisms proposed for drug-induced psoriasis and psoriasiform drug eruptions. One current hypothesis of psoriasiform drug eruption supports the notion of type IV hypersensitivity through the stimulation of T cells by plasmacytoid dendritic cells [6]. Plasmacytoid dendritic cells can be found in psoriatic lesions and naturally produce interferon alpha (IFN-alpha), which

may play a key role in the induction of psoriasis. TNF inhibits the maturation of plasmacytoid dendritic cells, but neutralization of TNF by anti-TNF drugs allows for increase in IFN-alpha production. IFN-alpha induces the expression of chemokine receptor CXCR3 on T cells that allows them to be directed to the skin. IFN-alpha can also stimulate maturation of myeloid dendritic cells for antigen presentation to T cells, resulting in an immune response and ultimately affecting the skin [9, 10].

Other theories suggest a relation to acquired infection during the anti-TNF regimen because of increased susceptibility to pathogens [5, 9, 10] or the induction of IFN-alpha playing a role in the stimulation of autoreactive T cells [9, 10]. Our patient had no evidence of infection at the time of presentation.

Several studies indicate that drug-induced psoriasiform eruptions may arise de novo, but that the incidence is greater in those who have a history of psoriasis. This theory fits our patient well given his history of plaque psoriasis

Conclusion

This case illustrates an adverse effect from a newer and increasingly used medication. It is important for dermatologists to recognize and treat these adverse effects, as it may result in the discontinuation of the medication. It is also important to communicate to the patient and interdisciplinary team members that the cutaneous signs and symptoms may take months to resolve after discontinuation.

References

1. Nguyen K, Vleugels RA, Velez NF, Merola JF, Qureshi, AA. Psoriasiform reactions to anti-tumor necrosis factor α therapy. *J Clin Rheumatology*. 2013 Oct;19(7):377-81. [PMID: 24048106]
2. Afzali A, Wheat CL, Hu JK, Olerud JE, Lee SD. The association of psoriasiform rash with anti-tumor necrosis factor (anti-TNF) therapy in inflammatory bowel disease: a single academic center case series. *J Crohns Colitis*. 2014 Jun;8(6):480-8. [PMID: 24268978]
3. Sandborn WJ, Feagan BG, Stoinov S, Honiball PJ, Rutgeerts P, Mason D, Bloomfield R, Schreiber S. Certolizumab pegol for the treatment of Crohn's disease. *N Engl J Med*. 2007;357:228-238. [PMID: 17634458]
4. Schreiber S, Khaliq-Kareemi M, Lawrance IC, Thomsen OØ, Hanauer SB, McColm J, Bloomfield R, Sandborn WJ. Maintenance therapy with certolizumab pegol for Crohn's disease. *N Engl J Med*. 2007; 357:239-250. [PMID: 17634459]
5. Pirowska MM, Goździalska A, Lipko-Godlewska S, Obtulowicz A, Sułowicz J, Podolec K, Wojas-Pelc A. Autoimmunogenicity during anti-TNF therapy in patients with psoriasis and psoriatic arthritis.

- Advances In Dermatology & Allergology/ Postepy Dermatologii I Alergologii.2015;32(4):250-254. [PMID:26366147]
6. Williams VL1, Cohen PR. TNF alpha antagonist-induced lupus-like syndrome: report and review of the literature with implications for treatment with alternative TNF alpha antagonists. *Int J Dermatol*. 2011 May; 50(5):619-25. [PMID: 21506984]
7. Sandborn WJ, Lee SD, Randall C, Gutierrez A, Schwartz DA, Ambarkhane S, Kayhan C, Pierre-Louis B, Schreiber S, Lichtenstein GR. Long-term safety and efficacy of certolizumab pegol in the treatment of Crohn's disease: 7-year results from the PRECiSE 3 study. 2014 Oct; 40(8):903-16. [PMID: 25146586]
8. Verma HD, Scherl EJ, Jacob VE, Bosworth BP. Anti-nuclear antibody positivity and the use of certolizumab in inflammatory bowel disease patients who have had arthralgias or lupus-like reactions from infliximab or adalimumab. *J Dig Dis*. 2011 Oct; 12(5):379-83. [PMID: 21955431]
9. Ivan G, and Gisbert J. Onset of psoriasis in patients with inflammatory bowel disease treated with anti-TNF agents. *Expert Review of Gastroenterology & Hepatology* 7.1. 2013; 41+. [PMID: 23265148]
10. Milavec-Puretić V, Mance M, Ceović R, Lipozenčić J. Drug induced psoriasis. *Acta Dermatovenerol Croat*. 2011; 19(1):39-42. [PMID: 21489366]